









# CONTRIBUTIONS TO EMBRYOLOGY

---

VOLUME XI, Nos. 49 to 55



PUBLISHED BY THE CARNEGIE INSTITUTION OF WASHINGTON  
WASHINGTON, 1920

CARNEGIE INSTITUTION OF WASHINGTON  
PUBLICATION No. 274

PRESS OF GIBSON BROTHERS, INC.  
WASHINGTON

## CONTENTS.

	PAGE
No. 49. Myeloid metaplasia of the embryonic mesenchyme in relation to cell potentialities and differential factors. By VERA DANCHAKOFF (5 plates).....	1-32
50. Studies on the longitudinal muscle of the human colon, with special reference to the development of the teniae. By PAUL E. LINEBACK (8 text-figures).....	33-44
51. Experimental studies on fetal absorption: I. The vitally stained fetus. II. The behavior of the fetal membranes and placenta of the cat toward colloidal dyes injected into the maternal blood stream. By GEORGE B. WISLOCKI (4 plates, 1 text-figure).....	45-60
52. A human embryo at the beginning of segmentation, with special reference to the vascular system. By N. WILLIAM INGALLS (5 plates, 1 text-figure).....	61-90
53. The effects of inanition in the pregnant albino rat with special reference to the changes in the relative weights of the various parts, systems, and organs of the offspring. By LEE WILLIS BARRY.....	91-136
54. A case of true lateral hermaphroditism in a pig with functional ovary. By GEORGE W. CORNER (1 plate).....	137-142
55. Weight, sitting height, head size, foot length, and menstrual age of the human embryo. By GEORGE L. STREETER (6 charts, 2 text-figures).....	143-170





---

CONTRIBUTIONS TO EMBRYOLOGY, No. 49.

---

MYELOID METAPLASIA OF THE EMBRYONIC MESENCHYME  
IN RELATION TO CELL POTENTIALITIES AND  
DIFFERENTIAL FACTORS.

---

BY VERA DANCHAKOFF.

---

With five plates.

---

## CONTENTS.

	PAGE
Introduction; Polyvalent structures; Factors of their further development.....	3
Mesenchyme of the spleen, of the allantois, and of the thymus.....	6
Mesenchyme of the muscles.....	9
Mesenchyme of the sex-glands.....	13
Mesenchyme of the kidneys.....	18
Mesenchyme in other regions of the embryo body.....	23
Conclusions.....	27
Bibliography.....	31
Explanations of plates.....	32

# MYELOID METAPLASIA OF THE EMBRYONIC MESENCHYME IN RELATION TO CELL POTENTIALITIES AND DIFFERENTIAL FACTORS.

BY VERA DANCHAKOFF.

## INTRODUCTION—POLYVALENT STRUCTURES—FACTORS OF THEIR FURTHER DEVELOPMENT.

The gradual development of diversity in ontogeny can be brought about in two different ways. It may result from merely a conversion of hidden diversities into visible ones and be determined by factors found in the physico-chemical constitution of the living matter itself. The environment in this case furnishes only the necessary conditions for the realization of the already existing diversity. According to Roux, a similar process can be called *self-differentiation* ("differentiatio sui," Roux; "differentiation spontanée," Brachet). Structures, anlagen, or cells developing in this manner are specific; that is to say, under any non-injurious conditions they will transform into definite products in a predetermined way. Such structures are univalent or unipotent and possess narrow and well-limited potencies which they fully realize in their development.

On the other hand, the diversity appearing during ontogeny may be determined by factors lying partly or fully outside of the developing structures. Such changes or differentiations are called by Roux *dependent differentiation* ("differentiatio relativa," Roux; "differentiation provoquée," Brachet). In this case the changes in the living matter may be considered as reactions, the results of which will depend upon external agents. They will be different in compliance with different environmental factors. The structures, primordia, or cells are in this case polyvalent, because they may develop along different lines. The living matter in this case may become a starting-point for various lines of development; the determining factors of the actual line of its development, however, lie outside of it, in the environment. In this case the actual line of development realized by the living matter is merely a part of its total potencies. It is to similar structures that the following words of Brachet can be so well applied: "Après que le naturaliste a constaté ce qu'un animal est et fait, il lui faut rechercher ce qu'il est en outre capable d'être et de faire."

Researches along these lines have taught us that not all of the typical development in the organism is a spontaneous differentiation, but that it may be determined by environment including the correlations of its organs. These correlations may inhibit some or even the greater part of the potencies of a structure or directly determine its actual line of development, which might be a fraction only of what it is

capable of doing. The typical development of living matter resulting from interaction of its physico-chemical constitution and normal conditions, on account of its regularity, often gives a strong impression of being merely a specific self-differentiation, and experimental or pathological conditions only may sometimes show that the regularity of typical development depends upon the regularity of the environment, and that the process may vary in compliance with changes in it. As a striking example of a typical process may be mentioned the development of the first blastomeres in definite classes of animals. In their typical development they regularly transform into definite parts of the organism, but the potencies realized by them in a typical development are not the only ones belonging to them. The first blastomeres in various classes of animals under experimental conditions may produce not only parts of embryos but whole embryos. The typical development of the first blastomeres in such eggs is limited in most cases, not by physico-chemical constitution of the blastomere, but by environmental factors. The total potencies of the blastomeres are greater than those which they manifest in their typical development.

In the later stages of segmentation the physico-chemical constitution of the ensuing cell-groups becomes more specific and their potencies narrower. But it has been already shown for some tissues that their potencies for further development remain greater than those which they actually manifest. The ectoderm on the surface of the whole body in amphibian larvæ is found to be polyvalent, since it may produce lenses at each point of its surface, if after the grafting of an optical cup it enters into direct local correlation with it. W. H. Lewis says: "Any portion of the inner layer of the ectoderm is capable of giving rise to a lens, when properly stimulated. There is then no especial predetermined group of cells which must be stimulated in order that a lens may arise."

The important work of analyzing in higher animals the factors which determine the ontogenetic processes has been inaugurated rather recently, and as yet little is known as to which of the various primordia develop into their final products exclusively on account of their physico-chemical constitution, and which of them, by nature polyvalent, are compelled to do so by external factors.

The experimental evidence found in the literature does not allow at present any generalization in this respect, and it is just as incorrect to ascribe a specificity to all the primordia of different organs as to declare them all totipotent, or at least polyvalent. The various cell-groups have to be analyzed separately and special care is required before proclaiming that an organ is definitely limited in its development; for, according to Fischel, "ein negatives Versuchsergebnis lässt sich nicht im Sinne eines Potenzmangels deuten."

In order to find out whether local environmental factors have any determining influence upon the development of definite primordia, they have frequently been transplanted into other parts of the organism. Braus (1903) successfully carried out similar experiments on amphibians and decided that the limb-bud of the anuran larva constitutes a self-differentiating system. Harrison (1918), on the basis

of similar experiments, came to the conclusion "that the essential process of differentiation, whereby the potency to form a forelimb becomes localized in certain cells of the body wall, must be relegated to very early embryonic life."

But there are a number of experiments the results of which indicate that other primordia in other animals may possess a polyvalency during the embryonic stages and even throughout life. Numerous cases in the vast domain of regeneration can be explained only on the basis of a polyvalency retained by certain structures. Various cases of heteromorphosis (including the transformation of the epithelium of the surface body into a lens) suggest strongly the existence of polyvalent structures. The regeneration in crustaceans of an eye or an antenna in the place of an extirpated eye (according to whether the optic ganglion was removed or left in place) is one example among many that could be cited (Herbst, 1895). Of course, in the cases of regeneration of various complex organs the advocates of tissue specificity, if microscopical study of the experimental material is omitted, can always advance the suggestion that there exists a specific primordium for every organ that might arise from a definite part of the organism.

My personal experience in the study of the primordia of hemopoietic organs, and of their activity in a normal adult organism as well as under pathological conditions, does not allow me to extend the conception of specificity or univalency to all the primordia or even to the tissues of the developing embryo. No doubt the different organs, under normal conditions, take a predetermined line of development. This is a definite and invariable result formulated by descriptive embryology. However, their actual development is the result of complex factors, which in part are represented by the constitution of the primordium itself, either polyvalent or univalent, and in part by factors lying outside of it. The mere observation that the primordia of the embryo under the same normal conditions develop into the same organs does not justify us in concluding that they are univalent and self-determining. Freed from a possibly inhibitory influence of their regular environment and submitted to other conditions, they might have manifested other potencies. If so, their normal development would have been determined, or at least limited, not by intrinsic factors consisting of a specific constitution of the primordia, but by factors external to them; the latter, therefore, would have determined which of their potencies were to be realized, and to what extent.

Most of the primordia of the organs in a developing embryo are localized and enter into definite correlations with other organs. Though limited to the mesenchyme, the hemopoietic differentiation is not confined to definite topographic boundaries. It is true that at an early stage of embryonic development blood primordia appear in the form of blood-islands in the area opaca and develop there from the mesodermal mesenchyme, but this is not the only place where hemopoietic tissue develops. Mesenchyme differentiates into blood-cells in the area opaca, between the growing buds of the liver-cells, in the spleen, in the bone-marrow, in many places along the intestinal tube, and (in a more diffuse manner) in the loose tissue between different organs. At a certain stage of embryonic development the diffuse hemopoiesis ceases and in a normal adult organism it is well localized.

While all the mesenchyme found between different organs of a normal embryo does not by any means differentiate into blood-cells, the mere fact that invariably, under normal conditions, only a part of it develops into blood-cells is certainly not a sufficient reason for assigning to that part certain specific properties not present in the mesenchyme of other regions. Other mesenchymal cells, except those which actually develop into blood-cells, may possess analogous potencies, but by special conditions might be prevented or inhibited from exhibiting them. The problem in this case is analogous to the problem of determining the potencies of the blastomeres. If all of the first 2, 4, or 8 blastomeres in definite animal classes can be brought to develop a full embryo, these blastomeres have to be considered potentially equivalent and their total potencies greater than those they actually display. In an analogous manner, if the loose mesenchyme between different organs or the mesenchymal constituents of various organs which do not ordinarily develop into blood-cells can be brought to do so, as is shown in this paper, the mesenchyme actually developing under normal conditions into blood-cells, and that part of it which undergoes similar changes under experimental conditions only, must both be considered potentially equivalent and the potencies of the latter greater than those it actually displays. Moreover, if mesenchymal cells, which under normal conditions invariably follow a definite line of differentiation, can be brought under changed conditions to develop a potency different from that manifested by them under normal conditions, these mesenchymal cells must be considered polyvalent, their actual development being determined by external conditions.

There is no doubt that the physico-chemical constitution of a definite living substance always plays an active part in its differentiation, and it is evident that from a bird's egg nothing but the diverse tissues of a bird will develop, and from a hemoblast nothing but one of the blood-cells will arise. Polyvalent structures encountered in the course of embryonic development are polyvalent in a limited sense only, and no longer totipotent; so a mesenchymal cell, at definite stages of embryonic development still polyvalent, may have among its offspring (according to environmental factors) a connective-tissue cell, a granuloblast, an erythroblast, or a small lymphocyte, but certainly not a nerve-cell or a mucus gland. Nevertheless, the demonstration of polyvalent structures, even in a restricted sense, necessarily implies the conclusion that environmental conditions may become factors capable of determining the actual line of the differentiation of a polyvalent structure, or, in other words, creating diversity in the living matter.

#### MESENCHYME OF THE SPLEEN, OF THE ALLANTOIS, AND OF THE THYMUS.

Descriptive investigations in embryology and pathology have furnished numerous data concerning a possible polyvalency of the loose mesenchyme and of the stroma of various organs in embryonic and adult life. The diffuse character of the embryonic hemopoiesis is certainly suggestive, not of the dissemination of specific hemopoietic primordia, but of a ubiquitous distribution of a single autochthonous process of differentiation. Moreover, observations relating to changes of

mesenchymal constituents in adult organs, under pathological conditions, into various kinds of blood-forming tissue have raised the question as to whether these results were due to a diverse activity of mesenchymal cells, polyvalent even in the adult, or to the proliferation of specific cell-groups present in the organs or brought in as cellular emboli.

On the basis of the descriptive investigations, the potentialities of the loose mesenchyme can not be definitely established. Its partial development into blood-cells, together with the lack of a strongly defined localization of the hemopoiesis in the ontogenetic development, as well as in its phylogenetic evolution, have served alternatively as arguments for its polyvalency or for its specificity. The invariable differentiation of a part only of the mesenchyme into blood-cells can indeed be interpreted either as a result of the specification of definite mesenchymal cell-groups or as a manifestation of a general potency, dependent upon factors under whose control a part only of the mesenchyme is placed. Only by experimentally extending the blood-forming activity to parts of the mesenchyme, which, under normal conditions, never manifest similar potencies, can we prove that they possess them. Only by experimentally calling forth in mesenchymal cells a potency different from that revealed by them under normal conditions can we prove that they are polyvalent. Departure from the typical development manifested under experimental conditions by either mesenchyme or first blastomeres can be compared to the differences observed in the fall of a feather *in vacuo* and in air.

In the two parts of the "Equivalence of Hematopoietic Anlages" (1916*e*, 1918*b*) it was my purpose to analyze the changes called forth by grafting of adult splenic tissue on the chick allantois in the spleen of the host, a merely specialized condensation of the mesenchyme, and to compare them with those which necessarily must have taken place in the loose mesenchyme of the allantois itself, if the mesenchyme in the allantois were equivalent to that of the spleen. In order to establish whether or not the mesenchymal part of the spleen has changed its potentialities with age, an analysis was also made of the fate of the adult splenic tissue grafted on the chick allantois. In a previous paper (1916*d*) changes in the structural characters of the thymus consequent upon the same experimental intervention were recorded. The results of this study clearly indicate that mesenchymal cell-groups in such different embryonic regions as thymus, spleen, and allantois can be simultaneously brought to a proliferation, of which the intensity strikingly surpasses the proliferative capacity of the usual embryonic mesenchymal tissue. This simultaneous proliferation was incited by the same factors brought about by the grafting and growth of adult splenic tissue on the allantois of the embryo. Moreover, the proliferation of the mesenchyme in all these regions was followed by an analogous differentiation. Mesenchymal cells lost their syncytial arrangement and appeared in groups of amœboid cells, which in the literature were given various names—stem-cells, hemoblasts, hemogonia, mesamœboid cells, etc. These cells continued to proliferate and, according to their topographic localization, finally were transformed into granuloblasts or, if situated in the venous sinuses of the developing spleen, into erythroblasts.

The mesenchyme of the thymus, of the spleen, and of the allantois was shown to possess similar potentialities which, in a typical development, were either realized in a slighter degree or not revealed at all. Large areas of mesenchyme were in all these organs transformed into granuloblastic tissue. Microscopical characteristics of the organs (for example, the size of the spleen and thymus) also were much modified, the organs under experimental conditions increasing in size to many times the normal average. Finally, the analysis of the fate of the grafted adult spleen brought quite definite evidence for the retention by the adult splenic mesenchyme of its original potencies—the cellular reticulum of both follicles and red pulp underwent granuloblastic transformation. Not only, therefore, could the size, and especially the structural character, of such organs as thymus and spleen be changed during their development in the embryo, but the structure of a normal adult spleen, of which the hereditary characters seemed to have been fully realized, could be radically changed by transplanting parts of this organ into the allantois.

The microscopical study of these transformations has shown that these changes depended upon a modified activity of polyvalent mesenchymal cells, which responded in definite but different ways to normal and pathological stimuli. The latter, introducing into the environmental conditions factors which were not present in normal typical development, must have brought changes in the metabolism of the mesenchyme which now liberated numerous free cells, hemoblasts. These factors called forth an intense differentiation of hemoblasts into granular leucocytes in regions in which it normally occurred only in a moderate degree, and also incited it anew in areas in which normally no similar differentiation was found. In the light of these results the embryonal mesenchyme of the spleen, of the thymus, and of the allantois of the chick has to be regarded as possessing equal power for granuloblastic differentiation.

During the early stages of splenic development the stem-cells showed themselves capable of various differentiation, while their fate was determined by whether they were incorporated into a developing venous sinus or were left outside. The stem cells in the thymus, which under normal conditions develop into small lymphocytes, were seen to follow a granuloblastic line of differentiation. Moreover, the mesenchyme of the adult spleen in the form of the cellular reticulum—a source for the small lymphocytes in later embryonic and adult stages—was shown to retain its potencies for granuloblastic differentiation, thus clearly demonstrating the polyvalency of the mesenchyme in these regions.

Definite as these findings may appear as experimental proofs for the polyvalency of the loose mesenchyme, they still leave a large, unsettled field in relation to numerous other regions in which the mesenchyme is found in the organism. Are not the above cited regions of mesenchyme centers of predilection in which granulopoiesis may be developed in embryonic stages and rekindled, even in adult? The splenic mesenchyme develops normally a granulopoietic activity, which in intensity may vary considerably in different specimens. Granulopoiesis in the thymus exists normally in reptiles and is occasionally observed in other animals. No granul-



poiesis has so far been described in the normal allantois, but the changes displayed under experimental conditions by this membrane, with its special vascularization, can not serve as a basis for deductions applying to other parts of the host's mesenchyme. One can not therefore be fully convinced, on the ground of the results already described, that all of the loose mesenchyme found in the embryo at about the seventh to the eighth day of incubation is polyvalent as well as equipotential, at least in regard to blood-forming power. A manifestation of various hemopoietic activity by all the mesenchyme of the whole embryonic body can be advanced as only valid proof of the equivalency of the mesenchyme in general, of the existence of latent potencies in the mesenchyme and of its polyvalency.

At the meeting of the Anatomical Society in New Haven in 1915 (1916*b*) I had an opportunity of demonstrating granulopoietic activity in the mesenchyme between the muscles and groups of muscular fibers in different regions of the embryo after grafts of adult splenic tissue on its allantois. In a later paper (1916*c*) I stated that "no place exists in the embryo body where (under experimental conditions) the mesenchyme does not show this process. Thus, the embryonic mesenchyme appears to be a diffuse anlage for both lymphopoiesis and granuloleukopoiesis." Since then additional data relating to the sex-glands, the kidneys, and other organs have accumulated, and finally it became obvious indeed that there remained no place in the body of a chick embryo of 7 days' incubation in which the loose mesenchyme could not be incited to granuloblastic differentiation. These additional data, together with those occasionally mentioned or demonstrated, will now be presented under separate paragraphs.

#### MESENCHYME OF THE MUSCLES.

The scanty mesenchyme within a muscle under normal conditions is invariably transformed into connective-tissue cells only. It could not be otherwise. The development of fibroblasts is here the result of interaction of the definite physico-chemical constitution of the mesenchymal cell plus definite normal environmental conditions. However, the mere observation that the mesenchymal cells in the muscles under the same normal conditions invariably develop into fibroblasts does not allow us as yet to conclude that these cellular elements are specific or univalent; *i. e.*, that they would, under any non-injurious conditions, develop into fibroblasts only. It is true that investigations on muscle regeneration did not reveal new potencies in the mesenchymal constituents of the muscles, but a negative result obtained under definite experimental conditions can not be immediately interpreted as proof of an absolute lack of a potency in these cells or in their ancestors. The study of the mesenchyme of developing muscles after grafts of adult splenic tissue on the allantois of the embryo brings a new evidence for the existence of latent blood-forming potencies within a part of the embryonic mesenchyme previously unsuspected of possessing such a potency. The loose mesenchyme between groups of muscle fibers and the mesenchyme around the different muscles in the neck region, in the wings and legs, as well as the connective-tissue cells around the tendons, show after this intervention an extensive granulopoietic transformation.

No detailed analysis is found in the literature relating to differentiation of the mesenchymal cells in the muscles into their sheaths at various embryonic periods. Only a comparison of the typical development of the mesenchyme in different organs with that taking place in specimens under experiment would enable us to realize fully the extent and importance of the changes taking place under experimental conditions. To follow, however, step by step, the differences between the normal development of the mesenchyme and its response under experimental conditions in the different organs would mean too great an extension of the present paper. However interesting might be the results of such systematic comparative study, it would require much time, and the presentation of the general results obtained, controlled and verified during the last three years, would necessarily have been further delayed. Moreover, the progress of changes in the mesenchymal constituents in muscles and other organs in specimens under experiment is so pronounced, and the final results of these changes so striking, that it seemed to me permissible and desirable to give here a synopsis of these changes, and at the same time to analyze as far as possible their significance. I will therefore confine myself to a description of the gradual changes which take place in the mesenchyme of the embryos under experiment and which finally lead to such fundamental transformations that in some cases the characteristic structure of definite organs can be hardly recognized.

An indication of an abnormally intense activity in the mesenchyme may be observed as early as the second day after a successful grafting. Figure 1 represents a small muscular area of the wing at this stage. The grafting having been made at the end of the seventh day of incubation, the embryo is now about 9 days old. The cross-striation of the muscular fibers is distinct. Unlike conditions found in normal embryos, groups of muscle-fibers and individual fibers in the various parts of the embryo body are in many places separated by quite large interstices. They give an impression of being œdematous. In the interstices between the muscular fibers mesenchymal tissue is found which shows an intense proliferation; numerous mitoses are present. In regions immediately adjacent to the muscular fibers the mesenchyme appears in the form of a more or less loose syncytium, the cells of which have an elongated shape and are closely apposed to the fibers. A sheath of mesenchymal cellular network is thereby furnished to the muscular fibers, which contain rather numerous nuclei. There is no difficulty in distinguishing the nuclei of the mesenchymal cells from those of the muscular fibers. Their flattened shape and superficial position, together with their characteristic structure, make the identification of the nuclei of the mesenchymal cells quite easy.

A different appearance is offered by the mesenchyme situated in the enlarged interstices between the muscle-fibers. There neither cytoplasm nor nuclei are flattened or distended; on the contrary, the mesenchymal cells appear in the form of huge bodies, from which numerous cytoplasmic processes emerge. A syncytium with rather short meshes is thereby formed. Similar areas in the muscles closely resemble the figures in Godlevsky's paper (1902) given as an illustration of the results brought about by physiological degeneration in muscles. If the loose tissue

in the interstices between the groups of muscle-cells should prove to be identical in both cases, it would seem that muscular cells at an early stage of their development can, by a reversible process, reassume the structure and potencies of the mesenchyme. The cells of this mesenchyme are found soon to increase their cytoplasm, which at the same time begins to appear more basophilic. The mesenchymal syncytium occupying the interstices and that closely adjacent to the muscle-fibers are not two separate structures and are seen to be directly connected by cytoplasmic processes. The intense proliferation observed in the mesenchyme leads soon to the formation here of a dense cellular tissue. The cells are gradually drawn together by the increase in their number as well as in size. In some places the increasing condensation of the mesenchyme transforms it finally into plasmodial masses, in which individual cellular units are no longer distinguishable. Moreover, a marked hypertrophy of numerous cells imposes at this time a polymorphic character upon the formerly uniform syncytium. The aspect of a muscle of an embryo under experiment at this stage differs already to a great extent from the structure of a normal muscle of a control embryo.

This mesenchyme soon acquires an even more peculiar aspect, while numerous cells of the syncytium withdraw their processes from the common network, become free, and appear under the form of amœboid cells. This process, though more pronounced in the mesenchyme situated in the spaces between the muscle-fibers, affects equally those mesenchymal cells which are closely adjacent to the muscular fibers. It is difficult to determine whether or not single cells between parts of muscles in a normal embryo may not be detached from the syncytium and remain here as dormant wandering cells. The process of separation of amœboid cells from the mesenchymal syncytium in different parts of the loose mesenchyme and in different blood-forming organs is now widely accepted. The rather unique localization of this process in the muscles, even between its individual fibers, and its great intensity revealed here, distinguish this process from that observed elsewhere under normal conditions. The cells detached from the mesenchymal syncytium in their subsequent development clearly show that in the stage of free cells they are capable of a more vigorous assimilation and of a higher synthetic power and that, at the same time, they more readily respond to external influences by fundamental structural changes. The separated mesenchymal cells hypertrophy and proliferate intensely.

Figure 2 gives an idea of the intensity which the process of proliferation and isolation of mesenchymal cells may attain in the muscles of some regions. This figure represents a small part of a cleft between the muscle-bundles in a tangential aspect. The group of muscular fibers are surrounded here by a dense accumulation of amœboid cells, considerable numbers of which seem to fuse into plasmodial masses. Many among these cells have already acquired the structural characteristics of hemoblasts; other amœboid cells resemble more the wandering cells of the connective tissue, which some years ago (1909) I described in the loose mesenchyme of the bird and reptile, under the name of histiotopic wandering cells. In these accumulations of free cells found between the muscle-fibers, the distinctive char-

acters of both groups of cells intermingle so gradually as to make this distinction in numerous cases no longer warranted. A constant relation between the characters of the amœboid cells (histiotopic or hemoblastic) and their topographic situation can be usually discerned. In the proximity of vessels the amœboid cell acquires preferably the structure of the hemoblast; in a region scantily supplied with vessels isolated mesenchymal cells appear in the form of histiotopic wandering cells. In regard to their developmental potencies these cells must be considered equipotential; first, because they so easily interchange; second, because they both manifest identical structural changes, as will be seen later.

Figure 8 illustrates the changes in the mesenchyme of the muscles in the chick leg under low-power. The heavy strands which occupy the interstices between the groups of muscular fibers can be identified under high power as accumulations of hemoblasts. In some parts of the photograph the cells are so closely drawn together that they give the impression of forming uninterrupted sheets, and only with the aid of high power can the reciprocal boundaries and the highly amœboid character of the respective cells be recognized.

Mesenchymal septa between large parts of individual muscles are equally affected, and at later stages appear densely infiltrated by mesamœboid cells. Even a more intense proliferation and separation into free cells is manifested by the mesenchymal tissue around the vessels traversing the muscle. Here whole sheaths of considerable thickness develop around the vessels and follow their ramifications. The study of the early stages of the myeloid metaplasia of the mesenchyme is particularly instructive as undoubtedly illustrating the local origin of the hemoblasts. At the time when an intensive development of hemoblasts takes place around the vessels, the blood within the vascular walls consists chiefly of erythrocytes in a more or less advanced stage of development and carries only single specimens of undifferentiated stem-cells or hemoblasts. The study of such stages leaves no doubt as to the local origin of the large accumulations of amœboid cells within the muscles.

Changes similar to those described above extend rapidly to the mesenchyme of the whole body, and as early as 4 or 5 days after a successful grafting the muscles present a peculiar aspect. A closer comparative study of different muscle-groups reveals that not all of them are affected to the same degree. Muscles can be found in which healthy muscular fibers become scarce and seem lost in huge accumulations of hemopoietic tissue. Sometimes direct atrophy and destruction of muscular tissue is brought about by development of large, rather well-circumscribed centers of hemopoietic tissue. Again, in other regions muscles do not differ much from their usual appearance. A direct ingrowth of cells from the mesenchyme surrounding the more superficial group of muscles can, in some cases (for example in the muscles of the neck), sufficiently explain the striking changes in them (figs. 3 and 9); a closer observation, however, does not reveal a regular relation between localization of the muscles and intensity of changes in them. The differences in the amount of connective tissue and the number of septa and septula normally present in the

muscles must certainly be of importance in bringing about the various degrees of infiltration of the muscles by hemopoietic tissue, since they all become starting points of intensive proliferation.

The future fate of the individual hemoblasts now situated within the muscle can be easily predicted. Their localization outside the vessels excludes for them the possibility of an erythropoietic differentiation. If in near proximity of vessels, hemoblasts usually transform readily into granuloblasts. There is, indeed, an intensive granuloblastic transformation of hemoblasts around the vessels traversing the muscles. Heavy sheaths of granuloblastic tissue are gradually developing around them. Granuloblasts (myelocytes), together with transitional stages of their gradual transformation into granular leucocytes, are also found in great numbers between the muscles and muscle fibers. Where, however, the connective tissue is dense and poorly vascularized, the isolated amœboid cells but seldom manifest a tendency to elaborate acidophilic granules in their cytoplasm; and, if so, they usually do not transform into granular leucocytes with rod-shaped granulation, but retain their spherical or oval nuclei and develop minute acidophilic granules.

Figure 3 is a drawing of a small part of a muscle in the neck of an embryo fixed 5 days after a successful graft of adult splenic tissue on its allantois. Figure 9 represents a similar region in the photograph. In spite of the advanced stage of granuloblastic transformation which a great number of hemoblasts have already reached, the process of gradual development of a mesenchymal cell into its final product, the granular leucocyte, can still be easily followed. This process affects the hemoblasts in all the regions in which the structure of the tissue is not too dense and which are supplied by a rich vascular net. Otherwise, the isolated amœboid cells appear in the form of histiotopic cells and retain this structure; quite remarkable may appear their amœboid activity, illustrated in figure 2. The larger accumulations of hemoblasts found in the muscles also undergo a granuloblastic differentiation. Granular leucocytes form in later stages the chief and sometimes the exclusive constituents of these cell clusters. The granular leucocytes, not finding an outlet into the circulation, undergo disintegration, and like in the spleen small necrotic foci then ensue in the midst of the muscular tissue.

One more region in the organism is found to contain mesenchyme which, at least in an embryo of the seventh to eighth day of incubation, is equivalent to the mesenchyme of hemopoietic centers and possesses a latent potency not revealed under normal conditions. The mesenchyme here, as elsewhere, may be conceived as disseminated hemopoietic buds, which, when awakened by a proper stimulus, display a great proliferative and differentiating ability. How long these dormant buds retain in the muscles their original metabolism and therefore their potentialities, and whether the latter may not be gradually lost as a result of a lasting symbiosis of the mesenchyme with the muscular tissue, can not be decided at present.

#### MESENCHYME OF THE SEX-GLANDS.

The stroma of the sex-glands in different classes of animals has been made the subject of special study by numerous investigators. In addition to the common con-

nective-tissue cells elements bearing a peculiar and definite structure "interstitial cells" were observed. Their morphological features were worked out in detail, especially in the testes of mammals, including man. Peculiar inclusions in the form of Reinke's crystals and riziform bodies, a characteristic structure of their idiosomes, as well as the presence of numerous fat droplets, were demonstrated. An attempt was also made to find homologous cells in the ovary.

The data concerning the presence of similar cells lose much of their precision in the observations made on the stroma of the sex-glands in lower animals. While in mammals, including man, the interstitial cells were traced through early embryonic periods, their presence in birds, particularly in the chick, was questioned by some investigators, not only in the embryo but also in the adult, and again asserted by others. The more general criterion upon which interstitial cells were identified in the chick consisted in most cases in the presence of numerous small fat droplets in their cytoplasm.

A parallel between the development of interstitial elements and of secondary sex characters was reported, and an important function was attributed to them, their secretion being assumed to be the factor determining the development of secondary sex characters. In view of the importance of such an assumption, no effort should be spared in securing additional data concerning these elements and in pointing out occasional and sometimes unavoidable errors.

The data concerning the presence of interstitial cells in the sex-glands of the chick are still very contradictory. They were not found by Boring in the testes of cocks from 1 to 12 months old (1912), in contradiction to de Cilleuls (1912), who found them at this stage and also seemed to have established a direct relation between the development of these cells and the sex characters of this animal. Recently (1915) Reeves confirmed the presence of interstitial cells in the testes of cocks 3, 5½, and 18 months old.

In an effort to settle this question finally, Boring and Pearl once more took it up and reported in their last paper (1917) that both in ovaries and testes interstitial cells can be found; in the ovaries, as a regular constituent of the stroma; in the testes, however, only occasionally in the newly hatched males. This observation was made on material fixed in Gilson with Mann's and Mallory's stains. It was considered by the authors that the acidophilic granules demonstrated by this method in some of the stroma cells of the sex-glands furnish a better criterion for the secreting function of these cells, consequently of their "interstitial" nature, than the presence of fat droplets. The illustrations which accompany this paper show free cells with acidophilic round granules in their cytoplasm irregularly disseminated in the stroma of the sex-glands. The presence of these cells recognized by the authors as "interstitial" was found to be not regular enough to warrant the assumption of such an important functional activity as the one ascribed to the interstitial cells of mammals.

Cells very similar to those described by Boring and Pearl were, however, found by Dauchakoff (1908) developing in the loose connective tissue of the chick embryo. The presence of similar cells in the connective tissue in the adult chick

was also reported by Solucha (1908). May the granular cells described by Boring and Pearl as "interstitial cells" prove to be the normal constituents of the connective tissue in the bird? Embryos with ubiquitous granuloblastic transformation of the mesenchyme after splenic grafts seem to be particularly favorable for answering this question. It has already been reported that after successful grafts of adult splenic tissue on the allantois of a chick embryo 7 to 8 days old the mesenchyme of the host is subject to a remarkable proliferation with subsequent isolation and a rapid hypertrophy of its cells, which further undergo a granuloblastic transformation. In spleen, thymus, allantois, and muscles great numbers of lymphoid hemoblasts, granuloblasts, and granulocytes are formed. The granuloblastic line of differentiation is imposed upon organs which, under normal conditions, manifest a hemopoietic activity of a different kind; so, for example, the thymus, which normally is the center of production of small lymphocytes, now becomes a focus of intensive granuloblastic activity. If the interstitial cells of Boring and Pearl are merely the normal constituents of the connective tissue of the chick, closely related to the family of blood-cells, we certainly would expect to find after grafts an enormous increase of granuloblastic activity in the stroma of the sex-glands similar to that found in other regions of the organism. It would, then, be an easy task to compare this undoubtedly hemopoietic tissue with the cells described by Boring and Pearl as interstitial. This task was greatly facilitated by the courtesy of Dr. Alice Boring, who kindly made, at my request, a demonstration of her preparations and took an active part in comparing the granular cells present in normal ovaries and testes with the granuloblastic tissue developing in huge masses after splenic grafts.

Figures 4, 5, 12, and 13 illustrate the striking changes in the stroma of the ovary and testes after splenic grafts. If compared with the stroma of the sex-glands in a normal chick embryo, in which only scattered amœboid cells with acidophilic granules can be found at this stage, the stroma in the sex-glands under investigation appears to be remarkably dense and heavily infiltrated with amœboid granular cells. Thick walls of granuloblastic tissue surround the intima of vessels of any considerable caliber. If it were not for the well-developed outer layer of the germinal epithelium the structure of the ovary would hardly be recognizable, and I was obliged to consult several well-known zoologists in order to definitely determine the nature of the organ in question.

Figure 5 represents a small part of the ovarian tissue adjacent to the germinal epithelium. It is well vascularized, numerous capillaries being discernible; scanty mesenchymal branched cells seem to hold them together. Two kinds of free cells, different in structure and origin, are found in its meshes. A part of them are unmistakably germ-cells; of large size and sometimes containing two vesicular nuclei, their cytoplasm shows a peculiar opaque appearance, and with eosin and azur II it acquires a purplish tint. But for the presence of distinct yolk-granules, they may readily be identified with those "endodermic wandering cells" which in 1908 I described in chick embryos of 3 to 12 segments as situated in the anterior part of the blastoderm between the ectoderm and the endoderm. At that time I stated only that, though I found them occasionally within the vessels, they had

nothing to do with blood-forming activity. It was the merit of Swift (1914, 1915) to have recognized in these cells the germ-cells. It is difficult to say whether the germ-cells found in the ovary at a stage of 16 days of incubation (fig. 5) are still on their way toward the already organized layer of germinal epithelium, or whether they have already been cut off from it by the mesenchyme. I leave this question undecided as not directly related with the present problem. The germ-cells found at this stage in the stroma of the ovary are rather scarce and isolated, but are accumulated in great numbers in the layer of the germinal epithelium.

As above stated, these cells are not the only ones found free in the meshes of the extremely loose mesenchyme in the developing ovary. Huge accumulations of amœboïd cells densely infiltrate the mesenchyme. Only a few of them do not contain acidophilic granules, most of them being heavily loaded with round and rod-shaped granulations. The amœboïd cells, free from granules, are typical lymphoid hemoblasts (hemogonia, stem-cells, mesamœboïd cells). Innumerable transitional stages clearly illustrate their gradual transformation into typical granular leucocytes with rod-shaped granulation. As is usual in centers with a sudden intensive manifestation of granuloblastic activity, the process of differentiation loses its normal regularity and cells may be found in which the granulation acquires the shape of rods at an early stage of its development; or, on the contrary, cells with polymorphous nuclei still retain a round-shaped granulation. Also, numerous small cells with round or oval nuclei and with numerous tiny acidophilic granules in their cytoplasm may be observed among the granular cells. These seem to be cells just detached from the mesenchyme, elaborating the granulation without having passed through the stage of the large basophilic hemoblast. The more diffuse accumulations of granular cells in the stroma of the ovary, as well as those accumulated in the form of heavy coats around the arteries and veins, belong undoubtedly to the series of the hemopoietic granuloblastic differentiation. The granuloblastic metaplasia of the stroma in the ovary forms merely a part of the general process involving the whole mesenchyme of the embryonic organism, at least at this stage (7 to 8 days).

Figures 12 and 13 of plate 4 illustrate, under low and high power respectively, the granuloblastic metaplasia of the ovarian mesenchyme. They remove all possible doubt as to the authenticity and extent of the process.

Are these huge accumulations of granuloblastic tissue found in the ovaries of the host after grafts of adult spleen on its allantois in any way comparable to those cells with acidophilic granulation found by Boring and Pearl in the ovary of the normal hen? A close comparison of a series of preparations shown to me by Dr. Boring with my own convinced us both of their similarity. I deeply appreciate the courtesy shown by Dr. Boring in demonstrating her preparations for the purpose of elucidating an unsettled question. The enormously increased granuloblastic activity in the ovarian tissue of embryos under experiment facilitated the interpretation of the isolated mature cells encountered in the normal ovaries. That Boring and Pearl did not always find these cells in the stroma of the sex-glands and that when present their number varied might well be accounted for by their



nature as wandering cells; a great variability is commonly observed in the number of wandering cells in any part of the organism.

Even more striking are the changes occurring in the stroma of the testes; here a few granular cells were found by Boring and Pearl only in newly hatched chicks. A glance at figure 4 will show a great number of acidophilic granular cells developed in the stroma of the testis of a chick embryo of 13 days. The changes in the stroma developed in 5 days after grafting. At this stage the stroma of the normal testis does not contain any granular cells; now and then a free wandering cell may be encountered, but seldom, if ever, do these differentiate further under normal conditions. The changes illustrated in figure 4 are therefore striking. At this stage the organ is traversed by the testis cords, which consist for the most part of a double row of cells, but which have not yet acquired a lumen. Large germ-cells, very much like those seen in the ovary, are situated in the cords, but only a few of them occupy a central position.

If it were not for the presence of numerous free cells the stroma would be rather poor in cellular elements, being, as a matter of course, composed of ordinary loose mesenchyme. The numerous amœboid cells make it, however, appear dense and heavy. It is not my purpose to describe again the histogenesis of these cells. As elsewhere, their source is the loose mesenchyme.

There is a marked difference between the character of the granular cells in the testes and those of the ovary, as shown in figures 4 and 5. The latter organ contains numerous granular leucocytes, together with their earlier developmental stages; in the testes most of the granular cells belong to the stage of granuloblasts. Their light nucleus is spherical, sometimes horseshoe-shaped, and contains one or two basophilic nucleoli. In almost all the cells the acidophilic granules in the cytoplasm are round; only single cells can be found which approach the final stage of differentiation into a granular leucocyte with rod-shaped granules. This difference depends upon the fact that the two specimens were fixed at different stages—the ovary 8 days and the testes 5 days after the grafts were made. The granuloblasts, already very numerous in the testes, had not yet had sufficient time to develop into their final product, the granular leucocytes.

The data given by Boring and Pearl concerning the regular presence of granular cells in ovaries of the hatched chick may be looked upon as an indication of the possible retention by the ovarian mesenchyme of its granuloblastic potency. The mutual correlation of ovarian mesenchyme and germ tissue may leave the granuloblastic potency of the mesenchyme of the ovary unaffected and in the presence of proper stimuli its mesenchyme may respond by further more or less extensive differentiation. Contrary to what is seen in the ovary, the authors did not find acidophilic granular cells in the testes; the mesenchyme here is scarce in the grown animal, but the absence of acidophilic granular cells certainly can not be interpreted as an indication of a permanent loss by the testicular mesenchyme of its granuloblastic potency. This may be the case, but it may also be that a proper stimulation, capable of revealing in the mesenchyme its granuloblastic potency, is lacking here. In embryos of 8 days of incubation, however, the mesenchyme of both the testes

and the ovaries is certainly equivalent to that of other regions of the body already examined, at least in respect to its granuloblastic potency.

### MESENCHYME OF THE KIDNEYS.

The potentialities of the mesenchyme of two organs—the mesonephros and metanephros—have to be considered under this heading. Both organs are present at 13 to 15 days of incubation (5 to 7 days after grafting), at which time the changes in the mesenchyme of the embryos under experiment were well advanced and the embryos studied. Its well-established origin and history render the study of the mesenchyme in both organs particularly interesting.

At an early embryonic stage the primordium of the epithelial and mesenchymal constituents of the kidneys are represented partly by the segment stalks and partly by that portion of the mesoderm which corresponds to them and which, in the chick, is transformed caudally from the twentieth or the twenty-first segment into the nephrogenic cord. Its anterior portion, the mesonephrogenic cord, participates in the formation of the mesonephros, and its shorter caudal portion separates and forms the primordium of the metanephros. The connective tissue of the mesonephros is derived from the dorsal parts of the segment stalks or of the nephrogenic cord, the cells of which lose their epithelial structure and form a loose mesenchymal tissue. It is also the dorsal part of the metanephrogenic cord, known as the external zone of the cord, which gives rise to the connective tissue of the metanephros (Felix, 1906). The mesenchyme of both organs, therefore, originates from that part of the mesoderm which is intimately connected with the somatopleura.

The mesenchyme of the kidneys, abundant in the early stages of embryonic development, becomes markedly scarce with the differentiation of new secreting units of the kidneys and with their further convolution. In the fully developed mesonephros, as well as in the adult metanephros, the mesenchyme is scarce and usually described as consisting of isolated fibroblasts and fibrils which invest the blood-vessels and the renal tubules. Under pathological conditions the stroma of the adult kidney can be seen to become much more abundant, but neither in adult nor in embryonic life was the stroma of the kidneys seen to assume a hemopoietic activity. Development of bone and bone-marrow was described in the kidney of the adult rabbit by Sacerdotti and Frattin (1902), and by Poscharissky (1905), the differentiation of the bone being attributed to the activity of the connective tissue. The development of the blood-cells has been, however, interpreted as a further differentiation of the lymphocytes, brought into the organ by the blood-stream (Maximov, 1907). In lower animals only does the mesenchyme of the mesonephros seem to be regularly connected with hemopoietic function. The stroma of the mesonephros in fishes becomes the seat of a permanent blood-forming activity, but neither in birds nor in mammals, as already stated, does the mesenchyme of the kidneys normally exhibit any of the hemopoietic potencies. The inference, therefore, that the hemopoietic potency exercised by the mesenchyme of the kidneys at a definite period of its evolution is gradually lost in higher vertebrates would seem to be well

supported by facts. Nevertheless, such a conclusion can be justly applied only to the results of typical development; as shown by the present observation, it is only in a typical development that the mesenchyme of the kidneys in higher vertebrates fails to manifest hemopoietic potencies. On the basis of the typical development of the mesenchyme no decision can be made whether it has undergone a definitive specification or whether on account of unfavorable environmental conditions, it is not revealing its hemopoietic potencies, though it possesses them in a latent state.

The study of the mesenchyme in the mesonephros and metanephros in chick embryos with a generalized granuloblastic differentiation of the mesenchyme clearly shows that in both organs it may enormously proliferate and undergo a further differentiation into granuloblastic tissue (at least at the stage of 7 to 9 days). The proliferative processes observed in the mesenchyme of the mesonephros and metanephros respectively, though essentially similar, bear well-pronounced individual characters depending upon the different environment in which they develop and demand a separate description in each case. Both organs are offspring from the same source. The lines of their development or differentiation are closely similar and yield distinctly analogous results. The differences in the immediate environment, which influence the proliferative processes of the mesenchyme in both organs, depend, therefore, not upon the different nature of tissues with which the mesenchyme enters into a correlation, but upon different developmental stages of the renal epithelial tissue. The stimulation of the mesenchyme and its first response in the embryos under experiment took place at 7 to 10 days of incubation. At this period the mesonephros has not only fully developed, but has already begun its involution, while the proliferative and differentiative processes in the metanephros are presently at their height. This difference may well explain the quantitative variations in changes observed in the mesenchyme of the mesonephros and metanephros after grafts.

*Mesenchyme of the mesonephros.*—The changes occurring in the mesenchyme of its caudal part only (the derivative of the nephrogenic cord) were studied. The first changes observed in the mesonephros after grafts do not require much comment, for they are identical with the proliferation and separation into mobile cells undergone by the mesenchyme in other regions of the embryonic body and already described for the mesenchyme of the allantois and of the muscles. Certain peculiarities are imposed on the process by the scarcity of space assigned at this time in the mesonephros to the mesenchyme, which, together with the capillaries, occupy the very narrow clefts between the renal tubules. But even in this respect the process does not present any exclusive feature, for in the parts of the organs in which the tubules are more sparse and the mesenchyme looser the process of mesenchymal proliferation leads to results analogous to those observed in the other regions of the body.

Figure 14 shows the striking changes undergone by the mesenchyme around a glomerulus and its secreting tubule in the mesonephros of an embryo of 13 days of incubation. This figure is a photograph of a preparation and therefore removes all doubts as to the authenticity of the process as well as to the intensity which it may

attain. Five days have passed in this case after the grafting of adult splenic tissue on the allantois of this embryo. The proliferation and transformation of numerous mesenchymal cells into mobile elements, which may be readily observed in the first 2 or 3 days after grafting, have led to remarkable changes in the stroma of the mesonephros. In figure 14 the glomerule and the various tubules are widely separated by a dense tissue, which is traversed by numerous capillaries. This tissue consists, for the greater part, of amoeboid granular cells easily identified with the various stages of granuloblastic differentiation of the hemoblast. Most of them are granuloblasts (myelocytes), though both completely differentiated granular leucocytes and numerous younger stages of hemoblasts are also found in these huge accumulations. Typical mesenchymal cells are scarce and in some regions would seem to hardly suffice to preserve the coherence of the organ. It is remarkable how an accumulation of renal tubules separated by spaces filled with amoeboid cells can still hold together. Though the development of the granuloblastic tissue may lead to huge granuloblastic accumulations, no formation of necrotic foci was observed, as described in the allantois, the muscles, and the spleen.

Not all of the organ may show such intense changes as illustrated in figure 14. In the central parts of the organ, where the mesenchyme originally is scarce, its proliferation and further differentiation never leads to the development of such heavy strands of granuloblastic tissue as are seen in this figure. Here the different segments of the renal tubules are much closer together and the lack of space may of itself prevent a more intensive proliferation of the mesenchyme. Some of the tubules are separated from each other by just a few fibrils; in this case, of course, they will retain their respective positions. But wherever mesenchyme is present, no matter how small the interstices between the windings of the renal tubules may be, a proliferation and further differentiation of the mesenchyme situated in these interstices regularly leads to the formation of larger and smaller islands and strands of granuloblastic tissue. The granular leucocytes and the granuloblasts are very mobile cells, and it is not a rare occurrence to find some of them traversing the walls of the vessels or situated within the lumen of the renal tubules; a couple of granular leucocytes may be seen in the lumen of a tubule in figure 14.

The study of the changes developing in the mesenchyme of the mesonephros, after grafting adult splenic tissue on the allantois of the embryo, has revealed hemopoietic potentialities in a new region of embryonic mesenchyme. The mesenchymal cells in the mesonephros during the functional period of this organ have lived in intimate symbiotic relations with the variously organized renal epithelia. The stimulation brought about by the presence of the splenic graft coincides with the beginning of the involution of this organ. The specific activity exercised by the renal epithelium might have exhausted the synthetic power of the cells, or else products elaborated during development of various organs in the embryo have injured it to such a degree that it degenerates and undergoes a final disintegration and resorption; or, finally, special vascular changes in the region of the mesonephros might have had an unfavorable effect on the organ. No definite data are

to be found in literature concerning the fate of the mesenchymal or connective-tissue cells present at that time in the mesonephros. Their active proliferation and differentiation, manifested after grafts at a time when the epithelial tissue begins its normal involution, is a direct proof of the great synthetic power belonging to the mesenchymal cells of the mesonephros. In some way the gradual lowering of the metabolic processes in the renal epithelium, with ensuing death, seems to be a rather favorable agent in bringing about an intensification of the proliferative processes in the mesenchymal cells and in the granuloblasts.

Though of a common origin, the mesenchyme of the mesonephros and its renal epithelium have diverged in their development. The removal of the substances excreted by the epithelium into the lumina of the renal tubules secures for the mesenchyme a protection against contact with possibly injurious substances and the mesenchyme in the mesonephros of a 7 to 10 days' embryo retains its proliferative and differentiative ability, as seen from the actual exercise of its granuloblastic potentiality. This potentiality, as follows from an analysis of the changes occurring after grafts in the mesenchyme of other organs, is a common property shared equally by all of the mesenchyme found at this time in the organism.

*Mesenchyme of the metanephros.*—Unlike the mesonephros, at the time when the graft of adult splenic tissue was made on the allantois of the embryo, the metanephros is the center of most intense organizing and proliferative processes; new renal tubules are developing, and those already present develop further into their different parts. The growth and development of the specific renal tissue seems to be little if at all affected by the common stimulation of the mesenchyme. The differentiation of definite parts of the nephrogenic cord appears as a specific process, at least under the conditions of the present experiments, as well as in typical development. The development of the metanephros follows its own course and attains results identical with those under normal conditions. The mesenchyme, however, which at this time is intimately intermingled with the nephrogenic tissue, detaches numerous cells just as in the other parts of the embryo already examined, and 2 or 3 days after the grafting was done—that is, on the eleventh day of incubation—large basophilic hemoblasts may be seen in the spaces between the renal tubules and the capillaries and around the newly developing renal units. At this early stage the circulating blood in the vessels of the metanephros does not show any marked changes in its cellular elements and contains only more or less differentiated blood cells. There is not the least doubt, therefore, that these hemoblasts develop from the loose mesenchyme more or less abundant at this time in the organ and are not cells which have immigrated from the vessels.

It is quite remarkable that in the regions of the developing metanephros in which the tubules are seen to originate, and which at this time consist of morphologically undifferentiated stellate and branched cells, comparatively few of the latter transform into mobile cells. The great bulk of the nephrogenic tissue organizes itself into the specific renal epithelium. Whether or not the nephrogenic tissue develops from two substantially different sources (for renal epithelium and stroma) under the aspect of a morphologically identical structure I can not at present say

definitely. It is true that the factors for the granuloblastic differentiation of the mesenchymal stroma become, under the present experimental conditions, so powerful as to transform a large amount of mesenchymal cells into granuloblasts even in the regions of the organism in which granulopoiesis has never occurred in a typical development. It would therefore be only natural to expect that, if the nephrogenic tissue proper possessed a potentiality for granuloblastic differentiation, it would have manifested it under the present condition. The granuloblastic potentiality may, however, still be a property of the nephrogenic tissue, but the factors for the specific organization of the nephrogenic tissue into renal epithelial tubules which are unknown to us may be of a more decisive nature for their realization.

The morphologically homogeneous mass of mesenchyme of which the nephrogenic tissue consists, and which is organizing itself on two different lines, may on the other hand prove to be of a different nature. A special study of its minute structure by various methods may possibly discover morphological differences which will account for the various lines of differentiation. The present study shows only that a part of the metanephric primordium (which under normal conditions remains inert and in the final stages of the development of the metanephros is represented by scanty connective-tissue cells), at the stage of 7 to 9 days of incubation, may be stimulated to hemopoietic activity and that its total potencies therefore are greater than those it is revealing under normal embryonic conditions.

It is a different question as to how long these mesenchymal cells are retaining the latent potencies. Maximov, in his paper on development of bone and bone-marrow in the kidney of the rabbit (1907) does not admit that the scanty connective-tissue cells of the stroma in the kidney possess hemopoietic potentialities. The bone-marrow, developing in the kidney after ligature of the renal vessels, is for him not of local origin, because the "sehr zellarmes spärliches interstitielles Bindegewebe enthält im normalen Zustande sicher keine Spur von myeloiden Elementen. Dass aus gewöhnlichen Bindegewebszellen, Fibroblasten, Myeloidgewebe entstehen könnte scheint Niemand ernstlich zu glauben."

I endeavored to solve this problem by transplanting adult kidney tissue on the allantois of the embryo. Here the mesenchymal constituents of the adult spleen have been seen to transform into hemopoietic, or, more specifically, into granulopoietic tissue. It was hoped that the behavior of the stroma of the adult kidney in the allantois might give some further information about its potentialities. The experiments carried out gave very decisive data concerning the ability of the renal epithelium to further proliferate, its tenacity to retain its epithelial arrangement, certain phases of its function, and also as to the great digestive power of the mesenchymal and endothelial cells situated between the renal tubules. No definite data were obtained concerning the differentiative ability of these cells. A detailed account of the growth of adult and embryonic kidney tissue on the allantois can not be presented here; a few words will suffice for our present purpose.

The growth of the transplanted adult kidney tissue has never been observed to be as intense as that of the embryonic kidney. It was observed, moreover,

that after 10 to 12 days of growth on the allantois the grafts never contained any necrotic tissue; but a study of the earliest stages (1 to 4 days of growth) revealed that only those renal tubules and glomerules survived which were adjacent to the embryonic mesenchyme of the allantois. A great number of them not so favorably situated appeared necrotic after 2 days of their existence in the allantois. The epithelial cells of all these tubules died and disintegrated. The blood-cells present at the time of the graft in the capillaries also succumbed. The fate of the vascular endothelium and the scanty connective-tissue cells in the interstices between the renal tubules and the lumen of the vessels was different. They now appeared swollen, their bodies well limited, sometimes widely separated from each other, their nuclei enlarged and oval, their cytoplasm intensely basophilic. At present I can not go into the details of the process, but there is no doubt that an active digestion of the necrotic epithelial cells and of the blood-cells took place by the surviving cells, the vascular endothelium, and the connective-tissue cells. I do not have at present any criteria which would enable me to distinguish them in relation to their digestive power; 2 and 3 days after the grafting both kinds of cells appeared intermingled and their specific morphological characters were no longer distinguishable. Though the renal epithelium seemed to undergo extracellular digestion, and blood-cells were in great numbers incorporated in the cytoplasm of the cells, no distinction could be made between the endothelial cells and the connective-tissue cells in relation either to structure or digestive capacity.

The digestive power of the endothelial and connective-tissue cells lying between the renal epithelial tubules completed the elimination of the dead cells, blocks of unaltered protein, 3 to 5 days after grafting; that is why I never encountered any necrotic foci in later stages of kidney grafts; 3 to 5 days after grafting, however, numerous embryonic mesenchymal cells grew from the allantois into the graft and it was no longer possible to distinguish between the embryonic and the adult cells. Occasionally single cells, in other places large groups of them, detached themselves from the common syncytium and underwent a granuloblastic differentiation, but it could no longer be decided whether these foci of granuloblastic tissue had their origin in the connective tissue of the transplanted adult kidney or whether they were derived from the ingrown mesenchyme of the embryo. Therefore I must leave it undecided whether or not the endothelial and connective-tissue cells of the adult kidney possess a hemopoietic potentiality. The study of their fate in grafts of adult kidney has, however, demonstrated their great digestive power.

#### MESENCHYME IN OTHER REGIONS OF THE EMBRYO BODY.

There is no need of a detailed analysis of changes observed after grafts in the mesenchyme in other regions of a 7 to 8 days' embryo. A brief survey will be sufficient in order to show that they are analogous to those already described in the muscles, sex-glands, kidneys, etc., and vary only with the relative scarcity or abundance of mesenchyme in a definite region of the embryo body at that time.

Liver, pancreas, suprarenal glands, intestine, the axis of the developing feathers, the connective tissue of the derm, the adventitia of the vessels, and the

perineurium are found 5 to 7 days after grafting to be thickly infiltrated with, if not entirely transformed into, mobile granular cells. A study of the early stages in the development of this granuloblastic tissue leaves no doubt as to its local origin. The heavy layers of granuloblastic tissue into which the adventitia and the perineurium are transformed, as well as the discrete strands of the same tissue in other organs, are the products of an intense proliferation of mesenchymal cells detached from the local mesenchymal syncytium and undergoing further unavoidable differentiation. This is not an outgrowth of settlers brought into the different organs by the blood-current. The isolation of the mesenchymal cells (primarily in syncytial and even in plasmodial connections with each other), their proliferation, and their further granuloblastic transformation are processes which do not necessarily require observations on living tissue under the microscope and are easily determined in preparation of adequately fixed and stained material. A further corroboration of the local origin of the granuloblastic tissue is given by a study of the circulating blood in the early stages of the mesenchymal transformation. At the time when great numbers of amœboid cells are liberated in the mesenchyme the circulating blood, both in the large and small vessels, is normal and consists of more or less completely differentiated elements. Only in well-advanced stages of the myeloid metaplasia of the mesenchyme, as will be seen later, does the blood reflect the processes taking place in the mesenchyme. At this time the blood in the embryos under experiment offers a picture very much like that found in the leucæmia (fig. 17).

*Mesenchyme of the liver.*—Figure 10 shows the changes found in the liver at the end of the seventh day after grafting. The connective tissue in the bird liver being very scanty, nevertheless constitutes a starting-point for the liberation of amœboid cells which subsequently proliferate and differentiate. Accumulations of hemoblasts and granuloblasts are formed and surround every vessel in the form of a heavy coat. Single rows of hemoblasts and granuloblasts are often found between the capillaries and the liver cells. They are probably derived from mesenchymal cells analogous to those which in the adult mammal are known as Kupffer cells. In an advanced stage of granuloblastic transformation of the mesenchyme in the liver, as represented by figure 10, numerous granuloblasts and hemoblasts may be seen within the lumen of the vessels. It is remarkable that they appear first in the capillaries and veins, and only much later do they become conspicuous in the arteries also. The hemoblasts and granuloblasts developing from the mesenchyme around the capillaries apparently find an easy access into their lumina and are carried farther by the veins, in which, even in later stages, they appear in relatively greater proportion than in the arteries.

*Mesenchyme of the adrenal.*—While it is still easy to follow the local origin of the hemoblasts and the granuloblasts in the liver, especially around the larger vessels, the study of this process in the adrenal is obscured by the extreme density of the tissue proper of the organ and by the scarcity of the mesenchyme. The strands of the epithelial tissue, as seen in figure 6, are separated by large capillaries and groups of chromaffin or phœochrom cells, and by sympathetic ganglion cells.



Very little is known about the mesenchymal constituents of the suprarenal. Kose, however, mentions that elements of lymphatic tissue and sympathoblasts are extremely similar. It is no longer difficult to draw a distinction between these cells 6 to 7 days after grafting, all the elements of the lymphatic tissue having undergone a granuloblastic differentiation. Figure 6 shows a small part of the adrenal tissue 7 days after the grafting of adult splenic tissue on the allantois of the embryo. In addition to the erythrocytes, the capillaries at this stage contain a great number of lymphoid hemoblasts. Granuloblasts are found outside the vessels, among the groups of chromaffin cells, between the capillaries and the epithelial strands, and even in the midst of these strands. The different kinds of cells are easily identified by their structural characters. The sympathetic ganglion cells have a structure similar to such cells elsewhere and usually are grouped together in large numbers, though also found scattered between the chromaffin cells, as shown in figure 6. The granuloblasts form irregular accumulations, sometimes large and separating the tissue proper of the adrenal; usually, however, they are found scattered, singly and in small groups. Occasionally lymphoid hemoblasts are found and easily identified, their amœboid nature offering a good criterion for their identification. It is difficult to determine the origin of the granuloblasts in the adrenal. They might have been derived from the local mesenchymal cells or from the hemoblasts brought in by the circulation. Groups of granuloblasts (fig. 15, *grbl.*) situated in the center of the epithelial strands are certainly cells which have come from other regions. The complexity and density of the tissue in the adrenal primordium obscures also the study of the early stages after grafting, during which the origin of the granuloblastic tissue in other organs is usually easily determined. However, the data obtained by study of the myeloid metaplasia of the mesenchyme in other regions of the embryo make it probable that here, also, at least some of the granuloblasts are derived locally from the normal mesenchymal constituents of the organ.

*Circulating blood.*—A few words will suffice to indicate the changes which the circulating blood is undergoing during the myeloid metaplasia of the mesenchyme. It has already been pointed out that in the early stages of the developing granuloblastic transformation of the mesenchyme the blood in the vessels does not differ from that encountered under normal embryonic conditions. As the hemoblasts and granuloblasts develop in greater quantities, they accumulate in the stroma of all the organs. As amœboid cells they easily find access into the capillaries and in later stages the blood in the vessels shows characteristic changes in the relative numbers of its cells. The blood is undergoing changes which have been described in leucæmias. Figure 17 illustrates the contents of the capillary net in the adventitia of a large vessel. A great number of hemoblasts and younger forms of erythroblasts distend the capillary net. In still later stages granuloblasts and granular leucocytes become especially numerous in the capillaries and veins and the circulating blood offers then a picture characteristic of myeloid leucæmia.

*Loose mesenchyme of the body.*—It is already known that the chick does not possess lymph-glands. The lymphatic tissue is, however, present in the organism in rather large amount. Instead of being well localized in the form of circum-

scribed agglomerations of lymphatic tissue, the lymphatic elements are scattered and diffusely infiltrate the loose connective tissue. If grouped in larger numbers the accumulations of lymphatic cells may attain a size just large enough to be discernible by the naked eye. The patches of lymphatic tissue disseminated in the loose connective tissue begin to appear in the later stages of embryonal life, but attain their full development only after hatching. I have already had occasion, in one of my previous papers (1916*c*), to briefly sketch their structure and origin and also to point out the fact that the loose mesenchyme, which in the typical development of chick differentiates into lymphatic cells, may after grafts follow another line of differentiation—*i. e.*, to transform into granuloblastic tissue.

Wherever loose mesenchyme is present in the embryo numerous cells are seen after grafts of adult splenic tissue to change their shape from stellate to spherical, and to free themselves. Part of these cells hypertrophy, soon become basophilic, and appear in the form of lymphoid hemoblasts. Others, though attaining a considerable size, nevertheless remain slightly basophilic and are often seen to protrude small and thin processes on their whole surface. These cells are the histiotopic or resting wandering cells. Both types, the hemoblastic and the histiotopic wandering cells, in the early stages after grafting, are represented in great numbers in the loose mesenchyme. Swarms of amœboid cells wander around and quite frequently intermediate forms are seen, leaving no doubt as to their easy transition. As previously stated, the hemoblastic type develops preferably around large, thin-walled vessels with slow circulation. The histiotopic or resting wandering type, on the contrary, is encountered more frequently in regions with scanty vessels.

Both types of cells may be found scattered or grouped together in large or small agglomerations. The histiotopic wandering cells manifest a tendency to flow together and to form plasmodial masses. Individual cells may secondarily detach themselves and acquire the structural features of the hemoblastic type. Seldom do the cells of the histiotopic type manifest a tendency to granuloblastic differentiation without previously having transformed into a lymphoid hemoblast. One may find single wandering cells of this type containing a couple of acidophilic granules, but it is difficult to decide whether these granules have been elaborated by the cell itself or whether they are remnants of ingested and digested cells. The histiotopic wandering cells, wherever they are situated, display great phagocytic activity. This activity in the particular case is directed chiefly against granular leucocytes in the loose connective tissue which do not find an outlet into the circulation.

Agglomerations of lymphatic hemoblasts are frequently observed in the loose mesenchyme and they regularly undergo a granuloblastic transformation. Agglomerations of such cells develop chiefly in the neighborhood of vessels. Figure 8 shows a longitudinal section of a vessel, accompanying a small nerve. Both structures are surrounded by strands of hemoblasts. Hemoblasts are found even within the small nerve. In figure 16 large accumulations of hemoblasts under the mucosa of the pharynx are seen to have already transformed into granuloblasts and the normally loose tissue is made heavy and dense by the presence of innumerable amœboid cells in various stages of granuloblastic transformation. The adventitia of a vessel transformed into a heavy coat of granuloblastic tissue is seen in figure 11.

The bulk of the loose mesenchyme which occupies the axis of a growing feather is seen to be transformed into granuloblastic tissue in figure 15. The cells of the young fat tissue (fig. 7) maintain their structure, but if mesenchymal cells remain unchanged between them, they are transformed into hemoblasts and granuloblasts, as shown in figure 7.

Wherever accumulations of granuloblasts attain considerable size and the final products of their further differentiation (the granular leucocytes) do not find an outlet into the circulation, they disintegrate. If in small numbers, they are ingested by the histiotopic wandering cells. If the centers of granuloblastic tissue attain, however, a considerable size, and granular leucocytes are massed together, the whole focus may become necrotic, and it is not a rare occurrence to find such necrotic centers anywhere in the mesenchyme. They represent as many centers of inclusions of non-split protein, which incite in the embryo a digestive activity in whatever tissue is capable of manifesting it.

#### CONCLUSIONS.

The study of the various organs with granuloblastic transformation of the mesenchyme leads naturally to the conclusion that the loose mesenchyme in an embryo of 7 to 9 days' incubation is polyvalent and equipotential. The mesenchyme under normal conditions may manifest, in definite regions of the organism and at definite stages, a hemopoietic potency, or may remain inert for an indefinite time. It may, however, be so stimulated as to proliferate with the production of numerous free cells and also to hypertrophy with a subsequent differentiation.

The embryonal mesenchyme as late as 7 to 8 days of incubation in a chick embryo is therefore capable of doing more than it does in typical development. Its great assimilative and proliferative power, conferring upon its cells a potential immortality, has been already established in tissue-cultures by Burrows and Carrel (1911, 1912, 1913) for the embryo, and by Maximov for the adult (1916). The culture method does not, however, offer to the connective-tissue cells conditions adequate for their further so-called progressive differentiation. These cells outside of the organism are evidently capable of retaining their metabolism in the culture medium, for they do not show there any sign of qualitative changes. Their metabolism in the cultures may evidently be very active, because they are capable of not only maintaining themselves, but of intensely proliferating. So far, however, it has not been determined by the cultural method whether a connective-tissue cell, a derivative of the embryonal mesenchyme, may outside of the organism undergo further differentiation.

A preliminary step seems to be indispensable in any of the lines of hemopoietic differentiation of the mesenchyme; *i. e.*, a separation of the mesenchymal cellular syncytium into single cells. The factors effecting this separation in the organism have not been determined. The consistency of the medium was pointed out by Uhlenhuth (1915) as a factor determining the shape of cells, a liquid medium rounding them up. The same factor is chiefly active in Rous's method of isolating individual cells growing in the culture by tryptic digestion of the clot (1916). After such treatment, growing connective-tissue cells, even though forming in the culture

a syncytium, assume a spherical form as soon as the clot disappears and they remain in a liquid medium. In this case, however, the trypsin may have attacked the thin cytoplasmic processes and concurred in the isolation of cells.

The syncytial connections of the cells seem to secure a common metabolism for them and to hinder their further differentiation. The isolation of cells evidently facilitates a direct interaction of the cells with the environment, and changes ensue as a result of the interaction of the physico-chemical constituents of the cell and of the environment.

Suggestions were made by me as to the nature of the factors determining the particular line of the hemopoietic differentiation of a mesenchymal cell after it has been detached from the common syncytium (1908, 1916*a*, 1918*a*). The erythropoietic differentiation of a hemoblast seems to be closely associated with its intravascular situation. The factors for the other lines of the hemopoietic differentiation can at this time hardly be formulated with any degree of certainty. These factors undoubtedly must be of a very definite nature, since now it is evident that the same polyvalent hemoblast is the starting-point for the various lines of hemopoietic differentiation.

The results of tissue culture, though very definite regarding the unlimited proliferative ability of adult connective-tissue cells, so far has not demonstrated a differentiative power in them. This is, of course, not an argument for a definitive loss of such a power. The differentiating factors not being definitely determined, we can not at will introduce them into our culture methods. To determine the degree of the differentiative ability of a common adult connective-tissue cell is the task of the future. A granuloblastic capacity of the adult reticular cell of the spleen has been established by Danekhoff in grafts of adult splenic tissue on the allantois (1918*b*). A generalized granulopoietic differentiative power of the loose mesenchyme at 7 to 9 days of incubation is, I hope, established by the work which forms the basis of this paper. Not only in the regions of the embryonic body, in which normally some of the cells of the mesenchyme show a granuloblastic differentiation at an earlier stage, could the mesenchyme be stimulated anew, but stimulation to such activity could be effected in parts of the organism in which the mesenchyme has never before shown such potency nor would, under normal conditions, ever have exhibited it. On the basis of the present experiments and observations both the intensity of the various lines of hemopoietic activity of the mesenchyme and the process itself seem to be dependent, relative, *provoqués*.<sup>1</sup>

The hemopoietic, in this case the granulopoietic, activity, being established as a dependent differentiation (*differentiatio relativa*, Roux; *differentiation provoquée*, Brachet), the next step would be to determine the factors which may incite it. However, a great uncertainty prevails as soon as we try to formulate more definitely the causes of the development of the intensive granulopoiesis after grafts of adult

---

<sup>1</sup>I should like to add a note which, though irrelevant to the present subject, is based upon the results of the present work. The study of the history of the mesenchymal differentiation seems to add some probability to the opinion that immortality and differentiation of living matter are phenomena usually excluding each other. A mesenchymal cell is immortal as long as it remains as such; that is to say, as long as it retains its characteristic metabolism. Its differentiation presupposes a change in its constitution, a change which in the case of the hemopoietic differentiation of the mesenchyme finally leads to a loss of its proliferative and assimilative powers—that is to say, to its death.

splenic tissue. The presence of such tissue in the economy of the embryo is followed by a myeloid metaplasia of the mesenchyme in the host. Moreover, the undifferentiated mesenchyme of the adult splenic tissue in the graft itself undergoes such differentiation. There must be a common cause for both of these phenomena.

Some valuable information concerning these factors may be gained by comparison of the present results with other well-known cases of excessive production of granular leucocytes. Though these instances concern mammals, the cause in both can not differ much, since the whole process of granuloblastic differentiation is found to be the same for both classes of animals. The granulopoietic activity of the bone-marrow is greatly increased in an adult organism by acute inflammatory processes. A granuloblastic differentiation (the myeloid metaplasia) can be incited in lymphatic organs by various agents. Discussing in one of my previous publications (1916*e*) this effect upon the mesenchyme of the host's spleen, I stated:

"It is important to notice that the myeloid metaplasia is produced by different causes. The toxins of various bacteria, the specific products of metabolism of malignant tumors, finally, inorganic chronic intoxications, may incite an extensive myeloid metaplasia. It is difficult to conceive, in such qualitatively different agents, a specific stimulating influence on the stem cells. The response to the action of these factors is specific in so far as it is exhibited by a certain kind of tissue (even not of cells). The stimulus itself may largely vary."

At that time the process of myeloid metaplasia presented itself to my mind as a result of the direct action of the factors introduced upon the mesenchyme, and therefore each of them must, in my opinion, have found in the same cells different receptors in order to be capable of bringing them to a proliferation. I do not know how otherwise we could explain an identical result obtained by such different factors as acute inflammation, inorganic intoxications, or malignant tumors; that is to say, if the myeloid metaplasia is conceived as resulting from a direct action of the agents cited upon the mesenchyme. But the myeloid metaplasia may be the result of a reaction of the mesenchyme to some secondary changes produced in the organism by the different factors and similar in all cases. It is possible, indeed, to find in the seemingly so different etiology of the myeloid metaplasia features common to all the cases. My present task will be only to point them out as factors which may be in some way connected with the developing activity in the mesenchyme.

In acute infections, besides the appearance in the organism of various new substances secreted by the bacteria, a more or less extensive injury of normal tissue takes place. Different kinds of cells die and remain in the organism in the form of small particles of unaltered protein. Though new to the organism, this situation is readily met with. The phagocytic and high digestive power of the endothelial cells of the cellular reticulum in the lymphatic organs and that of the mature fibroblasts (in the case of nerve degeneration, for example) toward various protein inclusions is well known and is usually sufficient in order to localize and to overcome a banal infection. Small protein particles in the form of dead cells are directly ingested by the mesenchymal cells and undergo an apparently complete intracellular digestion. A local infection of short duration will not produce a myeloid metaplasia of the undifferentiated mesenchyme in all the hemopoietic organs, but will only increase

a production of granular leucocytes in the bone-marrow. During infection, appearance in the organism of both homologous and heterologous proteins takes place. This never occurs under normal conditions, amino-acids only being conveyed to the different tissues of the organism. It is difficult in this case to determine whether the stimulation of granulopoiesis is in some way connected with one of the two factors, or with both of them. Furthermore, the appearance in the organism of proteins or of phases of their digestion not completely reduced to their "building-stones," the amino-acids, necessarily calls forth, as shown by Abderhalden, a liberation of enzymes into the circulation, their presence here being easily determined by the dialyzation method. Not only can the appearance of proteins directly stimulate the mesenchyme, but, what is even more probable, the isolation of the mesenchymal syncytium into separate cells can be effected by a partial digestion of the thin cytoplasmic processes by the action of circulating enzymes. Support to such a view may be found in the work of Rous, in which it is shown that a tryptic action of short duration will digest the clot of the medium and probably the thin syncytial processes of the cells growing in it, but not the cells themselves. How much probability such explanation has in itself future work will show. It is suggestive, however, that myeloid metaplasia, different as its etiology may appear, is always preceded by destruction inside of the organism of living material—*i. e.*, by the appearance in the organism of dead cells, or particles of unsplit protein, and therefore (according to Abderhalden) by liberation of enzymes.

If now we return to the analysis of factors involved in the production of the extensive myeloid metaplasia in my embryonic material, we always find the graft of adult splenic tissue to be not only the center of growth of living material, but also to include smaller or larger blocks of necrotic masses—*i. e.*, of masses of unsplit protein. It seems, even, that the larger these accumulations of necrotic tissues are the more intensive becomes the dissolution of the syncytial connections of the mesenchyme in the embryonic body and its subsequent extravascular granulopoiesis. In numerous cases its action may become a vicious circle, the intensive granulopoiesis itself leading to the appearance of new necrotic centers (spleen, muscles, loose connective tissue, etc.), thus strengthening the initial stimulation.

Effects upon the embryonic mesenchyme of grafts of different tissue will be discussed in a special paper. It is, however, remarkable that only grafts of those tissues will produce an extensive stimulation of the embryonic mesenchyme which for a certain length of time include centers of necrotic tissue.

There remains but little probability that factors for the mesenchymal stimulation in the embryo may be found in the various processes constituting the growth of adult splenic tissue in the graft. The proliferating mesenchyme of the grafted splenic tissue itself undergoes granuloblastic transformation; it is, therefore, itself under the control of the factors governing the granuloblastic differentiation of the embryonic mesenchyme.

*January 1918.*

## BIBLIOGRAPHY.

- BORING, A. M., 1912. The interstitial cells and the supposed secretion of the chicken testis. *Biol. Bull.*, vol. 23, p. 141-153.
- and R. PEARL, 1917. Sex studies. Interstitial cells in the reproductive organs of the chicken. *Anat. Rec.*, vol. 13, p. 253-268.
- BRACHET, A., 1917. *L'œuf et les facteurs de l'ontogenèse*. Paris.
- BRAUS, H., 1903. Versuch einer experimentellen Morphologie. *Munch. med. Wochenschr.*, vol. 50, p. 2076.
- BURROWS, M. T., 1913. The tissue culture as a physiological method. *Transac. Congress. Amer. Physicians and Surgeons*, vol. 9, p. 77-90.
- CARREL, A., Present condition of a strain of connective tissue twenty-eight months old. *Jour. Exper. Med.*, vol. 20, p. 307-386.
- and M. BURROWS, 1911. Cultivation of tissues in vitro. *Jour. Exper. Med.*, vol. 13, p. 387-396.
- DE CILLETLS, F., 1912. Interstitial testicular cells and secondary sex-characters. Summary in *Jour. R. Microsc. Society*, December.
- DANCHAKOFF, V., 1908. Untersuchungen über die Entwicklung des Blutes und Bindegewebes bei den Vögeln. I. Die erste Entstehung der Blutzellen beim Hühnerembryo und der Dottersack als Blutbildendes Organ. *Anat. Hefte*, Bd. 137, Heft. 113, p. 473-587.
- 1909. Untersuchungen über die Entwicklung von Blut und Bindegewebe bei Vögeln. Das lockere Bindegewebe des Hühnchens im fetalen Leben. *Arch. f. mikr. Anat.*, Bd. 73, p. 417-481.
- 1916a. Über die Entwicklung des Blutes in den Blutbildungsorganen (Area vasculosa, Dottersackanhänge, Knochenmark, Thymus, Milz und lockeres Bindegewebe) bei *Tropidonotus matrix*. *Arch. f. mikr. Anat.*, Bd. 87, p. 497-581.
- 1916b. The loose connective tissue as a seat of lymphogranulopoiesis. *Abstr. Proc.*, *Anat. Rec.*, vol. 10, p. 192.
- 1916c. The wandering cells in the loose connective tissue of the bird and their origin. *Ibid.*, p. 483-492.
- 1916d. The differentiation of cells as a criterion for cell identification, considered in relation to the small cortical cells of the thymus. *Jour. Exper. Med.*, vol. 21, p. 87-105.
- 1916e. Equivalence of different hematopoietic anlagen (by method of stimulation of their stem cells). *Amer. Jour. Anat.*, vol. 20, p. 255-308.
- 1918a. Cell potentialities and differential factors considered in relation to erythropoiesis. *Amer. Jour. Anat.*, vol. 24, p. 1-30.
- 1918b. Equivalence of different hematopoietic anlagen (by method of stimulation of their stem cells). II. Grafts of adult spleen on the allantois and response of the allantoic tissues. *Ibid.*, p. 127-173.
- FELIX, W., und A. BÜHLER, 1906. Die Entwicklung der Harn und Geschlechtsorgane. *Handbuch der vergleichenden u. experimenteller Entwicklungslehre der Wirbeltiere* Herausgegeben von Oskar Hertwig, Bd. 3<sup>1</sup>, p. 81.
- GODLEWSKI, EMIL, 1902. Die Entwicklung des Skelet- und Herz-muskelgewebes der Säugethiere. *Arch. f. mikr. Anat.*, Bd. 60, p. 111-156.
- HARRISON, ROSS G., 1918. Experiments on the development of the fore limb of *Amblystoma*, a self-differentiating equipotential system. *Jour. Exp. Zool.*, vol. 25, p. 113-161.
- HERBST, C., 1895. Ueber die Regeneration antennen-ähnlicher Organe an Stelle von Augen. *Arch. f. Entw. Mech.* Bd. 11.
- LEWIS, W. H., 1901. Experimental studies on the development of the eye in Amphibia. I. On the origin of the lens. *Amer. Jour. Anat.*, vol. 3, p. 505-536.
- 1907. Experimental studies on the development of the eye in Amphibia. III. On the origin and differentiation of the lens. *Amer. Jour. Anat.*, vol. 6, p. 473-508.
- MAXIMOV, A., 1907. Experimentelle Untersuchungen zur postfötalen Histogenese des myeloiden Gewebes. *Ziegler's Beiträge*, Bd. 41, p. 122-166.
- 1916. The cultivation of connective tissue of adult mammals in vitro. *Arch. Russes d' Anat.*, ed d' Embr., T. 1, fasc. 1.
- POSCHARISSKY, J. F., 1905. Ueber heteroplastische Knochenbildung. *Ziegler's Beiträge*, Bd. 38, p. 135-176.
- REEVES, J. B., 1915. On the presence of interstitial cells in the chicken's testis. *Anat. Rec.*, vol. 9, p. 383-386.
- ROUS, P., and F. S. JONES, 1916. A method for obtaining suspension of living cells from the fixed tissues and for the plating out of individual cells. *Jour. Exper. Med.*, vol. 23, p. 549-554.
- SACERDOTTI, C., und G. FRATTIN, 1902. Ueber die heteroplastische Knochenbildung. *Virchow's Arch.*, Bd. 168, p. 431-443.
- SOLUCHA, 1908. Ueber die Zellformen des Bindegewebes und Blutes der Vögel im normalen Zustand und bei Entzündung. *Inaug. Dissert.*, St. Petersburg.
- SWIFT, C. H., 1914. Origin and early history of the primordial germ-cells in the chick. *Amer. Jour. Anat.*, vol. 15, p. 483-516.
- 1915. Origin of the definitive sex-cells in the female chick and their relation to the primordial germ-cells. *Amer. Jour. Anat.*, vol. 18, p. 441-470.
- UHLENHUTH, E., 1915. The form of the epithelial cells in cultures of frog skin and its relation to the consistency of the medium. *Jour. Exp. Med.*, vol. xxii, p. 76-104.

## EXPLANATION OF FIGURES.

The figures on Plates 3, 4, and figure 16 are photographs of preparations. All the other figures were drawn with the camera lucida at stage level with Zeiss apochromat 2 mm., oil-immersion objective. The compensatory ocular S was used for figures 1, 2, and 3, ocular 6 for all others.

### ABBREVIATIONS IN ALL FIGURES THE SAME:

C., capillary	Grbl., granuloblast
Ende., endothelial cell	Gr., granulocyte
Erb., erythroblast	Hbl., hemoblast
Erc., erythrocyte	Msc., mesenchymal cell

#### PLATE 1.

FIG. 1. Small muscular area in the wing of an embryo 9 days old, 2 days after grafting adult splenic tissue on its allantois. Mfn. Muscular fiber nuclei. Wc. Wandering cells.

FIG. 2. Cleft between muscle bundles in a tangential aspect. Wandering cells in great numbers, some of them as basophilic hemoblasts, others more approaching the structure of histiotopic wandering cells, some of the wandering cells forming plasmodial masses.

FIG. 3. Granuloblastic differentiation of the mesenchymal strands between muscular fibers, five days after grafting.

FIG. 4. Part of the testis. The greater part of the mesenchyme between the testis cords is transformed into amoeboid cells, hemoblasts, and granuloblasts. Tc., testis cord, Gc., germ cells.

#### PLATE 2.

FIG. 5. Part of ovarian tissue in proximity with the germinal epithelium. Granuloblastic transformation of the mesenchyme in the ovary eight days after grafting.

FIG. 6. Part of adrenal tissue. Adr. e., adrenal epithelium. Phe., phäochrom cells. X, phäochromoblasts.

FIG. 7. Area of fat-tissue with numerous granuloblasts between the fat-cells.

#### PLATE 3.

FIG. 8. Area of muscular tissue in leg. Heavy strands on hemoblastic tissue separate the groups of muscular fibers.

FIG. 9. Same as figure 3.

FIG. 10. A vessel in the liver. Its wall is heavily infiltrated with hemoblasts and granuloblasts.

FIG. 11. Area of granuloblastic tissue around a large vessel.

#### PLATE 4.

FIGS. 12. and 13. Parts of ovarian tissue with an extensive granuloblastic transformation of its mesenchyme.

FIG. 14. Myeloid metaplasia of the mesonephros. Glomerule and convolute tubules wrapped into a dense granuloblastic tissue.

FIG. 15. Anlage of a feather. A great part of the mesenchyme in its axis transformed into granuloblastic tissue.

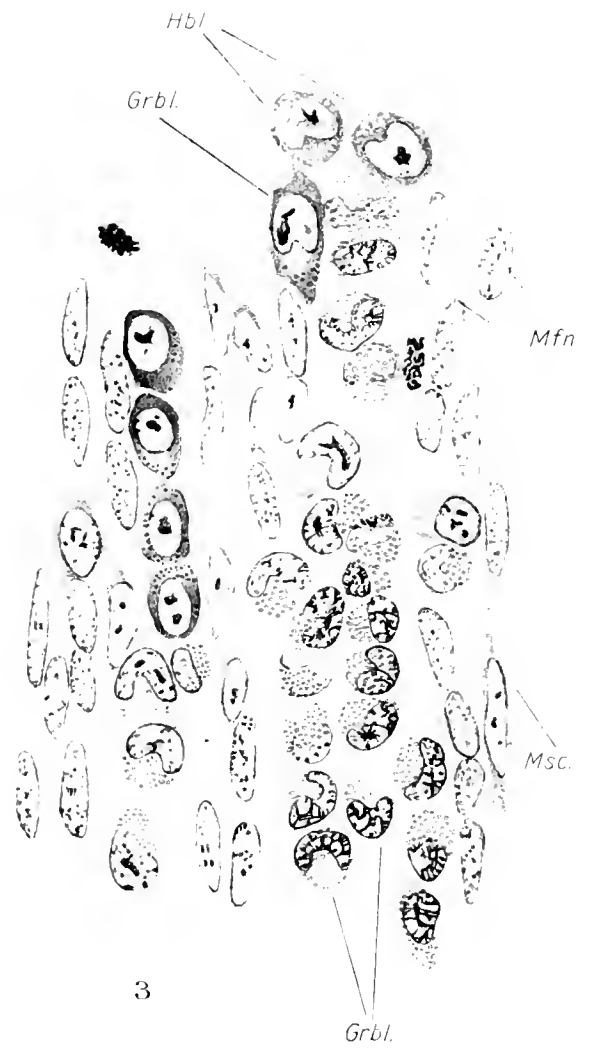
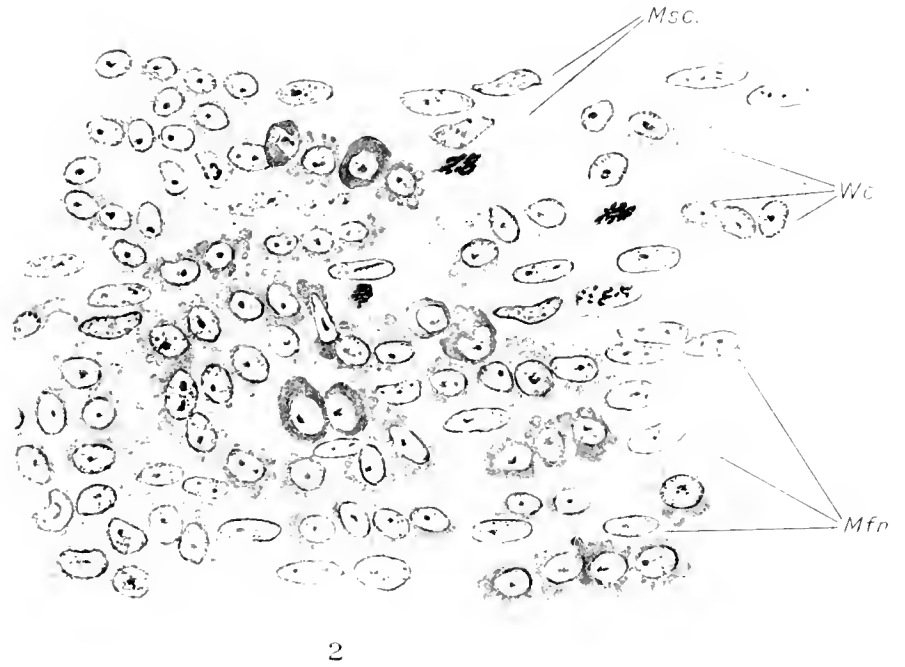
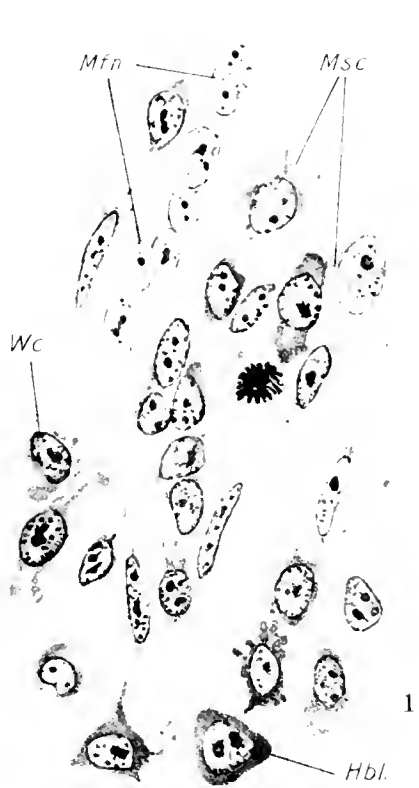
#### PLATE 5.

FIG. 16. A papilla of the pharyngeal mucosa. A great part of its stroma is transformed into granuloblastic tissue.


FIG. 17. Capillary net in the connective tissue septa between the muscle bundles in the leg, 8 days after grafting. The capillaries are distended by hemoblasts and young stages of erythroblasts, the mesenchyme between them transformed into granuloblastic tissue.

FIG. 18. Longitudinal section of small nerve (n) and vessel. In the perineurium and in the mesenchyme around the vessel numerous free cells are detached from the mesenchymal syncytium. These develop into hemoblasts and granuloblasts.

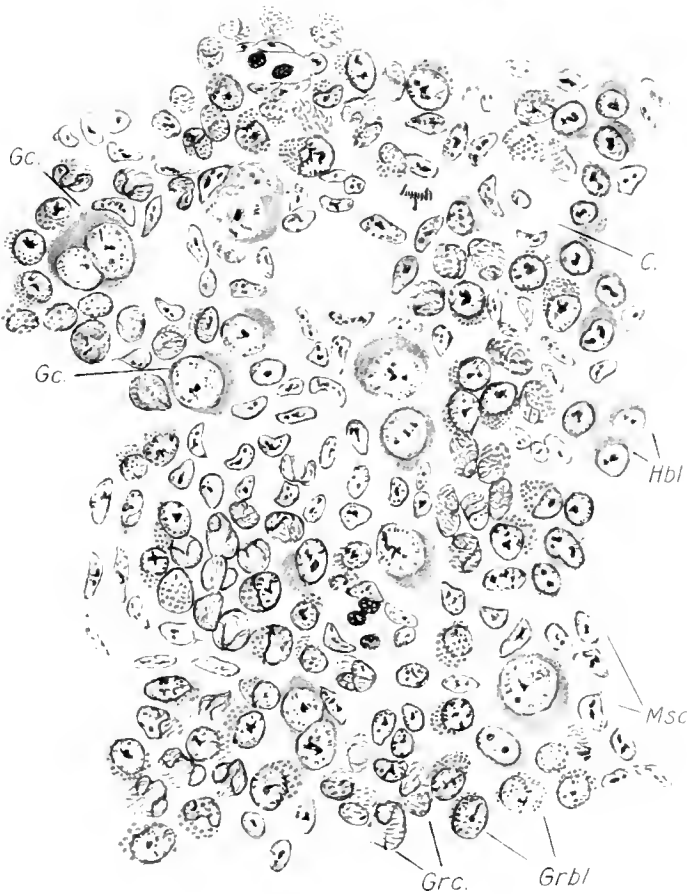



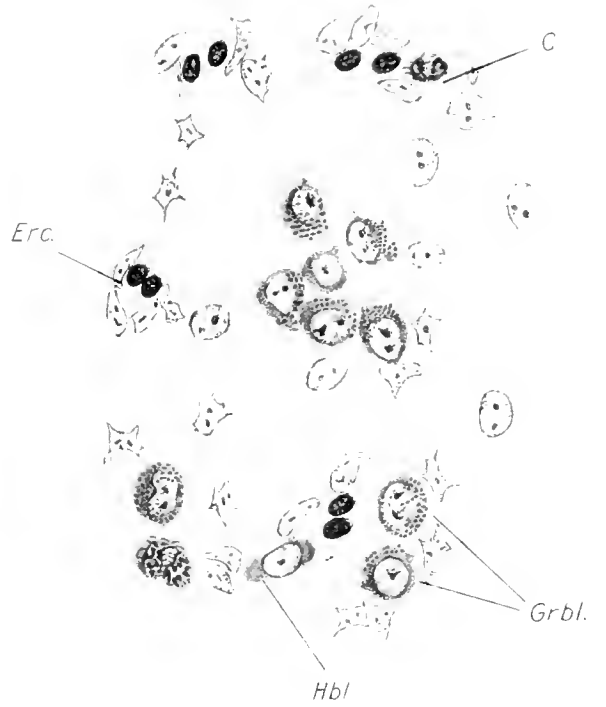




6




5

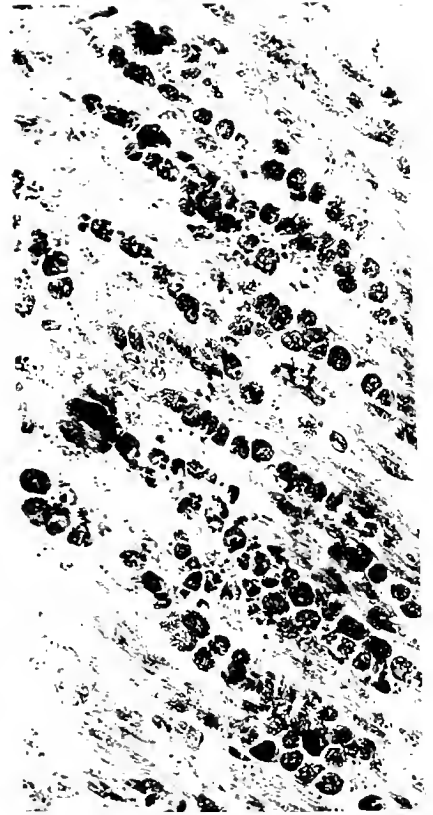


7





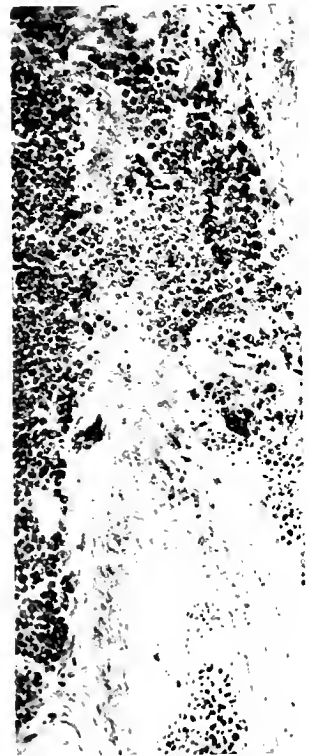
8



9




10

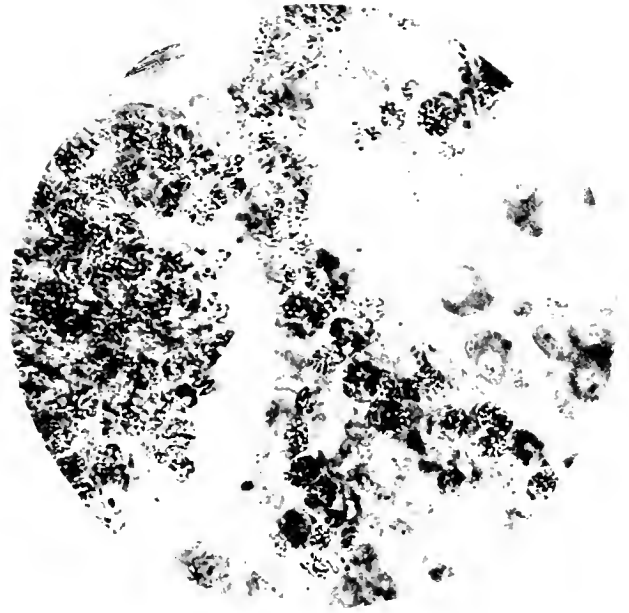


11

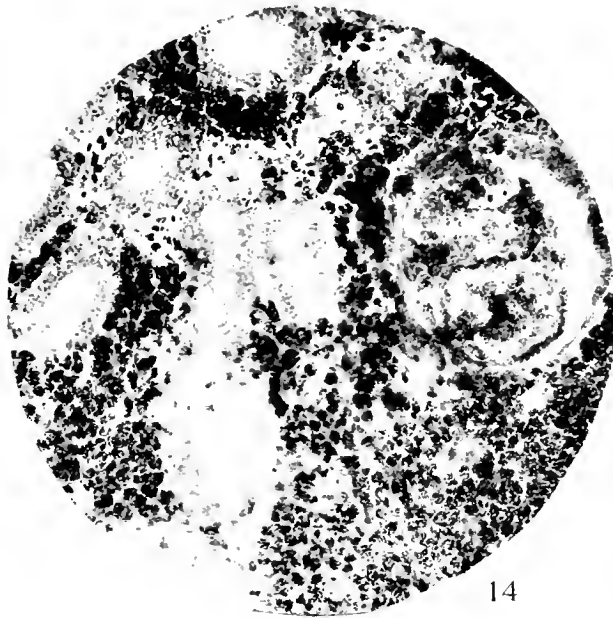



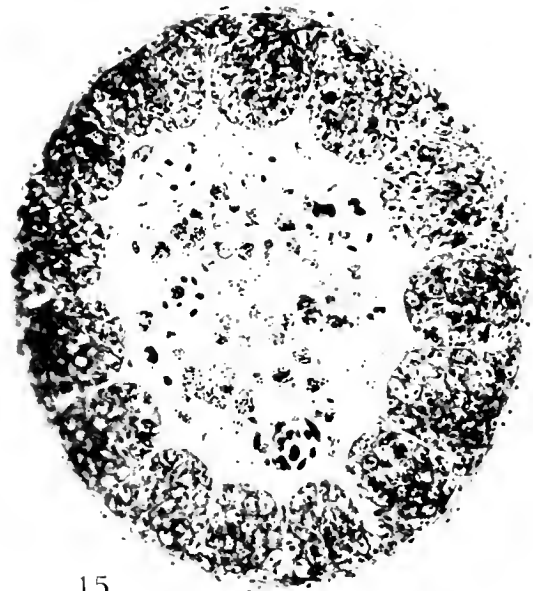
12



13



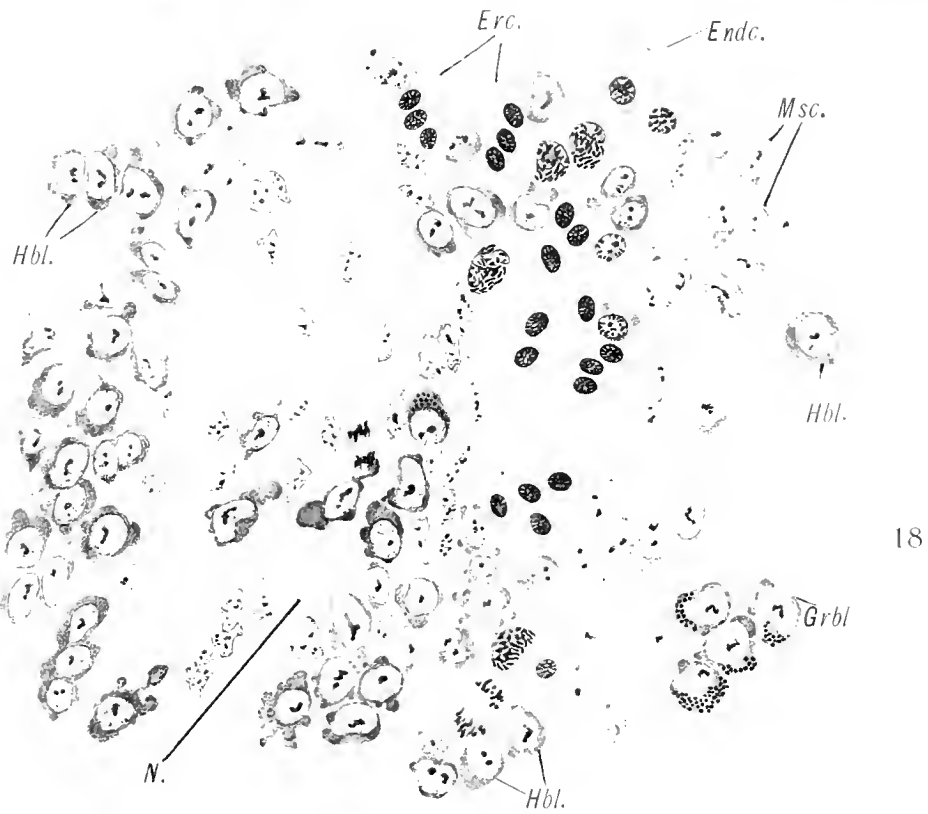
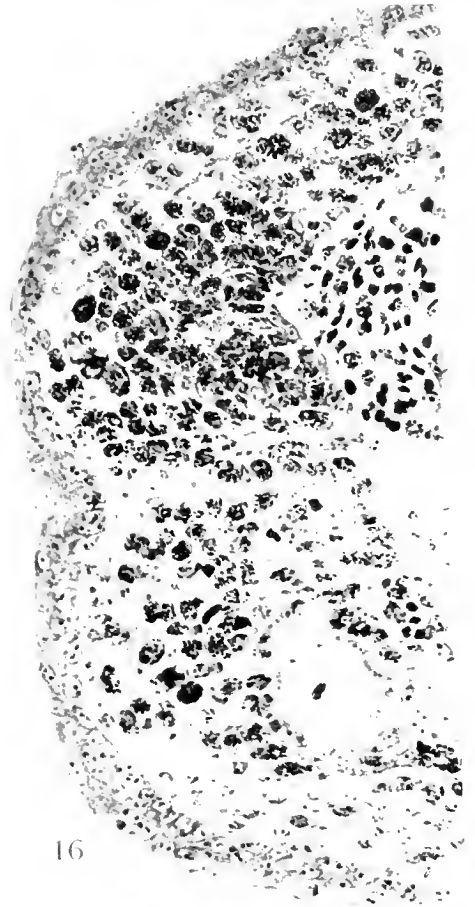
14



15









CONTRIBUTIONS TO EMBRYOLOGY, No. 50.

STUDIES ON THE LONGITUDINAL MUSCLE OF THE HUMAN COLON,  
WITH SPECIAL REFERENCE TO THE DEVELOPMENT  
OF THE TAENIAE.

By PAUL E. LINEBACK,  
*School of Medicine, Emory University, Georgia.*

Eight text-figures.



# STUDIES ON THE LONGITUDINAL MUSCLE OF THE HUMAN COLON, WITH SPECIAL REFERENCE TO THE DEVELOPMENT OF THE TAENIAE.

BY PAUL E. LINEBACK.

The presence and arrangement of tæniæ in the colon of some domestic animals, as well as of man, are striking and distinctive. The relationship between these bands and nutritional habits (*i. e.*, kind of food eaten, manner in which it is taken and utilized, and type of feces discharged) attracts more than passing notice. For example, the horse and the cow eat the same kind of food; presuming that it goes into the cæcum in the same state in both animals, the horse passes it through a colon having four tæniæ, while the cow passes it through a colon having none, and the type of feces discharged by one is entirely different from that discharged by the other. Man and pig are omnivorous animals, having a broader range of food supply than any other types. Both will take and utilize animal and vegetable food, cooked or raw, and the types of feces are very similar; but the structure of the colon and the arrangement of the tæniæ are quite different in the two species. The pig is supplied with only two bands in a long, double, spiral colon, whereas in man there are three bands in a rather simple loop of large bowel.

A further study of this relationship between the tæniæ and the nature of the bowel-content might be carried on with interest. Especially would the physiological aspect of both the tæniæ and the sacculations bear further investigation. But back of these peculiar phenomena with their physiological aspects is the problem of the production of tæniæ, their origin, development, and nature. Since the human colon as a whole is more simple and primitive, ontogenetically, than the colon of domestic animals, a study of the tæniæ here would seem to offer fewer difficulties and promise some definite results. At a meeting of the Anatomical Association in New Haven (1915), and again in New York (1916), I gave reports of work done on the colon and tæniæ of the pig; and in 1916 I published in the *American Journal of Anatomy* (vol. 20, p. 483) an article on the development of the pig's colon. This paper is a report of further studies based upon these subjects, together with work done on the human colon.

## LITERATURE.

The literature does not offer much in the way of setting forth the origin and development of the tæniæ. Such references as are found, with a few exceptions, are mainly only a mention of the bands when the wall of the colon is discussed. Thus they are cited by Meckel (1817), Kölliker (1854), Barth (1866), and Brand (1877); but in 1882 Baginsky made a brief statement concerning them which has a definite embryological bearing. In *Archiv für pathologische Anatomie* (vol. 89, p. 90) he wrote:

“Während die äussere Muskelschicht nur eine dünne Lage darbietet, die an 3 Stellen einer dichten Anhäufung von Muskelfasern Platz macht. So ist schon deutlich die Anlage der Tæniæ des Colon markirt.”

Following this, other citations are found, but only of a general nature, such as those made by Oppel (1897), Maurer (1902), Ellenberger and Baum (1909), and Nagy (1911-12). Then Broman (1911) gave a more detailed account of the growth of the tæniæ. His statement is longer than Baginsky's and bears the added feature of setting forth the human tæniæ, while Baginsky dealt only with the lower animals. Broman's account in his Handbook (p. 352) is as follows:

“Bis zur Geburt bleibt gewöhnlich auch im Colon die Längsmuskelschicht ringsum kontinuierlich. Bei der im extrauterinen Leben folgenden stärkeren Ausdehnung des Colon wird aber diese Muskelschicht in drei parallelen Muskelbündeln zersplittert, die durch immer grösser werdende Zwischenräume von einander getrennt werden. Die werdende Lage dieser Langmuskelbündel wird schon im vierten Embryonalmonat durch gefässhaltige Mesenchymverdickungen markiert.”

More recent citations are made by F. T. Lewis (1912), F. P. Johnson (1913), and Sisson (1914). Sisson dealt with the tæniæ in domestic animals only, and Johnson merely referred to them in his study of the mucosa of the human intestine. Lewis, however, has set forth their appearance very definitely. His account is found in *Human Embryology* (Keibel and Mall, vol. 2, p. 396), in which he states:

“At 42 mm. it (the circular muscle) is found throughout the colon. The longitudinal layer appears as a crescentic condensation along the mesenteric attachment of the transverse colon at 75 mm. In the transverse colon at 99 mm. the mesenteric tæniæ is still the most prominent part of the longitudinal muscle, but the other two tæniæ are indicated. There is probably a thin layer of longitudinal muscle in the intervals between the tæniæ.”

#### MATERIAL AND METHODS.

This study was confined essentially to the human colon and the results are applicable chiefly to this type. But in order to study as closely as possible some of the minute changes and variations attending early growth, especially the appearance of the longitudinal fibers, embryos of different animals were utilized. The most useful of these was found to be the pig, since an abundance of this material was at hand, and it was thus possible to collect a closely graded series and to vary its preparation. The best staining results were obtained by using Mallory's phosphomolybdic-acid preparation, which differentiated the muscle fibers with a good degree of definiteness. Human fetuses of the following stages of development were studied: 33 mm., 40 mm., 50 mm., 70 mm., 90 mm., 105 mm., 110 mm., 120 mm., 125 mm., 145 mm., 160 mm., 180 mm., 185 mm., 190 mm., 200 mm., and new-born. Several of the smallest were prepared whole, and from the others the colon was carefully removed and two sections, 6 and 8 mm. long respectively, were taken from the two ends (caecal and rectal). Three sections were taken from the older specimens, one each from the ascending, transverse, and descending portions. All were sectioned serially and stained by the Mallory method. In addition, the following series from the collection at the Carnegie Laboratory of Embryology, Baltimore, was also carefully studied, and these specimens will be referred to herein as C. C. (Carnegie Collection).

The entire collection was placed at my disposal through the generosity of Professor Streeter, and I wish at this time to express my sincerest gratitude to him for this great kindness. I wish also to express my indebtedness to Professor F. T. Lewis and Professor R. R. Bensley for encouragement and material aid, and to recall the delightful associations of their laboratories.

Some experimentation was done on the cæcum of the guinea-pig, as this is a relatively large structure with an especially well-developed group of tænia. A number of skiagrams were examined and a few fluoroscopic inspections were made of the human colon in the living state.

No.	mm.	No.	mm.	No.	mm.
782	26	1358	32	362	39
1199	26	210	35	886	43
756	27	1591	36	96	50
75	30	1318	37	538	50
86	30	922	37	418	52
115	32	1161	37		

#### DISCUSSION.

The production of tænia may be divided into two phases, each dependent upon separate factors and attended by different phenomena: an early growth phase, characterized by the appearance of the bands and their growth up to a fixed state, and a functional phase, wherein the tænia are accentuated and become especially distinct through the functioning of the sacculations.

The growth phase may be introduced by a brief consideration of the circular muscle. The study of a closely graded series of embryos reveals the circular muscle appearing much earlier than the longitudinal. This is true in the small intestine as well as in the large. It is also found that the muscle is first seen in the caudal end of the intestine, and that it can subsequently be traced throughout the entire length of the latter. Lewis states that "at 42 mm. it is found throughout the colon," with which my findings agree, although I should conclude that it reaches that state of completeness somewhat earlier. Fetus No. 75 C. C., 30 mm. (fig. 1), shows it only in the pelvic portion of the intestine; while in a 35-mm. specimen, No. 210 C. C., it can be seen throughout the entire length of the intestine. Evidently, its growth is upward from the caudal end of the tube and is quite rapid. These items are significant, in that they show that in its manner of growth the circular muscle exactly precedes the longitudinal, both in time of appearance and time of completion.

The zone just outside of the circular muscle is occupied by the myenteric plexus, capillaries, and embryonic cells. The plexus occupies almost the entire zone and is contained in rather poorly defined rounded and oval compartments, which become very distinct by the 50-mm. stage. It is on the outside of these, and in the angles between them, that the longitudinal muscle-fibers will make their

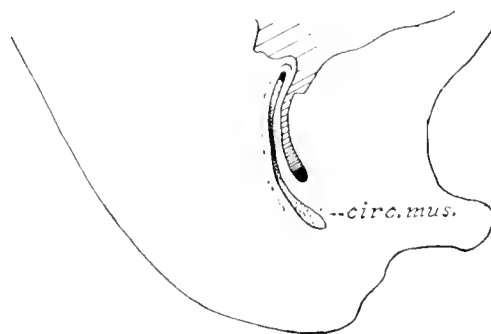


FIG. 1.—Sagittal section of a human embryo 30 mm. C. R. length (No. 75, Carnegie Collection), showing the circular muscle-fibers in the pelvic portion of the colon. No longitudinal fibers are present.

appearance. In the younger stages, just following the formation of the circular muscle, these aggregations of nerves may be wrongly interpreted as the cut ends of the longitudinal fibers; but proper staining and careful study will reveal their true identity.

The investigation proceeded with the aim of noting the first muscle-fibers which could be unquestionably identified as such, and these were not found earlier than the 40-mm. stage. In a fetus of this size they are seen in the lower end of the intestine. In the extreme caudal end, near the anal canal, a complete layer, quite thin but well defined, completely surrounds the tube. Johnson has shown how they intermingle with the internal sphincter and levator ani muscles in older fetuses, a condition which is seen as early as this 40-mm. stage. A 46-mm. fetus, No. 95 C. C. (fig. 2), shows the whole muscle grown a little farther upward and its dorsal fibers

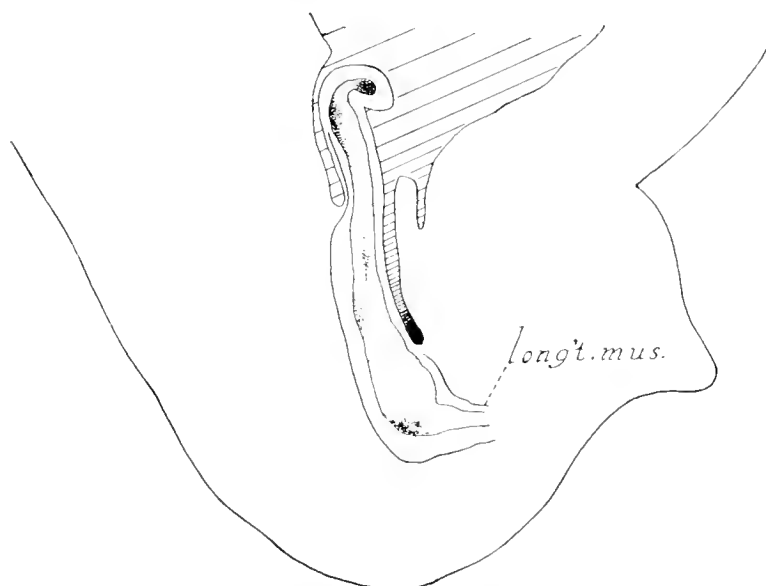


FIG. 2.—Sagittal section of a human fetus 46 mm. C.R. length (No. 95, Carnegie Collection), showing the presence of longitudinal muscle-fibers (the circular muscle is not drawn). The ventral portion of the muscle extends only as far as the pelvic cavity, while the dorsal fibers extend well into the abdominal region.

extending well into the sigmoid region; no well-defined fibers can be detected in any of the regions higher up. In a 50-mm. fetus there is a distinct layer at the mesenteric attachment, the continuation of the dorsal fibers of the 46-mm. stage. The layer is well defined and extends throughout the length of the colon. Lewis noted this muscle and stated that in a 75-mm. fetus it was seen along the transverse colon, although he made no mention of it in other parts of the bowel.

Thus it is seen that the longitudinal fibers, as well as the circular, have their origin in the extreme caudal end of the intestine and grow rapidly upward toward the caecal end. In the pelvis the muscle forms a continuous layer surrounding the tube, but as the more open region of the sigmoid is reached it extends only along the line of the mesentery attachment. Here it lies just over the plexus of nerves in a crescentic shape with its horns directed laterally. The remainder of the circle outside of the plexus is a zone of quite uniform thickness, where there are found cells generally of an indefinite type; some are fibrous and resemble the cut ends of the longitudinal muscle, but do not react as such to the Mallory stain. In a 52-mm.



fetus, No. 448 C. C. (figs. 3 and 4), this remaining portion is occupied by definitely formed muscle-fibers which are, however, loosely scattered in the zone, whereas those at the mesenteric arc are compact. This may cause the erroneous conclusion that the mesenteric arc is the only part of the muscle present at this stage, but a careful search reveals the scattered fibers as just mentioned. This state of the muscle continues unaltered for some time, no marked changes being noted until near the 90-mm. stage. At this time the entire circle of fibers becomes compact, with the mesenteric portion still prominent (fig. 5). This harmonizes with what Lewis stated concerning the arc, and also with Broman's statement about a continuous layer.

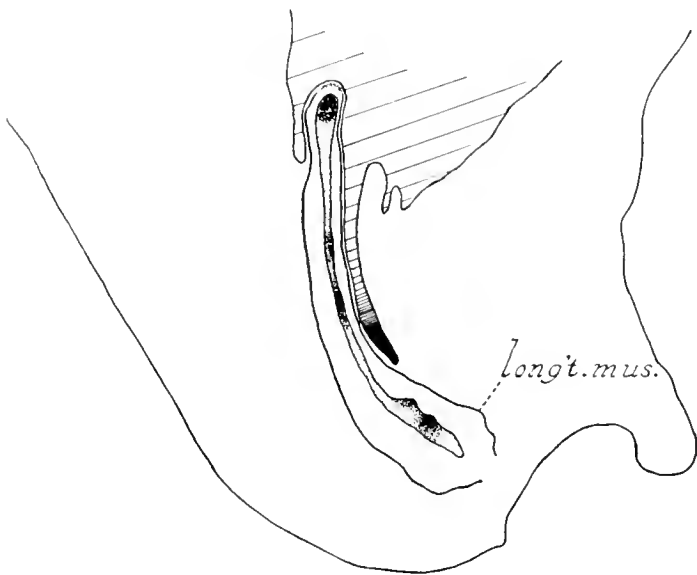


FIG. 3.—Sagittal section of a human fetus 52 mm. C.R. length (No. 448, Carnegie Collection), showing both dorsal and ventral portions of the muscle extending into the abdominal region.

The important development up to the 90-mm. stage is the appearance of the longitudinal muscle in the rectum, where it is a complete layer entirely surrounding the tube. By rapid growth it extends to the caecal end, first along the line of the mesenteric attachment, then (closely following this) the rest of the circle becomes occupied by muscle-fibers which are at first loosely scattered but soon become condensed into a well-defined layer. The condition in the pig is quite similar with the exception of a few minor differences. Shortly after the muscle appears in the pelvis it is also seen in the caecal end with apparently no muscle in the bowel between these regions. Growth then proceeds from both ends and, as in the human intestine, the muscle rapidly fills the entire length of the colon. Another peculiarity is that the two bands in the pig's colon have a striking position. Although the mesenteric arc is the first part of the muscle to develop, it does not grow into a tænia; but when the muscle entirely surrounds the tube, as in the human colon, two lateral thickenings appear, one on each side of the bowel equidistant from the mesentery, which become true tæniæ (fig. 7). In the caecum, however, which is much longer than in man, a third tænia is present. It extends from the ilio-caecal junction to the tip of the caecum along the line of the meso-caecal attachment, corre-

sponding to the mesenteric tæniæ in man. The other two tæniæ continue their lateral position also to the tip of the cæcum.

The problem of the tæniæ has been thus far suggested only by way of citing the mesenteric thickening and its relationship to the rest of the muscle. Lewis referred to this as the *mesenteric tæniæ* and stated that "at 99 mm. it is still the most prominent part of the longitudinal muscle"; and further, that "the other two tæniæ are indicated." Broman stated that in the fourth month the primordia of the longitudinal muscle bundles are marked. One feels that both of these statements are incomplete, since one does not make it clear where or by what the tæniæ

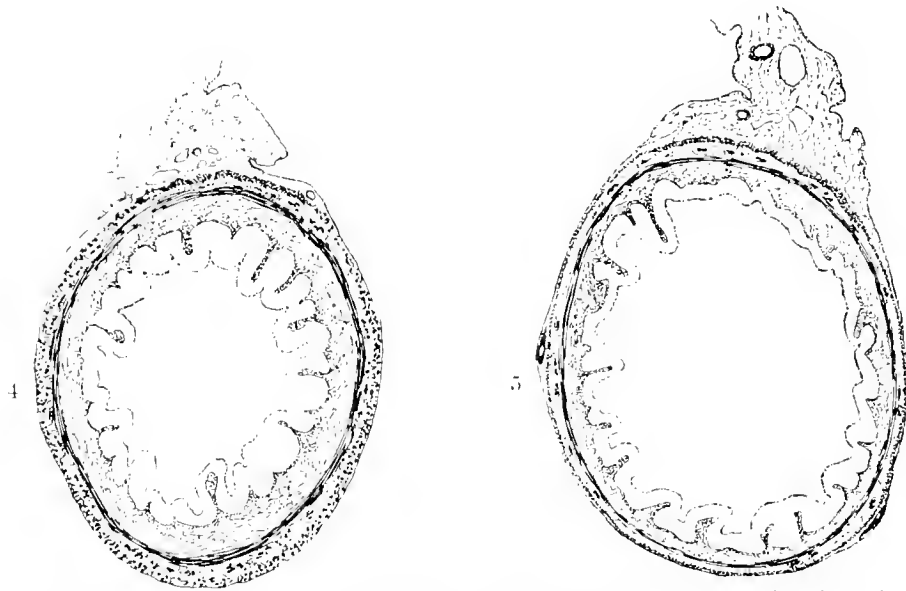


FIG. 4.—Cross-section of the colon of a human fetus 52 mm. CR. length, showing a well-defined tæniæ at the mesenteric arc, with a complete layer of loosely scattered fibers surrounding the tube.

FIG. 5.—Cross-section of a human fetus 90 mm. CR. length, showing the fibers of the longitudinal muscle, loosely scattered in the 52-mm. stage, now compact, and only the mesenteric tæniæ present. Two enlargements are seen, one on each side of the tube, caused by the presence of blood-vessels. It will be noted that the muscle here is in no way involved.

are indicated, and the other (that they are marked by "mesenchymal thickenings") is wide of the point. Thickenings are found scattered along at irregular intervals; these, upon cross-section, might be taken to indicate the developing tæniæ, but they do not involve the muscle in any way. Indeed, when the tæniæ appear they are quite distinct from these thickenings, which in reality are caused by large blood-vessels (fig. 5).

At about 100 mm. there appear at two places in the muscle an accumulation of fibers which cause a marked thickening in the layer (fig. 6). These masses are crescentic in shape, resembling the mesenteric thickening, are located about equidistant from it and from each other, and extend the whole length of the bowel. They are accumulations of muscle-fibers within the layer at these two places and continue to enlarge until the 105-mm. stage, when they are distinctly formed and fixed in their triangular position. When traced for some distance along the bowel they are seen to vary in size and shape; at places they are broad and flat or narrow

and thick, but are not effaced by subsequent growth in the general intestinal wall. They are actually permanent accumulations of muscle-fibers and not temporary migrations of fibers from the adjacent interspaces, since these spaces are entirely unaffected by them. This is somewhat at variance with Broman, who speaks of a splitting of the muscle by dilatation of the intestine which produces the three parallel bands. One may only conjecture what he considers produces the dilatation. That it is a filling of the intestine with meconium is a reasonable deduction, but the formation of the tæniæ could hardly be explained on this basis. Meconium accumulates first in the rectum. In a 125-mm. fetus it fills the tube to distension only as far as the beginning of the sigmoid, but the tæniæ are distinctly formed as early as

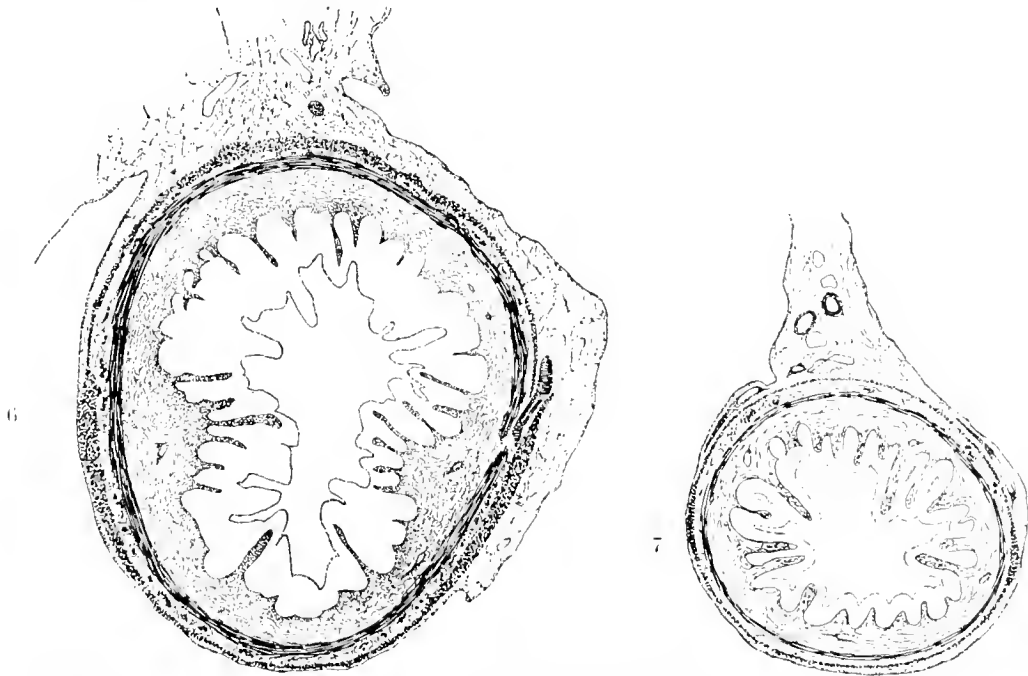


FIG. 6.—Cross-section of the ascending colon of a human fetus 105 mm. CR. length, showing the three tæniæ in a triangular position in the wall. Note their broad, flat shape and the presence of longitudinal fibers in the intervals.

FIG. 7.—Cross-section of a 200-mm. pig fetus, showing lateral position of the two tæniæ. Note blood-vessels passing just beneath the peritoneal layer to the vicinity of the bands.

the 105-mm. stage and in a region where no trace of meconium is found. Furthermore, in this rectal region, where there is marked distension with distinct tæniæ, the interspaces are unbroken. In the new-born, distension with meconium may be found as high up as the cæcal region, but the ring of longitudinal fibers remains unbroken; hence a splitting process can hardly be considered. From his statement that "there is probably a thin layer of longitudinal muscle in the interval between the tæniæ," it may be concluded that Lewis holds that the tæniæ are present first, and that later the interspaces are filled in by extension from the edges of adjacent bands; but from a careful study of young series up to the 100-mm. stage I am led to believe that the muscle is first present as a continuous layer, probably having grown laterally from the horns of the mesenteric crescent—the first band—and that the other two tæniæ develop within the layer as aggregations of muscle-fibers.

The development thus far attained is fundamental, remaining unchanged in its essential features throughout subsequent variations in size, shape, and relationship of the colon. Changes may be noted in its form, as when contractions of the circular muscle produce saccules, or in its position and relationship, as when markedly filled by meconium; but the bands never lose their identity, nor do the intervals become entirely obliterated. In a region of the bowel where there is marked distension and the wall is smoothed out the tæniæ remain distinct, and over the domes of the saccules there may be found a very thin layer of longitudinal fibers. It is generally stated that the tæniæ become confluent in the lower end of the bowel, but cross-sections show that the three bands are still present as thickenings in the wall, distinctly separated from each other, although sacculations are absent.

The second phase of tæniæ formation is ushered in by a factor which begins about the 150-mm. stage—*i. e.*, the appearance of sacculations, the effect of which upon the tæniæ is significant. Their formation and effect were studied experimentally in the guinea-pig; investigations were also made of skiagrams of the human colon and a few direct inspections in life, through the fluoroscope. By these methods it was directly observed that the pouches are produced by the sharp contraction of narrow groups of circular muscle-fibers extending between adjacent tæniæ. Apparently the circular muscle is more or less firmly attached by inter-muscular connective tissue to the longitudinal bands, which fact permits it to contract segmentally. The fluoroscopic inspections and the experiments on the cæcum of the guinea-pig showed waves of contraction passing down the bowel in three rows, between the three tæniæ, which constantly changed its surface contour from a series of saccules to a series of clefts. The degree of contraction varied from a slight indentation of the saccule to its entire obliteration.

A marked feature noted was that the contraction waves were independent of each other; only rarely were two groups of fibers on opposite sides of tæniæ in contraction at the same time. Most commonly a contracting segment was opposed by a saccule; thus the three rows of saccules are also independent of each other (fig. 8). The saccules are in no way related to the bowel-content, as evidenced by the fact that they appear as early as the 150-mm. stage in a region of the colon where there is no meconium, and that where meconium is causing the distension the saccules are absent. For the production of both tæniæ and saccules it is evidently necessary to seek further than meconium distension or stimulation caused by it. A basis for such a study might be found in the peculiar position of the pig's tæniæ and their relationship to the mesenteric structures, nerves, blood-vessels, and lymphatics.

Recalling the position of the two tæniæ, one on each side of the bowel with none at the mesenteric attachment, it is interesting to note that, instead of the mesenteric structures entering the intestinal wall at the mesenteric line, the majority of them

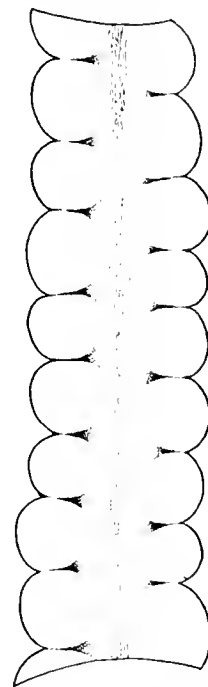


FIG. 8.—Semi-diagrammatic figure of colon of a new-born infant, showing alternate arrangement of saccules on opposite sides of a tænia.

pass just beneath the serous layer, around to the vicinity of the bands, before penetrating deeper (fig. 7). Usually, on the mesenteric side of each tænia and very close to it, there can be seen numerous branches of the nerves and blood-vessels passing in and out. If the proposition of an active growth for the production of tæniæ be tenable, then, instead of a passive adjustment by a splitting process, it is essential to look for some causative factor back of this growth. The breaking up of mesenteric vessels into capillary plexuses in the region where the bands will later develop is fundamental. Numerous instances of this phenomenon were noted, but such a line of investigation requires further and more careful attention.

The effect of these segmental contractions is to accentuate the tæniæ, causing them to stand out in marked distinctness, especially when the contractions are most active (fig. 8). Previous to the appearance of the contractions the tæniæ are poorly outlined to the unaided eye, but by their action the bands become sharply defined. This condition is noted in the adult as well as in the fetus. There are portions of the adult colon, when directly examined, in which there seem to be no tæniæ and the content of which appears to have no effect upon this state of the wall; but where contractions and saccules are in an active state the tæniæ are marked.

In the consideration of this fundamental factor in tæniæ production another aspect of the bands proper presents itself—that of an added function. In addition to holding the colon in position and shortening it, the bands functionate as fixed and firm longitudinal cables between which the circular muscle-fibers are stretched and against which they may pull in segmental contraction. When one considers the more solid content of the colon, with its retarded progress and the necessity of more force in moving it, some such adjustment for only partial circular-muscle contraction would seem logical. This can be accomplished only by the development of strong, fixed, longitudinal bands, against which the segments of the circular muscle may pull. By such an adjustment there are three rows of counteracting segments which, working alternately, tend to gradually move the massive content along without violence to the wall.

#### SUMMARY.

An attempt has been made to give a more detailed account of the appearance, development, and nature of the tæniæ than is found in the literature. In so doing a few features are noted in addition to and at variance with accounts already given.

1. The longitudinal muscle begins its growth in the caudal end of the intestine and rapidly extends to the caecal end; first, as a layer at the mesenteric attachment, followed shortly by the whole circle of the tube becoming incased in a complete layer of longitudinal muscle-fibers before tæniæ are formed.

2. The mesenteric thickening becomes the first tænia, and the other two are developed in the already existing layer of muscle.

3. The production of tæniæ, especially of the adult state, is due to an added factor, the segmental contraction of the circular muscle between the bands. These contractions are in turn dependent upon the tæniæ, which functionate as cables against which the circular muscle may pull.

4. The whole aspect of tæniæ production is based on active growth and functional factors rather than being the passive results of foreign elements.

## BIBLIOGRAPHY.

- BAGINSKY, A., 1882. Untersuchungen über den Darmkanals des menschlichen Kindes. *Arch. f. path. Anat.*, Bd. 89, p. 64-94.
- BARTH, 1868. Beitrag zur Entwicklung der Darmwand. *Sitzb. der Akad. der Wiss., Wien*, Bd. 58, p. 129-136.
- BRAND, EMI, 1877. Beitrag zur Entwicklung der Magen- und Darmwand. *Verhandl. d. phys.-med. Gesellsch.*, n. F. 11, p. 243-255.
- BROMAN, IVAR, 1911. Normale und abnorme Entwicklung des Menschen. Wiesbaden.
- ELLENBERGER, W., and H. BAUM, 1909. Systematische und topographische Anatomie des Hundes. Berlin, 12th ed.
- JOHNSON, F. P., 1913. The development of the mucous membrane of the large intestine and vermiform process in the human embryo. *Amer. Jour. Anat.*, vol. 14, p. 187-226.
- KÖLLIKER, A., 1854. *Mikroskopische Anatomie*, vol. 2<sup>1</sup>, Leipzig.
- LEWIS, F. T., 1912. The development of the large intestine. *Manual of Human Embryology* (Keibel and Mall), vol. 2, p. 393-403.
- MAURER, F., 1902. Die Entwicklung des Darmsystems. *Hertwig's Handbuch der vergl. u. exp. Entwicklungslehr.*, Bd. 2, Teil 1, p. 109-252.
- MECKEL, J. F., 1817. *Bildungsgeschichte des Darmkanals der Säugethiere und namentlich des Menschen*. *Deutsches Arch. f. Physiol.*, Bd. 3, p. 1-84.
- V. NAZY, LADISLAUS, 1912. Ueber die Histogenese des Darmkanals bei menschlichen Embryonen. *Anat. Anz.*, vol. 40, p. 147-156.
- OPPEL, A., 1897. *Lehrbuch der vergleichenden mikroskopischen Anatomie*, Bd. 2.
- SISSON, SEPTIMUS, 1914. *The anatomy of domestic animals*; 2nd ed., Philadelphia.

CONTRIBUTIONS TO EMBRYOLOGY, No. 51.

EXPERIMENTAL STUDIES ON FETAL ABSORPTION.

- I. THE VITALLY STAINED FETUS.
- II. THE BEHAVIOR OF THE FETAL MEMBRANES AND PLACENTA OF THE CAT TOWARD COLLOIDAL DYES INJECTED INTO THE MATERNAL BLOOD-STREAM.

By GEORGE B. WISLOCKI,

*Arthur Tracy Cabot Fellow, Laboratory of Surgical Research, Harvard Medical School.*

With four plates and one text figure.





# EXPERIMENTAL STUDIES ON FETAL ABSORPTION.

By GEORGE B. WISLOCKI.

## I. THE VITALLY STAINED FETUS.

Colloidal dyes and particulate matter introduced into the blood-stream of pregnant animals fail to reach the fetus. The placenta appears to be an impenetrable barrier for inert colloids, and experiments show that even colloidal metabolites reach the fetus only after they have been split into simpler substances by enzyme action, hydrolysis, and other chemical processes. Goldmann (1909, 1912) noticed that when he injected colloidal dyes (particularly trypan-blue and pyrrhol-blue) into pregnant mice and rats the placenta and the fetal membranes stained very deeply with the coloring matter, but none of it reached the fetuses.

Because colloidal dyes have been of such great value in the study of problems of absorption and phagocytosis in the adult animal it has been a cause for regret that there has existed no simple means of applying these substances to the study of similar processes in the fetus. The writer (1916) first observed that amphibian larvæ could be vitally stained by immersing them in dilute solutions of colloidal dyes and his experiments led to further interesting observations by McClure (1918) and Clark (1918). The staining of fetuses appeared more difficult since it had been shown that injecting the dyes into the maternal blood stream was fruitless as a means of staining the embryo. The technical difficulties accompanying direct introduction of the dyes into the fetal circulation are numerous, and in such procedures physiological conditions can not be maintained. It was therefore gratifying to observe that by injecting colloidal substances into the amniotic cavity they could be introduced into the fetus with perfect ease and under physiologically normal conditions. The present study concerns the results of injecting colloidal dyes and other substances into the amniotic sacs of guinea-pigs. A few observations of the same sort upon fetal cats are also described. The observations upon cats, although incomplete, are deemed important because they confirm some of those upon the guinea-pig and therefore the final deductions assume a broader significance.

Sterile operative technique was used in the experiments. The pregnant animal was anesthetized and a mid-line laparotomy was done. One horn of the pregnant uterus was brought into view through the incision. After palpating a fetus through the uterine wall, it was grasped between thumb and index finger of the operator. If the fetus was so young that the amniotic cavity was completely distended with fluid, a replacement injection was performed. The technique of replacement injections is described by Weed (1917). As applied to this study, it consists of inserting two 24-gage needles, connected with balanced reservoirs, directly through the uterine wall into opposite poles of the amniotic cavity and permitting the injection fluid to enter by one needle, while the amniotic fluid escapes through the other. In older fetuses, where the amniotic sac is incompletely distended with fluid,

direct injections were made by means of a syringe. For purposes of vital staining 1 to 5 c. c. (depending on the age of the fetus) of a 1 per cent trypan-blue solution was injected. After completing the injection the uterus was replaced in the abdomen and the incision closed. Recovery of the animals was uneventful.

#### OBSERVATIONS UPON FETAL GUINEA-PIGS.

The guinea-pig fetuses used in these experiments ranged from 30 mm. to full-term. The technique was found impracticable for younger stages. The pregnant animals, injected as described above, were sacrificed at intervals varying from a few minutes up to several days, and the tissues fixed in 10 per cent formalin.

Diffusion of trypan-blue from the amniotic cavity of the guinea-pig becomes apparent a few minutes after injection. The fetal membranes turn a uniform dark blue (fig. 1) and within an hour the dye can be demonstrated in the fetal blood-serum by the filter-paper test. The fetus itself assumes a slaty-blue color which gradually deepens (fig. 2) and the placenta becomes a brilliant blue (fig. 1). The stain ceases at a definite line of demarcation between the placental labyrinth and decidua serotina. The uterine wall everywhere about the fetus remains unstained.

Trypan-blue can not be detected in the maternal circulation, liver, kidneys, or urine, where one would expect to find it in case it escaped, even in traces, from fetus to mother. In a series of nearly full-term fetuses much larger quantities of trypan-blue were injected into the amniotic cavities in order to determine whether the presence of a sufficiently large quantity of dye would cause it to appear in the maternal circulation. In no instance, however, could the dye be detected in the mother. In one animal 30 c. c. of trypan-blue was injected into the amniotic sacs without any of it finding its way into the maternal tissues. It seems reasonable to believe, therefore, that inert colloidal substances can not pass from fetus to mother. From this description it is evident that trypan-blue is rapidly absorbed from the amniotic cavity, enters the fetal circulation, and vitally stains the fetus and placenta.

Clinicians and veterinarians state that in many animals, and perhaps in man, during the latter part of pregnancy the amniotic fluid normally diminishes. Authorities for this belief are: Kehrer (1867), who made his observations on rabbits; Döderlein (1890), on the calf; Preyer (1895), on the avian egg; Frank (1901), on ruminants; and Jacqué (1903-4), on sheep. Since the amniotic fluid is believed to be partially absorbed during the latter half of pregnancy, curiosity is aroused as to the pathway of absorption. The observations of Zweifel (1875), Ahlfeld (1885), Zuntz (1885), Döderlein (1890), Preyer (1895), and others, who found lanugo hairs, amniotic epithelial cells, and bits of hoof and nail in the stomach and intestines of older fetuses, show clearly that the amniotic fluid may be swallowed by the fetus. These observations appeared to afford such a complete explanation of the partial disappearance of the amniotic fluid that little consideration was given to other possible paths of absorption. One can readily conceive of a number of possible modes of absorption of fluid from the amniotic sac: (1) passage into the gastrointestinal tract by movements of deglutition; (2) passage into the respiratory tract by movements of inspiration; (3) absorption through the epidermis of the fetus;

(4) diffusion through the amniotic membrane and umbilical cord. It will be of interest to see what light our experiments upon fetal guinea-pig fetuses shed upon these possibilities.

*Absorption of fluid from the amniotic sac by passage into the gastro-intestinal tract.*—The passage of fluid into the fetal stomach in the latter half of pregnancy can be demonstrated experimentally in animals by injecting a small quantity of any soluble dye into the amniotic cavity. Of 15 guinea-pig fetuses so injected, 11 showed heavy traces of coloring matter in the stomach one hour later. After a somewhat longer interval the dye appeared in the intestines. It is fair to assume that substances in true solution may enter the fetal circulation in this way. Trypan-blue probably does not, since it is in colloidal solution, and we know that in post-natal life colloidal dyes are not absorbed by the mucosa of the gastro-intestinal tract.

*Absorption of fluid from the amniotic sac by passage into the respiratory tract.*—No exact observations upon the respiratory movements of the fetus exist, but everyone who has worked upon pregnant animals is aware that movements resembling respiration occur during the latter part of pregnancy. By injecting a colored solution into the amniotic sac it can be demonstrated that amniotic fluid is aspirated into the trachea and lungs. In such experiments the lungs at once become deeply stained. This phenomenon is prettily shown by performing a replacement injection of a 1 per cent solution of potassium ferrocyanide and iron ammonium citrate and after 30 minutes immersing the fetus in acid formalin. Prussian blue is precipitated in the lungs (fig. 3). From these experiments the absorption of small quantities of amniotic fluid through the lower respiratory tract is demonstrated. The failure of previous investigators to describe lanugo hairs, etc., in the respiratory passages does not militate against such a conclusion, since the epiglottis might readily prevent gross material from entering the lungs.

*Absorption of fluid from the amniotic sac through the epidermis.*—Absorption in this manner does not appear to have occurred in any of the animals injected in these experiments. Whenever trypan-blue was injected into the amniotic sac the amnion and umbilical cord stained very quickly, but the color stopped abruptly at the junction of umbilical epithelium and the skin at the umbilical ring. The skin of the fetuses, at first uncolored, gradually turned blue as the dye accumulated in the fetal circulation. To determine more exactly that solutions are not absorbed through the fetal skin, in one series of animals potassium ferrocyanide and iron ammonium citrate were injected into the amniotic sac. In no instance could precipitated Prussian blue be discovered in the epidermis after such injections. The experiments afford definite proof that passage of fluid into the fetus by this route does not occur.

*Diffusion of fluid from the amniotic sac through the amniotic membrane.*—If dye-stuffs are injected into the amniotic sac, the fetal membranes and umbilical cord are quickly stained. That this is probably a diffusion phenomenon and resembles transudation, as seen elsewhere in the body (*e. g.*, in the peritoneal cavity), can be demonstrated by means of the Prussian-blue reaction. In 3 experiments a 1 per

cent solution of iron ammonium citrate and potassium ferrocyanide was injected into the amniotic sacs of several fetuses. The membranes were fixed in acid formalin at intervals varying from 5 minutes to an hour. Evidence of the diffusion of the injected fluid was gained by finding Prussian-blue precipitate in the membranes. Very soon after the injection this precipitate was found in the amniotic epithelial cells, as well as between them. It also appeared, after a longer interval, in the subepithelial mesoderm. This demonstrates the gradual penetration of the amniotic membrane by the injected solution.

To summarize these observations, it may be stated that during the latter part of pregnancy there are three pathways of absorption from the amniotic sac. The chief of these appears to be direct transudation through the amniotic membrane. The other two routes are through the fetal stomach and respiratory tract.

After noting the passage of vital stains and true solutions through the amniotic membrane, it was of interest to determine the further course which they pursue in entering the fetal circulation. This course is necessarily determined for each animal species by the relationship of the amniotic membrane to the chorion, allantois, and yolk-sac. The guinea-pig is very similar in development to the mouse, which has been carefully described by Sobotta. The striking feature in both is that amnion and embryo develop within the blastodermic vesicle instead of upon its surface, as in other mammalia. Furthermore, the yolk-sac surrounds the internal cell-mass and amnion; subsequently, the wall of the blastodermic vesicle and the outer layer of the yolk-sac atrophy, leaving the fetus with a layer of endodermal cells—the inverted yolk-sac—as its outermost covering. This endodermal membrane persists throughout fetal life, becomes richly vascularized by the omphalo-mesenteric vessels, and develops numerous villi whose cells are markedly phagocytic and probably play a large part in the absorption of the embryotrophe and in the nutrition of the fetus (Goldmann). Due to the obliteration of the extra-embryonic coelom, the amnion, early in fetal life, becomes loosely adherent to this membrane by strands of mesoderm. As a result, the amnion is brought into intimate contact with the omphalo-mesenteric vessel (figs. 1 and 2). It can be demonstrated that these blood-vessels are partly responsible for the absorption of solutions from the amnion. To do this, a solution of iron ammonium citrate and potassium ferrocyanide is injected into the amniotic sac. One hour later the membranes of the fetus are fixed in acid formalin and the omphalo-mesenteric vessels are examined under the microscope. Precipitated Prussian blue is encountered outside as well as inside the vessels (fig. 6).

We now pass to a description of the fetus in the second phase of vital staining, namely, the appearance of the vital dye in the form of granules in groups of cells, collectively called *macrophages*. As we have described, trypan-blue passes from the amniotic cavity into the circulation of the fetus. After 24 to 72 hours it appears in the form of characteristic granules in many of the fetal tissues. It must be pointed out that this vital staining is not comparable to that obtained after repeated injection in the adult. As is well known, the several tissues of the adult animal do not stain equally rapidly or heavily, and after a single injection one may fail

to find any stain at all in the adrenals, testes, etc. We are aware that the staining in these fetuses does not represent the extent to which it would occur if repeated introduction of the dye were made. Such a procedure is technically impossible.

The appearance of the vitally stained fetus in sagittal section is of interest (fig. 4). It is seen at a glance that the central nervous system remains unstained. This behavior is identical with that in postnatal life. The physical conditions which prevent the passage of foreign colloidal material from the blood-stream into the central nervous system appear to be established relatively early in intrauterine life. The cells within the fetus which have been observed to store trypan-blue granules may be conveniently described under three headings: (1) endothelial cells, (2) connective-tissue cells, and (3) epithelial cells. The storage of the dye in the fetal membranes and placenta will be described separately.

*Endothelial cells.*—The only endothelial cells of a fetus 30 to 40 mm. in length which have been noted to absorb trypan-blue under the conditions described, are those lining the sinusoid spaces of the liver. Characteristic blue granules are always abundantly present within the cytoplasm of these cells.

*Connective-tissue cells.*—Large, round cells, with a single round or oval nucleus, whose cytoplasm contains granules of vital dye, are occasionally encountered in the connective tissue. It is noted that, as in the adult, the elastic tissue of the fetal arteries exhibits an affinity for the dyes.

*Epithelial cells.*—The kidneys of a fetus 30 to 40 mm. in length are striking because of the large quantity of dye invariably found within the epithelial cells of the convoluted tubules (fig. 7). The dye is most abundant in the proximal portion of the tubules, scant in the distal portion, and entirely absent in the collecting tubules. The glomerular epithelium remains unstained. The fetal urine gives the characteristic stain of trypan-blue on filter paper.

It may be said, therefore, that the fetal liver and kidneys play an important part in the removal of foreign colloidal material from the fetal circulation.

Trypan-blue appears in the form of granules within cells in the umbilical cord, amnion, yolk-sac, and placenta.

*Umbilical cord.*—In the umbilical cord the dye appears in the form of fine granules in the mucoid connective tissue (fig. 8). These granules are aggregated in the cytoplasm of the cell on both sides of the nucleus.

*Amnion.*—Trypan-blue occurs abundantly in the cytoplasm of the amniotic epithelium in the form of small blue granules (fig. 9). Bondi (1905) observed similar granules in the human amnion after staining it with neutral red. He believed that this appearance signified a secretory activity on the part of the amniotic epithelium. In the light of our present knowledge, the fact that the amniotic membrane stains with neutral red and trypan-blue indicates that its cells possess cytoplasmic vacuoles capable of absorbing and storing these substances. As to the normal rôle of these cytoplasmic vacuoles very little is known. The mesothelial cells attached to the inner surface of the amniotic epithelium are also laden with fine blue pigment (fig. 9).

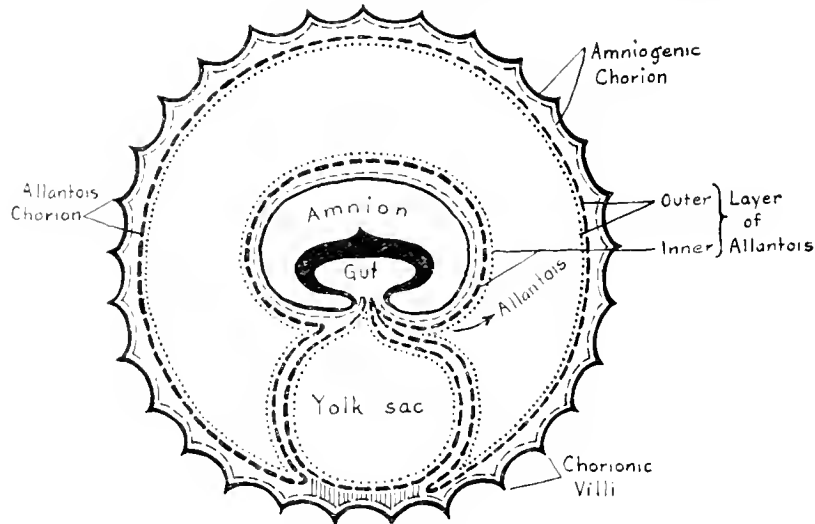
*Yolk-sac.*—In the guinea-pig the inverted yolk-sac or vitelline membrane becomes the outermost fetal membrane and a layer of endothelial cells consequently

comes in contact with the maternal tissue of the uterine wall. Goldmann showed that in the mouse this layer of cells plays an important rôle, similar to that of chorionic epithelium, in the transmission of nutritive material from mother to fetus. The endodermal cells have an enormous capacity for storing colloidal material. They, as well as the chorionic epithelium of the placenta, are responsible for the failure of foreign colloids, injected into the maternal blood-stream, to enter the fetus (figs. 5 and 10). These same endodermal cells appear to act as a barrier to the passage of colloids in the opposite direction, from fetus to mother, for in the vitally stained fetuses the same cells are heavily laden with dye (fig. 11).

*Placenta.*—Trypan-blue is absorbed and stored in a few of the endothelial cells lining the capillaries supplying the chorionic villi. These cells are laden with granules of dye and protrude into the lumina of the vessels.

#### OBSERVATIONS UPON FETAL CATS.

The development of the fetal membranes of the cat and other carnivora differs markedly from that observed in rodents, such as the mouse, rat, and guinea-pig. One of the essential differences is that in carnivora the embryo develops upon the surface of the blastodermic vesicle instead of within it, and consequently the germ layers do not undergo *inversion*. In the cat fetus we find as the outermost fetal covering the amniogenic chorion. A well-developed allantois separates chorion and



TEXT-FIGURE NO. 1.—Diagrammatic representation of the fetal membranes of the dog. (After Bonnet.)

amnion. The yolk-sac is entirely closed and becomes reduced in size as pregnancy advances. The placenta surrounds the fetus as a broad, circular band, hence called *placenta zonaria*. A diagram (text-figure 1) borrowed from Bonnet (1907) makes these relationships clear. Trypan-blue was injected into the amniotic cavities of a number of cat fetuses during the latter part of pregnancy. Vital staining of the fetuses always occurred. Two litters of kittens, living and vitally stained, were born 5 and 8 days respectively after a single injection of trypan-blue into the amniotic sacs.

The maternal tissues remain unstained after injection of trypan-blue into the fetuses. The reverse happens if the dye is injected into the maternal circulation. The tissues of the mother become deeply stained, while those of the fetuses do not, and such a mother gives birth to unstained offspring. The placenta prevent the dye from passing into the fetal circulation, as can be easily demonstrated by examining microscopically a section from the placental labyrinth. The fetal cells separating the maternal blood-spaces from the fetal capillaries contained enormous numbers of fine blue granules within their cytoplasm. The chorion, amnion, yolk-sac, and allantois of the fetus failed to stain, either macroscopically or microscopically, after injection of trypan-blue into the maternal circulation. In several experiments the dye was injected into the space between uterine wall and chorion, but even then it was not absorbed by the fetal membranes. (A detailed account of these observations is given on pages 54-59.)

Colloidal dyes were absorbed from the amniotic cavity of the cat fetus as readily as from that of the guinea-pig. Trypan-blue was found in the stomach and small intestine of nearly all the fetuses examined. It passed with equal readiness into the trachea and bronchi. The amnion, soon after injection, became intensely stained and gradually the umbilical cord, placenta, and fetus turned blue. The mesothelium between amnion and allantois is vascularized by numerous branches from the umbilical vessels, and it was through these that absorption occurred.

It was further observed that when trypan-blue was injected into the allantoic sac of the fetus the allantoic membrane did not stain, nor did absorption of any of the injected dye occur. The allantoic membrane appeared to be impermeable to the dye. It is interesting to recall that the allantoic arises as an outgrowth from the hind-gut and also is thought to be a reservoir for fetal urine. It may also be recalled that in the adult trypan-blue is not absorbed from the urinary bladder.

#### CONCLUSIONS.

1. Substances injected into the amniotic cavity of the guinea-pig and cat are absorbed during the latter half of pregnancy. Absorption occurs in three ways: (*a*) through the gastro-intestinal tract; (*b*) through the respiratory tract; and (*c*) by diffusion through the amniotic membrane.

2. Amniotic fluid is normally swallowed and also inspired by the fetus during the latter half of pregnancy.

3. The fetal guinea-pig may be vitally stained by injecting a colloidal dye into the amniotic sac. Vitally stained cells are abundant in the fetus and membranes. The chief of these are the endothelial cells lining the hepatic sinuses, the epithelium of the renal convoluted tubules, the amniotic epithelium, and the endothelial cells of the placental capillaries. The endodermal cells of the yolk-sac are extremely phagocytic toward vital dyes.

4. Foreign colloidal material can not pass from the fetal into the maternal circulation.

---

My appreciation is due Dr. W. C. Quinby for suggestions which were of value in carrying out these experiments.

## II. BEHAVIOR OF THE FETAL MEMBRANES AND PLACENTA OF THE CAT TOWARD COLLOIDAL DYES INJECTED INTO MATERNAL BLOOD-STREAM.

The extensive researches of Gusserow, Fehling, Zuntz, Zweifel, Wiener, Benecke, Krukenberg, and Preyer have demonstrated the passage of gases and dissolved crystalline substances from the maternal into the fetal circulation. Traces of potassium iodide, potassium ferrocyanide, sodium salicylate, benzoic acid, sodium indigo sulphonate, etc., were observed in the fetal urine and in the amniotic fluid after their administration to the mother. The passage of chloroform from the maternal to the fetal circulation has been observed repeatedly. That true solutions are capable also of passing in the opposite direction, from fetus to mother, has been shown for strychnine by Savory and later by Gusserow; for nicotin and curarine by Preyer, for alcohol by Nieloux.

For many years there was less clarity concerning the passage of formed substances (such as proteins and fats) through the placenta. It is now believed, mainly from the experimental work of Ascoli, Bonnet, Hofbauer, and Goldmann, that such substances are not directly transmitted through the placenta, but must first undergo a breaking-down in the epithelium of the chorion before assimilation by the fetal blood-stream is possible. Hofbauer considers the activity of the chorionic epithelium as comparable in many respects to absorption by the intestinal mucosa.

A number of observations have been made on the behavior of the fetus toward inert colloids and particulate matter introduced experimentally into the maternal blood-stream. The general conclusion drawn from them is that foreign colloidal or particulate matter fails to reach the fetal circulation, due to the fact that the placenta and fetal membranes are impenetrable to colloidal substances which the chorionic epithelium is unable to convert into an assimilable form.

Jassinsky (1867) injected a suspension of carmine into pregnant dogs and, although the animals died from this procedure in about 20 minutes, he observed that the substance did not reach the fetal circulation but was held up in the placenta.

Reitz (1868) injected a suspension of cinnabar into the jugular vein of a pregnant rabbit. He claims to have subsequently found particles of the injected material in the coagulated blood of the heart and in the capillaries of the brain of the fetus. His observations appear erroneous in the light of our present knowledge.

Hoffmann and Langerhans (1869) state that after injecting a nearly full-term rabbit with carmine they found no trace of the dye in the fetus or placenta.

Fehling (1876) injected india ink into the femoral vein of a pregnant rabbit and killed the animal 24 hours later. He observed that the fetus contained none of the ink, but he does not describe how the placenta prevented it from entering the fetal blood-stream.

Schlecht (1907) describes a pregnant mouse which had been stained by the repeated injection of lithium carmine. The dye had failed to stain the fetuses but was plainly visible in the placenta and fetal membranes. Microscopically it was found throughout the placenta in the form of fine red granules in the cytoplasm of the chorionic epithelium. None of the decidual cells contained dye granules. The outermost membrane of the mouse (the *inverted yolk-sac*, which Schlecht wrongly



terms *chorion*) was deeply stained but the amnion was not. He shows an illustration in which the endothelial cells of the inverted yolk-sac are seen heavily laden with dye, while the amniotic epithelium contains none.

The only complete observations on the behavior of the fetus toward injected foreign colloids are those of Goldmann (1909), who studied the mouse and rat with great care. Into a number of pregnant mice and rats he injected colloidal solutions of the benzidine dyes, pyrrhol-blue and trypan-blue. These dyes are practically non-toxic to living tissue. The result was that in every instance the tissues of the mother became deeply stained, the dye appearing in the form of blue granules in many of the cells of the body. On opening the uterus of such a vitally stained animal the fetuses were found unstained, the dye apparently having been prevented from entering their bodies by the placenta and membranes, all of which were a dark blue. On examining sections of the placenta and membranes, Goldmann found that the dye had been absorbed by many of the fetal cells and appeared in the form of blue granules within their cytoplasm; to this circumstance he attributed the failure of the dye to reach the fetal circulation. In the placenta he observed the dye in the fetal ectoderm, particularly in the giant cells or angioblasts, and in the entire chorionic epithelium of the labyrinth which separates the maternal blood-spaces from the fetal capillaries. The decidual cells, as well as the mesenchyme of the villi and the endothelium of the fetal capillaries, were unstained. He saw further that the dye was very abundant in the endodermal cells of the inverted yolk-sac. In his earlier paper Goldmann claimed that the amniotic fluid was stained blue and he believed that it consequently must be a secretion from the neighboring vitally stained endothelium of the yolk-sac and hence derived ultimately from the maternal blood-stream. In a later publication (1913) he contradicts his former assertion regarding the staining of the amniotic fluid.

Concerning the significance of vital staining in the placenta, several opinions have been advanced. Schlecht (1907) believes that the chief function of the vitally stained chorionic cells is to protect the fetus from toxic substances in the maternal blood-stream. Goldmann sees in them a group of cells which are tremendously important in the storage of nutrient material for the fetus. He was led to this view by demonstrating that these same cells are normally laden with glycogen and give staining reactions for iron and fat.

Goldmann's work upon the placenta was confined to rats and mice, whose embryology is nearly alike, and he found that these two genera behaved the same toward vital dyes. In view of the dissimilarity in the development of the placenta and fetal membranes in the different orders of mammalia, it is surprising that no further studies on the action of vital dyes in pregnant animals have been undertaken.

Turning to the laboratory animals—the mouse, rat, guinea-pig, rabbit, cat, dog, and monkey—one finds that they all belong to the *Deciduata*, but that they fall into three orders: *Rodentia*, *Carnivora*, and *Primates*. In the development of the placenta and fetal membranes these orders exhibit distinct and characteristic differences which it will be of interest to consider in the light of vital staining. The present study concerns the behavior of the placenta and fetal membranes of

the cat toward trypan-blue. For comparison a number of vitally stained pregnant mice, rats, guinea-pigs, and rabbits were also examined. The dye was injected into the mother intravenously on successive days. In the cats used, pregnancy was more than half completed.

In the gross the uterus of the vitally stained cat appeared deeply stained. On opening it the placenta and unruptured membranes could be easily shelled out. The placenta, which completely surrounds the fetus as a broad band or belt, was stained a deep blue (fig. 13). The chorion (which incloses the poles of the fetus) was unstained with the exception of a zone a few millimeters in width, along the placental borders, which was a mottled blue. This zone was found to be more marked late than early in pregnancy. On rupturing the membranes the fetus, the umbilical cord, the yolk-sac, and the allantoic and amniotic membranes were found entirely unstained. There was no dye in the allantoic or the amniotic fluid.

It may be said that in the cat, when the fetuses are normal and living, staining of the amniotic fluid does not occur. In this my observation differs from that originally made by Goldmann (1909), who described the amniotic fluid of the mouse and rat as bright blue. It should be noted that in a later paper (1913) Goldmann stated briefly, without giving further experimental data, that the amniotic fluid, as well as the embryo, is unstained. He had previously thought that his observation lent support to the theory that the amniotic fluid is in whole or in part derived from the maternal blood-stream. From the present experiments it seems probable that normally inert colloidal substances are unable to pass through the placenta or outermost fetal membrane. These experiments shed no light on the derivation of the amniotic fluid, and one can only venture the theory that the colloids normally found in the amniotic fluid are probably not of direct maternal origin. In the experiments described in the foregoing study trypan-blue was injected directly into amniotic sacs of living fetuses, in which case there was rapid absorption of the dye into the fetal blood-stream with vital staining of the embryo.

Further evidence that trypan-blue does not ordinarily reach the blood-stream of the fetus is afforded by the observation that several of the vitally stained cats in these experiments gave birth to litters of living young which were unstained.

Before describing the microscopic appearance of the vitally stained placenta of the cat, it may be of interest to recall briefly its comparative development and architecture. The placentae of mammalia have been classified by the degree of union which occurs between the fetal and maternal tissues. Thus in the most primitive type, seen in the pig, there exists merely an apposition of the chorionic epithelium to the epithelium of the uterus. Consequently the maternal vessels are widely separated from the fetal ones by a number of layers of cells. In the slightly higher developed placentae of ruminants the uterine epithelium is nearly all absorbed by the trophoblast, so that a more intimate union of the chorion with the maternal tissues results. In carnivora, further resorption of the maternal tissues by the trophoblast occurs, so that finally a complex labyrinth of chorionic villi and maternal vessels is formed. The maternal blood is separated from the chorionic epithelium by a single layer of endothelial cells, and the distance from maternal to fetal vessels is greatly diminished. Such a placenta has been termed

*placenta endotheliochorialis* by Grosser (1909), from the fact that endothelium and chorion form the line of juncture between the two tissues. Lastly, there is the type of placenta common to Rodentia, Insectivora, Chiroptera, and Primates, in which even the endothelium of the maternal vessels is obliterated by the trophoblast, so that the maternal blood flows into spaces bounded only by the fetal cells. Therefore, there remain between the maternal and the fetal blood-streams solely the thin layer of chorionic syncytium, the delicate stroma of the villi, and the endothelium of the embryonic capillaries. This type has been termed by Grosser *placenta hemochorialis*.

The most careful study on the development of the placenta of the cat has been made by Duval (1894), who showed that the trophoblast invades the uterine wall, absorbing the uterine epithelium and the decidua, and forming (as it advances) a mass of syncytium and giant cells which gradually invests the maternal vessels. According to this observer, the syncytium and giant cells which form the bulk of the placenta consist principally of chorionic ectoderm. One finds, therefore, in the labyrinth of the mature placenta, numerous maternal capillaries, lined with endothelium and surrounded by masses of epithelium of fetal origin, beneath which lie the stroma of the villi and the embryonic blood-vessels. Duval's view that the syncytium and the giant cells are of ectodermal origin in the cat and dog has been generally accepted, but not without several noteworthy opponents. Thus Bonnet (1903) claims that a narrow zone of decidua separates the chorionic ectoderm from the maternal vessels. He believes, however, that late in pregnancy this strip of decidua becomes intimately fused with the chorionic ectoderm and forms a lamellar or syncytial layer in which the character of the individual elements is no longer recognizable. Another view is held by Schoenfeld (1903), who believes that decidual cells contribute to the formation of the syncytium, but that the incorporation of these cells does not prevent the chorionic epithelium from coming into direct contact with the maternal endothelium.

A similar difference of opinion exists regarding the origin of the epithelial masses which occur at the junction of the chorion and decidua basalis ("Umlagerungs-zone" of Strahl). Duval believes that "les lames basales" and "les areades ectodermiques," as he calls these structures, are composed of fetal ectoderm, whereas Grosser believes they are largely decidual cells and hence should be designated *symplasma*.

Duval has pointed out that in the cat the chorionic ectoderm is composed of cells with fairly well defined boundaries, whereas in the dog it is largely syncytial. In the cat the chorionic ectoderm forms lamellæ of epithelium about the maternal capillaries, and in it two types of cells may be discerned. One finds large, oval cells (termed by Duval *central* or *giant* cells) which lie close to the capillary endothelium and which have a single nucleus or often two or three large round nuclei and a vacuolated cytoplasm. These cells become more conspicuous as the placenta matures, and Duval believes that they arise from the less differentiated epithelium beneath them. Some have thought that they are of maternal origin and have designated them decidual or serotina cells.

Surrounding the giant cells are numerous smaller cells with single, more deeply staining nuclei. These at first possess abundant cytoplasm and distinct cell

outlines, but as gestation advances their cytoplasm shrinks so that they appear as narrow sheaths around the capillaries and the prominent giant cells.

The placental labyrinth of the cat is stained very deeply by trypan-blue. The dye appears in both types of cells composing the chorionic ectoderm just referred to (figs. 14 and 15). In the giant cells it is particularly striking, filling the cytoplasm with numerous bright blue granules. In the smaller epithelial cells constituting the lamellæ it is no less abundant but tends to appear in clumps. It is also observed in the cytoplasm of many of the endothelial cells lining the maternal capillaries, but none of it occurs in the fetal mesoderm or in the endothelium of the embryonic blood-vessels. In the masses of chorionic ectoderm at the junction of the chorion and spongiosa very little trypan-blue is found. One receives the impression that this is due solely to the fact that these cells are too remote from the maternal vessels in which the dye is circulating to participate in its absorption. No dye is seen in the epithelium of the remains of the uterine glands or in the detritus in their lumen. Macrophages, heavily laden with trypan-blue, are present in large numbers in the stroma surrounding the gland and in the uterine musculature.

The only other noteworthy deposit of dye is found in the chorionic ectoderm along the borders of the placenta. In carnivora the maternal blood extravasates into the space between the uterine epithelium and the chorion along the margins of the placenta; hence this region in the dog has been termed the *green border* and in the cat the *brown border*. The chorionic villi which dip into this mass of blood are actively engaged in its resorption, and the epithelial cells covering them are seen under the microscope to contain numerous entire and fragmented red blood-corpuscles, besides abundant pigment. It is thought that in this way the fetus obtains the iron necessary for its growth. In the cat the chorionic villi in this region are covered by a single layer of high columnar epithelial cells which have club-shaped distal ends and nuclei situated close to the basement membrane. The distal, broad end of the cell contains numerous whole or fragmented erythrocytes, whereas deposits of finely granular brown pigment are seen in the middle and proximal portion of the cell. In the vitally stained animal numerous granules of trypan-blue are distributed throughout the central and proximal portions of these same cells (fig. 4). The chorionic ectoderm over the poles of the fetus is unstained.

The observations made upon pregnant cats may be briefly summarized as follows:

1. Trypan-blue is incapable of passing from the maternal blood-stream through the placenta and membranes into the fetus or even into the amniotic or allantoic fluids.
2. Trypan-blue, injected into the maternal blood-stream, reaches the placenta, where it is absorbed and stored, principally by the chorionic ectoderm of the labyrinth. It is stored in the cytoplasm of the chorionic cells in the form of granules.
3. The endothelium which lines the maternal capillaries of the placental labyrinth absorbs and stores the dye in the same manner as the chorionic ectoderm.
4. Trypan-blue is also deposited in the chorionic epithelium of the *brown border*.

## CONCLUSIONS.

It appears that inert colloids are normally not transmitted through the mammalian placenta or membranes and consequently can not enter the fetal circulation or the fluids surrounding the embryo. The outermost fetal membrane, whether it be of ectodermal origin as in carnivora, or endodermal as in rodents, invariably fails to transmit such substances.

The chorionic ectoderm of the placenta possesses, in all the animals investigated, the ability to absorb and store foreign colloids. It is interesting to note that in the fetus vital dyes are absorbed and stored in both ectoderm and endoderm, germ layers which in the adult rarely (choriod plexus) participate in their storage. Cells of all three germ layers may under suitable conditions stain vitally, and it appears that the power to ingest benzidin dyes is not limited to any one class or group of cells.

The deposition of vital dyes is greatest in those cells of the placenta and fetal membranes in which the metabolic exchange between mother and fetus is most active. It represents an accumulation of unassimilable material along the pathways between mother and fetus.

Hofbauer (1905) has pointed out the striking similarity between the placenta and intestines in their power of absorption and excretion. A fundamental difference would seem to exist in their behavior toward trypan-blue. Whereas the dye becomes aggregated in large amount in the chorionic cells, none of it is absorbed by the intestinal mucosa. Why particles the size of trypan-blue should readily enter and be stored in the chorionic but not the intestinal epithelium is a question which requires further study.

## BIBLIOGRAPHY.

- AHLFELD, F., 1885. Ueber die Bedeutung des Fruchtwassers als Nahrungsmittel für die Frucht. *Berichte und Arbeiten*, vol. 2, p. 22. Leipzig.
- BONDI, J., 1905. Zur Histologie des Amnioepithels. *Zentralbl. f. Gyn.*, vol. 29, p. 1073-1076.
- BONNET, R., 1903. Beiträge zur Embryologie des Hundes. Zweite Fortsetzung. *Anat. Hefte*, vol. 20, p. 323.
- , 1907. *Lehrbuch der Entwicklungsgeschichte*. Berlin.
- CLARK, E. L. and E. R., 1918. On the relation of certain cells in the tadpole's tail toward vital dyes. *Anat. Rec.*, vol. 15, p. 231.
- DÜDERLEIN, A., 1890. Vergleichende Untersuchungen über Fruchtwasser und foetalen Stoffwechsel. *Arch. f. Gyn.*, vol. 37, p. 141.
- DUVAL, M., 1894. Le placenta des carnassiers. *Jour. de l'anat. et de la physiol.*, vol. 31, pp. 189, 262, 649.
- FEHLING, H., 1876. Zur Lehre vom Stoffwechsel zwischen Mutter und Kind. *Arch. f. Gyn.*, vol. 9, p. 523.
- FRANK, 1901. *Handbuch der tierärztlichen Geburtshilfe*. Berlin.
- GOLDMANN, E. E., 1909. Die äussere und innere Sekretion des gesunden und kranken Organismus im Lichte der vitalen Färbung. Teil I. *Beitr. z. klin. Chir.*, vol. 64, p. 192.
- , 1912. Same title, Teil 2. *Ibid.*, vol. 78, p. 1.
- GOLDMANN, E. E. 1913. Experimentelle Untersuchungen über die Function der Plex. choroid und der Hirnhäute. *Arch. f. klin. Chir.*, vol. 101, p. 735.
- GROSSER, O., 1909. Vergleich. Anat. u. Entwicklungsgeschichte d. Eihäute und Placenta. Wien u. Leipzig.
- HOFBAUER, P., 1905. *Grundzüge einer Biologie der menschlichen Placenta*. Wien u. Leipzig.
- HOFFMANN, F. A., and P. LANGERHANS, 1867. Ueber den Verbleib des in die Circulation eingeführten Zinnobers. *Virchow's Arch. f. path. Anat.*, vol. 48, p. 304.
- JACQUÉ, L., 1903-4. De la genèse des liquides amniotiques et allatoidiens. *Mem. couron. Acad. roy. de Belge*, vol. 63, p. 1.
- JASSINSKY, P., 1867. Zur Lehre über die Struktur der Placenta. *Virchow's Arch. f. path. Anat.*, vol. 40, p. 341.
- KEHRER, F. A., 1867. Vergleichende Physiologie der Geburt des Menschen und der Säugethiere. *Beitr. z. verg. u. exper. Geburtsk.* Giessen, Heft 2.
- MCCLEURE, C. F. W., 1918. On the behavior of *Bufo* and *Rana* toward colloidal dyes of the acid azo group (trypan-blue and dye No. 161). *Amer. Anat. Memoirs*, No. 8.
- PREYER, W., 1895. *Spezielle Physiologie des Embryos*. Leipzig.

- REITZ, W., 1868. Ueber die passiven Wanderungen von Zinnoberkornchen durch den thierischen Organismus. *Berichte der Wiener Akad. math. naturw. Classe*, vol. 57 (2), p. 8.
- SCHLECHT, H., 1907. Experimentelle Untersuchungen über die Resorption und die Ausscheidung des Lithionkarmins unter physiol. u. pathol. Bedingungen. *Ziegler's Beiträge*, vol. 40, p. 312.
- SCHOENFELD, H., 1903. Contribution à l'étude de la fixation de l'œuf des mammifères dans la cavité utérine, et des premiers stades de la placentation. *Arch. de biol.*, vol. 19, p. 701.
- WEED, L. H., 1917. The development of the cerebro-spinal spaces in pig and in man. *Contributions to Embryology*, vol. 5, Carnegie Inst. Wash. Pub. No. 225.
- WISLOCKI, G. B., 1916. The staining of amphibian larva with benzidine dyes, with especial reference to the behavior of the lymphatic epithelium. *Amer. Jour. Physiol.*, vol. 42, p. 125.
- ZUNTZ, N., 1885. Ueber die Quelle und Bedeutung des Fruchtwassers. *Pflüger's Arch.*, vol. 6, p. 548.
- ZWEIFEL, 1875. Untersuchungen über das Meconium. *Arch. f. Gyn.*, vol. 7, p. 471.

## EXPLANATION OF PLATES.

## KEY TO LEGENDS.

<i>b. b.</i>	Brown border.	<i>endo.</i>	Endothelium.	<i>m. b. v.</i>	Maternal blood-vessel.
<i>ch.</i>	Chorion.	<i>e. v.</i>	Endodermal villi.	<i>pl.</i>	Placenta.
<i>ch. ep.</i>	Chorionic epithelium.	<i>f. b. v.</i>	Fetal blood-vessel.	<i>r. b. c.</i>	Red blood-cell.
<i>e. l.</i>	Ectodermal lamella.	<i>g. c.</i>	Giant cell.		

## PLATE 1.

- FIG. 1. Gross appearance of the placenta and fetal membranes from the uterus, 12 hours after injection of a vital stain into the amniotic cavity. Note the prominent omphalo-mesenteric vessels.
- FIG. 2. Gross appearance of a guinea-pig fetus with the amnion opened 36 hours after injection of trypan-blue into the amniotic cavity. The omphalo-mesenteric vessels can be seen in the wall of the amniotic sac.
- FIG. 3. Guinea-pig fetus, nearly full term, after injection of potassium ferrocyanide and iron ammonium citrate into the amniotic cavity. The fetus was killed 30 minutes after injection and immersed in acid formalin. Notice the deep Prussian-blue stain in the lungs and trachea. The stomach contents also were blue. The kidneys are slightly stained.
- FIG. 4. Sagittal section of guinea-pig, measuring 36 mm., 48 hours after the introduction of trypan-blue into the amniotic cavity. Note that the central nervous system remains unstained.
- FIG. 5. Appearance of the placenta and membranes of a guinea-pig fetus after a single injection of trypan-blue into the maternal circulation. Notice the endodermal villi which are deeply stained. *e. v.* endodermal villi.

## PLATE 2.

- FIG. 6. Precipitation of Prussian blue in the omphalo-mesenteric vessels by immersion of the fetal membranes in acid formalin 30 minutes after the injection of 1 per cent potassium ferrocyanide and iron ammonium citrate into the amniotic cavity, demonstrating the escape of solutions from the amniotic sac into the fetal circulation.
- FIG. 7. Kidney of guinea-pig fetus measuring 36 mm., showing trypan-blue in the convoluted tubules 72 hours after the injection of the dye into the amniotic cavity. Notice that the glomeruli are unstained.
- FIG. 8. Section of the umbilical cord of a guinea-pig fetus measuring 42 mm., showing vitally stained mucoid connective-tissue cells, 24 hours after injection of trypan-blue into amniotic cavity. *U.*, lumen of umbilical vein.
- FIG. 9. Section of amniotic membrane of guinea-pig fetus measuring 41 mm., showing absorption of trypan-blue, 24 hours after injection of the dye into the amniotic cavity.

## PLATE 3.

- FIG. 10. Section of the endodermal villi, the modified remains of the "inverted yolk-sac," heavily laden with pigment after repeated injection of a colloidal dye into the maternal circulation.
- FIG. 11. Wall of the "inverted yolk-sac," showing the endodermal cells as they appear 24 hours after an injection of trypan-blue into the amniotic cavity. Fresh membrane slightly counterstained with alum carmine.
- FIG. 12. Section through placenta of guinea-pig fetus measuring 40 mm., showing a vitally stained macrophage 76 hours after injection of trypan-blue into the amniotic cavity.

## PLATE 4.

- FIG. 13. Cat fetus, measuring 6.8 cm., surrounded by unruptured membranes, showing the coloration of the placenta and chorion after repeated injection of trypan-blue into the maternal circulation. Note that the chorion over the poles of the fetus is unstained. The allantoic and amniotic fluids do not contain a trace of dye and the fetus is unstained.
- FIG. 14. Placenta of cat, nearly full term, after repeated injection of trypan-blue into the maternal blood stream, showing the distribution of dye in the chorionic epithelium.
- FIG. 15. Placenta of a vitally stained cat, nearly full term, showing several multinuclear giant cells of the chorionic ectoderm filled with particles of trypan-blue.
- FIG. 16. Section of the "brown border" of the placenta of a cat, nearly full term, showing the absorption of erythrocytes and of trypan-blue by the chorionic epithelium.

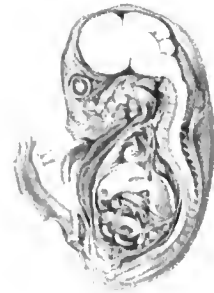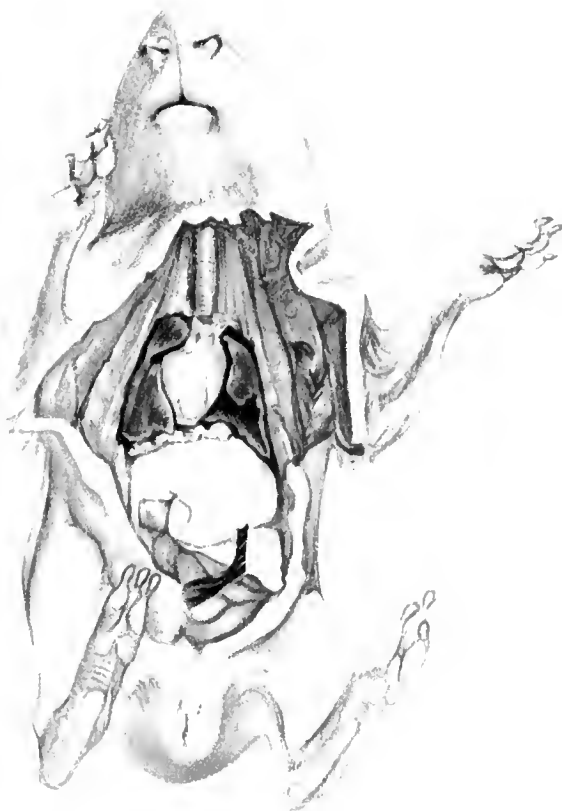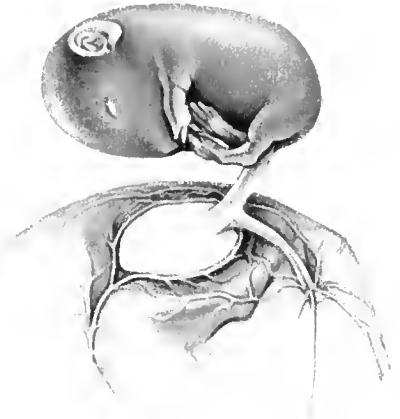
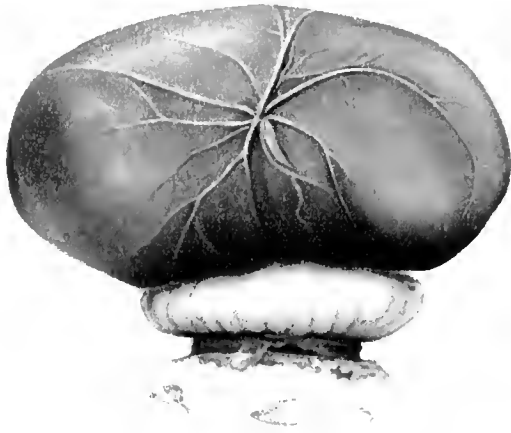


FIG. 4

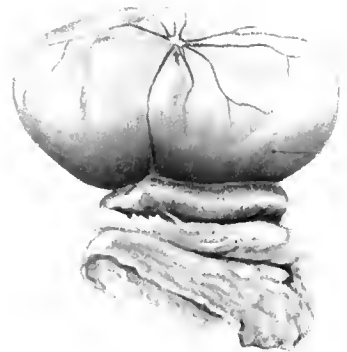

FIG. 5





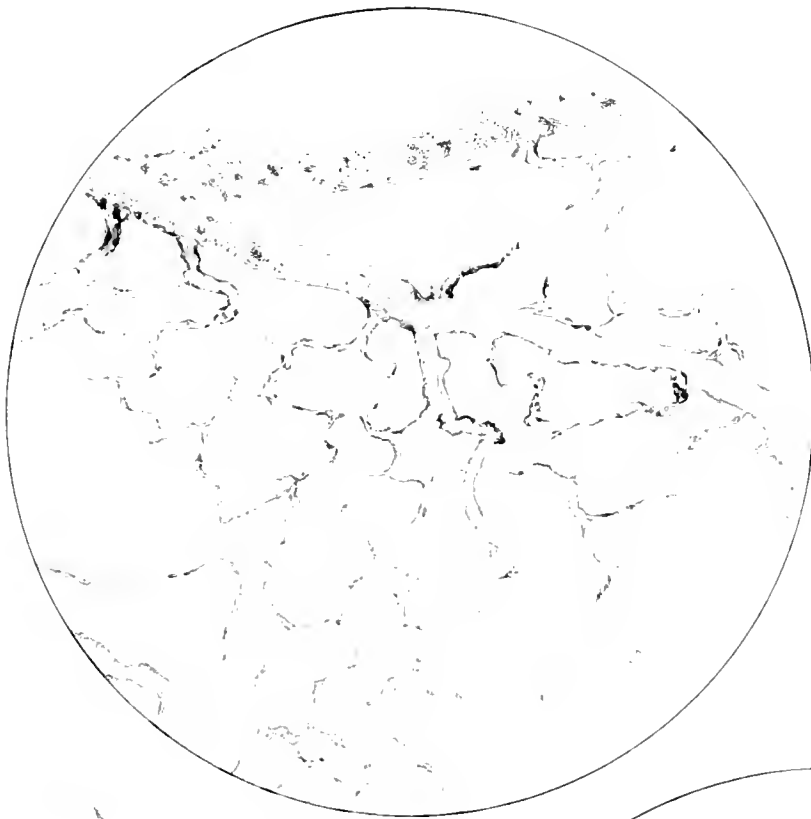



Fig 6



F 6



F 7






FIG. 10




FIG. 11



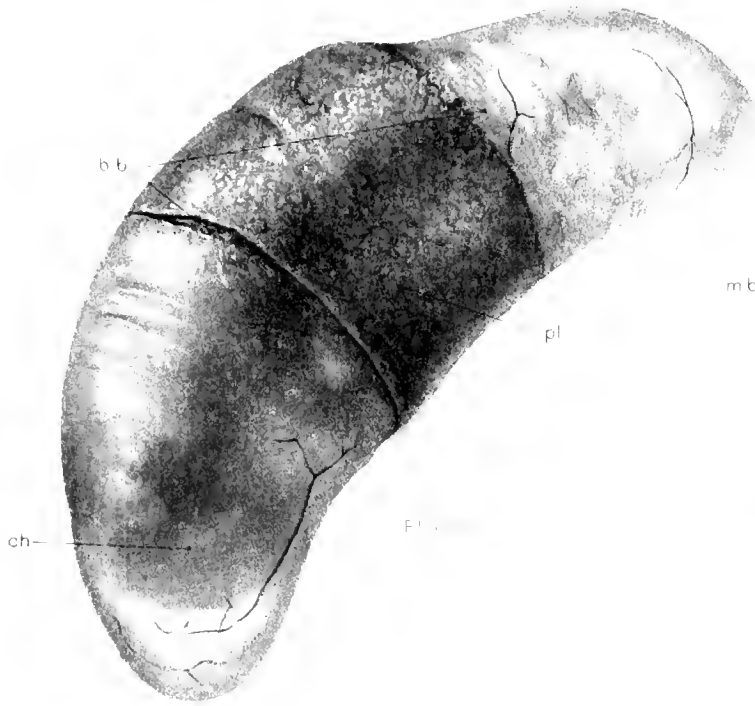


FIG. 13



FIG. 14

fbv

gc

el

nbc

mbv

el

fbv

fbv

gc

ch ep

fbv

FIG. 14

mbv

FIG. 15



CONTRIBUTIONS TO EMBRYOLOGY, No. 52.

A HUMAN EMBRYO AT THE BEGINNING OF SEGMENTATION, WITH  
SPECIAL REFERENCE TO THE VASCULAR SYSTEM.

BY N. WILLIAM INGALLS.

With five plates and one text-figure.





# A HUMAN EMBRYO AT THE BEGINNING OF SEGMENTATION. WITH SPECIAL REFERENCE TO THE VASCULAR SYSTEM.

BY N. WILLIAM INGALLS.

The embryo which forms the subject of this communication is No. 1878 of the Carnegie Embryological Collection. Data relative to its age are rather indefinite, but it is apparent that the menstrual age is in excess of the real or fertilization age. Further evidence of this is found in the fact that the tissues of the ovum (and this applies also to the endometrium) had begun to suffer slightly, with the result that the fixation and staining reactions are not all that could be desired. These changes are not, however, of such a nature or degree as to raise doubts about the specimen being normal. They have been further complicated by what has been in some respects an unfavorable plane of section, so that at times considerable difficulty has been encountered in determining certain of the finer morphological details presented by this particular stage. This account, therefore, will confine itself to a brief description of the essential features of the embryonic body and of the structures immediately adjoining. We shall not enter upon any discussion of the findings in the yolk-sac or chorion, or of the finer histological details of the embryo itself. Evidences of mitotic activity are encountered, but they are not especially frequent.

Concerning the gross specimen we may quote the laboratory notes as follows:

“Main mass of specimen composed of decidua, clots and scrapings from curettage. In addition to this there is an isolated flattened ovum measuring  $7.5 \times 10.5 \times 12$  mm. The specimen is stained pink, like the scrapings obtained from curettage. The bare surface of the chorionic vesicle, which comprises about one-third of area of ovum, is folded somewhat. The villi seem to be well-developed, but are absent also on a narrow strip in the side opposite the bare area. The bare areas look rather thick-walled and the villi rather clubbed.

“Upon opening the ovum from the bare area it felt rather firm. The chorion was thick and most of the interior was filled with a web-like magma, small portions of which were not unlike absorbent cotton. It was quite easy, however, to remove all the magma without injury to the embryo. The latter looked somewhat mottled, especially in the region of the yolk-sac, which lay somewhat at right angles to the amnion. At the point of union of the two a somewhat elongated, opaque disc could be seen quite distinctly.”

## EXTERNAL FORM. EMBRYO AND ADNEXA.

The form of the embryonic body (figs. 1, 2, 3, and 4) is in general quite similar to a larger and older specimen, No. 391, 2 mm. (Dandy, 1910), and a much more advanced one, No. 1201, also 2 mm., both of the Carnegie Collection. In all three, as in so many other embryos of about this stage, there is a well-marked dorsal concavity. In No. 1878 this flexure is very abrupt, even more marked than in No. 1201 (Evans and Bartelmez, 1917), and is most acute about, or slightly in advance of, the line between the future brain and cord. Posterior to the angle thus formed is a

short portion of the dorsum of the embryo which is very nearly straight, while beyond this is a gentle rounded elevation completing the embryonic body. Seen in profile, No. 1878 is strikingly like the older but slightly shorter embryo (II 98), 1.27 mm., recently described by Wilson (1914, plate III). The Krömer-Pfannenstiel embryo, while only a little longer (1.8 mm.) is much more advanced. The model shows the body of this embryo to be practically straight (Krömer, 1903; Keibel and Elze, 1908). Indeed, in the model there seems to be hardly room enough for the heart and pericardial cavity, as they have been described and figured in section, between the brain and the yolk-sac.

There can be no doubt that the early development of the heart, and especially of the myoepericardial mantle and pericardial coelom, plays a very important rôle in the lifting up of the head. This general effect on the anterior end of the embryo could be accentuated only by the precocious development of the forebrain. Further evidence of such an elevating process may be seen in the relation of the amniotic reflection anteriorly, where, immediately below the stomodeum it is lifted up as a saddle-like ridge by the large pericardial coelom beneath. In addition, one may conclude that a large yolk-sac would have a similar tendency to raise the heart and with it, of course, the entire anterior end of the embryo. This might help explain the condition in the Krömer embryo, where the yolk-sac is not very large. While doubtless subject to not a little individual and relative variation, the yolk-sac, throughout most of its history, especially later and possibly also very early, is rather small as compared with the embryo and body-stalk. For a very brief period, however, it undergoes a rapid increase in dimensions and the relative size of the embryo and sac is, for a short time, reversed. In the Krömer specimen the relation of the two is being changed for the second and last time. Certainly the embryonic body is weaker and more pliable about its middle than anywhere else, and all things considered it is difficult to see how it could possibly be bent in the opposite direction. A dorsal flexure, normal or otherwise, is what one might expect at this time and, until more is definitely known as to the possible factors involved, some degree at least of such a flexion will have to be looked upon as normal. On the whole, it would be better to speak of an elevation or erection of the head, as also suggested by Wilson, and so put the emphasis where it undoubtedly belongs. There is no reason why a curve of this character may not later be wiped out entirely, as happens to so many others in the embryo, of which we will mention only the dorsal curvature of later stages, which is subject to very considerable individual variation. The deep, sharp kinks shown by the His embryos Lg. and Sch., 2.15 and 2.2 mm., respectively, may very well be abnormal, and, except their direction, they apparently have little if anything in common with the so-called flexure which we have just discussed. In the same category would fall the embryo Delaf. of Eternod (1909), noted as "2.1 mm. (?) ensellé," admittedly an old alcohol specimen. These kinks involve the body at a definitely more caudal point. They occur at a later stage in development, at a time when the diminishing yolk-sac not only offers less support to the embryo, but would be in a favorable position, on account of its narrowing attachments, to actually exert some traction upon the delicate body of

the embryo. It is quite conceivable that the earlier normal curve might grade insensibly into the later abnormal one. Wilson's specimen was, we imagine, very near the parting of the ways, where it would have either gradually straightened out or have suffered, through some influence, a much sharper degree of flexion.

No attempt will be made to institute a formal and detailed comparison of No. 1878 with other embryos, nor to determine its developmental status as regards them. Loose comparisons between embryos lose much of their apparent meaning on account of the variability in rate and manner of development. To such variation we have recently drawn attention (1918) and fortunate or extreme instances of it may yet throw considerable light on early human ontogeny.

The greatest length of embryo No. 1878, measured on a straight line from the anterior (later ventral) surface of the head just above the stomodeum to the cloacal membrane, is, as determined on the model, 1.38 mm. Of this, rather more than one-half will later be taken up into the head, the heart being now frankly in the head region, while the rest of the future body is represented by the remaining posterior part of the embryo, of which a small portion is occupied by the primitive streak.

The elevation of the posterior end of the body is not due solely to the sinking in of the region in front of it, but to a considerable extent to the developmental changes which will very shortly entirely remodel this part of the embryo. The anterior slope appears as a part of the general dorsal concavity, the posterior runs down to the extreme end of the body close to the body-stalk, while its lateral surfaces fall off quite rapidly to the attachment of the amnion. Anteriorly and less deeply over its summit it is grooved by the neural folds, which extend about one-third the way down the posterior slope, of which a little less than the caudal half is occupied by the primitive streak. The last-mentioned region, in part at least, corresponds to the steep declivity so well marked in the Glaevecke embryo of v. Spee and the 1.3 mm. stage of *Eternod*. This portion, due to its active growth, will not only contribute in length to the embryonic body but will also bring about the so-called folding-off of its caudal extremity. The results of this process are the formation of the hind-gut, the allantois then appearing as an appendage of the gut instead of the yolk-sac, and finally the shifting to the ventral surface of the originally dorsally placed cloacal membrane. Around the posterior margin of the tail-bud thus formed, the primitive streak may persist for some time. These changes, due to an active outgrowth rather than to any passive folding, are just beginning in No. 391 and are well under way in Krömer's embryo.

Concerning the body-stalk and amnion a few words here will suffice. The former is very large and massive, in fact much more bulky than the entire embryonic body, and is roughly spindle-shaped with its smaller end attached to the chorion quite obliquely. Its shape and size are due to the enormous vessels which it contains, especially about its middle third, where it bulges prominently into the amniotic cavity. On account of its relations to the body-stalk, the amnion shows two deep, lateral recesses on either side of the stalk. From the left recess there passes out into the stalk a long, irregular, hollow outgrowth which we may identify as an amniotic duct (fig. 3). Its length, including the funnel-shaped origin from the

general amniotic cavity, is about 0.6 mm. The duct crosses the body-stalk almost at right angles, close to the surface of the latter, and ends very near the distal extremity of the allantois and close to the chorionic surface of the body-stalk a short distance below the attachment of the stalk to the chorion. The lumen is very irregular, at times wanting, and is lined by cells which vary from low cuboidal to frankly cylindrical. Irregular thickenings or solid masses of cells also occur in the walls, some of which seem to have almost lost their connection with the duct. The whole structure is obviously undergoing retrogressive changes. Near the summit of the amnion there occurs a second small, slightly branched, but quite irregular diverticulum (not shown in the illustrations), which penetrates for some little distance into the substance of the body-stalk in the region of its attachment to the chorion. This slender, tubular structure is much smaller than the amniotic duct mentioned above; it is also less sharply demarcated from the surrounding mesenchyme, while its cells are rather more vacuolated.

#### EMBRYO AND ECTODERM.

The external configuration of the embryonic body is determined in large measure by the stage of development of the nervous system, which is here in the form of a groove, widely open throughout its entire extent. One may say that about one-half of this groove represents the future brain, and that at about the junction of this with the cord, or even a little in advance of this point, is where the flexure of the embryo is most marked. The primitive forebrain is especially prominent, being represented by two conspicuous crescentic folds, highest and broadest behind and approaching each other anteriorly, where they are separated by a shallow furrow. Behind, these folds are convex, separated by a deep groove, and the brain-wall here is not especially thick. In front their median slopes are distinctly concave, passing gently into the central depression of the neural groove. A similar, even more marked concavity is found in this region in embryo No. 1201. It is at this point, in front, that the walls of the neural groove are thickest, indicating the position of the later optic pits. The median groove (the bottom of the neural groove) is continued over the anterior surface of the head, spreading out and terminating in the buccopharyngeal membrane just above the attachment of the somatopleure. This portion of the brain, which we have identified as prosencephalon, is widest about its center, overhangs posteriorly the sides of the head ventral to it, and is placed at approximately right angles to the remaining caudal part of the brain.

Just behind the angle thus formed the brain is slightly narrower, but it soon increases again in diameter to form a spindle-shaped enlargement, the posterior limits of which are indistinct. This latter enlargement, which is not especially conspicuous, is the rhombencephalon, while the faint constricted portion in front of it we take to be the mesencephalon, although a part of what we have called fore-brain, just at the angle, may later give rise to more or less of the mid-brain. In other words, the cephalic flexure is very well marked at this early stage. A better term would be *mid-brain flexure*, since it is only the nervous system which is bent, and this over the anterior, blind end of the fore-gut. A straightening out of the

body of the embryo will render this flexure even more typical and conspicuous. The appearance of the fore-brain is here quite different from the condition as usually figured, where the neural folds are represented as being strongly convex. The remainder of the nervous system, represented by the cord, is a deep, open furrow in the back of the embryo. Caudally, there is a rather sudden decrease in the thickness of the ectoderm forming the folds; the groove also becomes very faint and shallow, but can be traced as far back as the primitive node. About the middle of the dorsal concavity, in the region which may be taken as upper cervical or lower medulla, the interval between the crests of the neural folds is less than elsewhere, and here the closure will first begin.

In the surface ectoderm on either side, about opposite the middle of the rhombencephalon, are two not very sharply delimited, moderate thickenings, which are the otic plates. They are in the main quite symmetrical, somewhat elongated, and measure about 0.08 mm. in diameter. The basal surface of the ectoderm here is cleaner and sharper than in the adjacent body-wall and hence more like the neural folds. These thickened areas are somewhat more extensive than shown in figures 1 and 2, but all of the material may not be found later in the otic vesicles, some being utilized in the separation off and covering in of the same. As indicative of a ganglion crest we may note that toward the anterior limit of the rhombencephalon there appear two fairly distinct and symmetrical collections of cells, of rather short extent, capping the neural folds on either side—the primordia of the ganglia of the fifth cranial nerves (figs. 1 and 2).

At the very posterior end of the embryo, occupying the lower half of the caudal slope of this part of the body, is the primitive streak. From the primitive node to the cloacal membrane it measures 0.13 mm. in length and is marked by a broad, shallow groove. At the primitive node there is a rather diffuse, loose connection between the three germ layers; the ectoderm is here distinctly thickened and faint indications of the remains of the dorsal opening of an archenteric canal can be made out. The latter seems to penetrate about half way to the entoderm and may therefore be in relation with the posterior end of the chorda, but nothing definite as regards this can be made out. Ventral and lateral to the primitive streak there is an abundance of rather loose mesenchyme.

The anterior (later ventral) surface of the head is regularly convex, with the median groove and beginning stomodeum as already noted. On either side, where this surface passes into the lateral surfaces of the head, are two quite distinct vertical grooves, the one on the left being rather deeper, shorter, and nearer the median line. Internally there is, on the left side, a shallow, poorly defined extension of somewhat thickened entoderm toward the ectodermic groove. The lateral surface of the head region is marked on the left side by two distinct, vertical, parallel furrows (fig. 1). The anterior one is short and is simply a fold involving the entire thickness of the body-wall, projecting internally into the pericardial cœlom. The other groove is much longer and if continued upward would cut the neural tube in the region of the mid-brain flexure. Corresponding with this posterior groove there is a similar one, on the right side, best marked low down, where its ectoderm lies close to the pharyngeal entoderm.

## ENTODERM AND DERIVATIVES.

The gut-tract (fig. 3) is represented at this stage by a well-defined fore-gut and what is combined mid-gut and hind-gut. There is as yet no real hind-gut, since the cloacal membrane is in the roof, while just behind this the allantois comes off from a rather deep, laterally compressed, funnel-shaped outpocketing of the yolk-sac, the roof of which is formed by the entoderm in the region of the cloacal membrane and primitive streak.

The fore-gut, about 0.5 mm. in length, makes a very decided angle with the future mid-gut, due to the erection of the whole anterior end of the embryonic body. It is at this time quite large and capacious, determining, together with the neural folds and heart, the configuration of this part of the embryo. Dorsally, in the mid-line, chordal region, it is in close relation throughout with the thin floor plate of the neural groove. In general, the dorso-ventral diameter is distinctly less than the transverse; its anterior half is definitely enlarged, especially in its transverse measurements, the future oral and pharyngeal regions. The shape of the cavity of the fore-gut varies considerably in its anterior and posterior portions. In the latter, from just behind the first pocket and thyroid to its communication with the yolk-sac, it may best be described as triangular or even T-shaped on section. Internally the dorsal wall is concave in the median line and then passes out to the roof in the rounded lateral angles. Externally, in the roof of these lateral recesses, on either side of the median ridge, are two rather faint, broad furrows which may be termed aortic and which are lost anteriorly on the roof of the pharynx. The two ventro-lateral walls appear as if pushed in toward the center, with the result that there is present a deep median trough in the floor and two lateral somewhat shallower grooves on either side, but close to the roof of the gut.

Externally, the fore-gut shows a prominent ventral keel corresponding to the internal median groove and two laterally projecting ridges which fade out behind on the yolk-sac. On either side of this keel the entodermal walls are concave, the dorsal wall is in general convex, the opposite holding for the interior. This ventral keel is in intimate relation with the developing heart, projecting through as it were between the two layers of the wide mesocardium until it lies quite close to the endothelial tube of the heart. The two dorsally placed, lateral grooves or recesses in the gut-wall lie behind the attachment of the mesocardium and behind the dorsal wall of the pericardial cœlom, projecting toward, but at some distance from, the beginning pleuro-peritoneal passages. Traced forward, the ventro-lateral walls of the gut open out as the space demanded by the developing heart gradually decreases. The dorso-lateral grooves likewise fade out as the result of these changes in the lateral walls. Just where these grooves merge into the enlarged anterior part of the fore-gut we may locate the earliest trace of the first entodermic pocket. On the right side there appears a small furrow, which extends for a short distance ventrally and very slightly posteriorly across the lateral wall, where it comes into relation with a second groove, which, if continued, would cut the median line just in front of the thyroid (fig. 4).

Externally in the ectoderm there is a well-marked linear depression of considerably greater extent than the small furrow just noted, but having the same direction. Here over an extent of about 0.04 mm. the ectoderm and entoderm are quite close together, no mesenchymal cells intervening, but the two layers are not in actual contact. Just in front of this groove lies one of the anterior, finger-like prolongations of the pericardial cœlom, while still farther forward are found the beginnings of the ventral aorta and first arch. However, on this (the right) side there are other indistinct furrows in both the ectoderm and entoderm, but they sustain no relation to each other and we would look upon the condition described above as an early indication of the first cleft. On the left side this small ventral furrow is not as definite, the gut here being more evenly expanded. Externally, as previously noted, there is a groove in the ectoderm very similar to that on the right, but everywhere between it and the entoderm there is mesenchyme present. At no point is there any well-defined variation in thickness in either ectoderm or entoderm corresponding with these grooves. The right side is slightly in advance of the left and the same appears to be the case in the two other embryos we have mentioned, No. 391 and No. 1201.

The buccopharyngeal membrane is well defined, measuring about 0.05 mm. from side to side and slightly more from above downwards. The ectoderm and entoderm over this area are in intimate contact; the former shows here a definite increase in thickness over the neighboring ectoderm, while the entoderm is not locally changed, but is distinctly thicker over the floor and side-walls of the pharynx than elsewhere. Externally the membrane lies immediately above the reflections of the somatopleure from the body to form the anterior limit of the pericardial cavity. It occupies the floor and side-walls of a shallow depression, which is continued by a definite furrow over the anterior end of the head into the open neural tube. The membrane seems to be rather widely separated from the first cleft, *i. e.*, the latter appears quite far back on the side of the head, but later development will approximate the two considerably.

In the mid-ventral line, just anterior to the point where the deep ventral trough of the fore-gut begins to widen out, is the primordium of the thyroid. It is a short, well-circumscribed outgrowth from the floor of the pharynx, indicated internally by a very short but well-defined lumen. In the model this outgrowth is located slightly to the right and directed also quite definitely in the same direction. The relation to the first internal pocket has been already noted. The thyroid is here in close relation with that part of the cardiac plexus which will later give rise to the ventral aorta and beginning of the first arch, in practically the same location in which we have described it for a much older stage (1907, p. 548). In No. 391 there seems to be an early thyroid in the same position as regards the heart, but this can not be determined with certainty on account of defects in the sections.

It is unfortunate that no definite statements can be made concerning the chorda, particularly as regards its anterior and posterior extremities. In addition to the unfavorable plane of the sections through the posterior two-thirds of the specimen there is (particularly in front of this) considerable loss of tissue involving

the chordal region and the floor of the neural groove. When these regions are figured the defective tissues have been drawn in, but only for the purpose of completing the illustration. In the very roof of the pharynx, where the plane of sections is obliquely tangential, and so again most unfavorable, there are certain appearances which might be interpreted as indicating the presence of chordal tissue extending almost as far forward as the buccopharyngeal membrane. Elsewhere in the embryo there is a defect, probably more than a simple tear in the sections, involving the floor of neural groove, and also, but to a much greater extent, the roof of the gut-tract. Along this line, both within the gut cavity and externally in the bottom of the neural tube, is a considerable amount of cell detritus, probably largely chordal in origin. This disintegration of the chorda may be due to certain peculiar properties of the tissue. It might further be construed as evidence of a weak connection with the entoderm. Regarding the posterior end of the chorda, nothing whatever can be made out beyond the fusion of ectoderm and entoderm at the primitive node. In general the condition of the chorda is probably much the same as in No. 391, namely, a chordal plate, nowhere entirely free from the entoderm and blending posteriorly with the primitive node.

The allantois is especially well developed in this case, long and regular throughout its course. Its origin from the yolk-sac has already been noted. It enters the body-stalk, lying near what may be termed the caudal border of the stalk and surrounded on the other sides by large anastomosing blood-channels. The lumen is lined by low columnar cells which become more flattened distally, while the caliber gradually increases toward its free, somewhat flattened extremity, which lies very near the tip of the amniotic duct. The length of the allantois is 1.25 mm. and it is everywhere at a considerable distance from the amnion, but its relation to the exocoelom is quite different. Along what we have called the caudal surface of the body-stalk are two prominent longitudinal ridges due to the underlying arteriae umbilicales. Underneath the deep groove thus formed, and situated between the vessels, runs the allantois. Here there is a prolonged area of contact between the mesothelium of the body-stalk and the epithelium of the allantois, about 0.3 mm. in extent or about one-fourth the entire length of the duct (fig. 3). The breadth of contact gradually increases as the distal, slightly dilated portion of the allantois is reached, where several epithelial cells are involved. Nowhere is there any interruption or loss of independence in either the epithelium or mesothelium, neither are there any apparent changes in the two cell-layers. What significance, if any, may attach to this we can not say; at all events it is not of regular occurrence. It may possibly be reminiscent of a larger vascular and functioning allantois, free in the exocoelom.

Immediately dorsal to the origin of the allantois from the yolk-sac, *i. e.*, in the roof of the gut, or yolk-sac, and very close to the caudal limit of the amnion, is the cloacal membrane. It is in a way hardly a membrane, being rather a solid, cylindrical mass of cells, uniting the ectoderm and entoderm, much as in Wilson's embryo H 3 (1914).



As regards the yolk-sac, even approximate dimensions can not be given, on account of the extensive folding which has occurred here. It seems rather larger in the models than in the photographs and is absolutely and relatively larger than in No. 391, or in the Krömer specimen; in the latter the yolk-sac is quite small. Figure 3 shows a short, well-marked diverticulum of the yolk-sac very near the embryo. Its lumen is lined by high columnar cells, the whole knob-like structure projecting into a mass of vascular mesenchyme. If it were shifted forward a fraction of a millimeter into the septum transversum and nearer to the omphalomesenteric veins we would have, not one of the so-called glands or crypts of the yolk-sac, but instead, the very beginning of hepatic development. As it is, one is reminded of the hepatic function ascribed to the epithelial tubules and crypts of the yolk-sac by Graf Spee (1896) and others. All things considered, we think that the umbilical vesicle, so-called, may subservise functions other than those of a purely hæmatopoietic nature (cf. Eternod, 1909, 1913; Jordon, 1910). Very near the diverticulum just mentioned is a smaller, solid outgrowth of the entoderm into the adjacent mesoderm.

#### MESODERM AND CÆLOM, SEGMENTATION.

The mesoderm of the body of the embryo is in the form of two narrow, compact bands, lying between the walls of the neural groove, the surface ectoderm and the entoderm of the yolk-sac. Toward the neural folds it is best defined, its other limits being much less sharp. Laterally it becomes looser and is continued into the mesothelium covering the yolk-sac and amnion, while caudad it passes into the diffuse mesenchyme of the primitive-streak region, where it is continued across the median line. Cephalad these paired mesodermic masses break up to form the scattered mesenchyme of the head and are also very clearly in connection with the thickened pericardial mesothelium as well (text-fig. A). The mesoderm of the body (the two compact bands as above noted) is in the first stages of segmentation. Its mesial border is rather uneven, but exhibits certain very definite, fairly symmetrical, deep indentations which will later separate off, partially at least, the somites of this region.

Near the mesial margin of the mesodermic mass are formed the beginnings of the so-called myocœls, very small or indicated only by the arrangement of the surrounding cells. Of these minute closed cavities there are three on the left side and two on the right, while between them are the indentations just mentioned. There is no indication here of a lateral extension of the myocœls, either to help form, or set up a secondary connection with, the intraembryonic cœlom, as is described by Keibel and Elze (1906) in the case of the second somite in an embryo of 1.38 mm. The embryonic cœlom is, except for the pericardial cavity and the small myocœls just noted, practically non-existent as yet, but a transitory or inconstant connection between it and the cavities of the somites may be established later. We have here, therefore, evidence of three segments on one side and two on the other; of these the middle or second segment on the left is the most distinct. The anterior limits of the first segment on both sides and of the third on the left and the second on the right are very uncertain (figs. 1 and 2).

The segments thus far differentiated lie just in advance of the center of the dorsal concavity and a short distance farther forward the unsegmented mesoderm becomes continuous with the walls of the pericardial cavity. As regards the nervous system, their location would be about the junction of brain and cord and we may look upon them as occipital somites. In the cervical somites which will form later, one may expect a better differentiation and sharper demarcation both between the individual somites and between these and the lateral mesoderm. Aside from the pericardial cavity (described later) and the myocoels, practically the only evidence of the formation of the intraembryonic coelom is found in the presence of a number of small, tubular prolongations of the exocoelom into the lateral mesoderm. They present very much the same appearance as shown by Dandy (1910), but are rather smaller. A few other unconnected spaces occur in the lateral mesoderm, forerunners of the embryonic body-cavity.

#### VASCULAR SYSTEM.

By far the most interesting and important results of the study of this embryo are those which pertain to early phases of vascular development. For the sake of convenience in treatment we may recognize four regions, viz., the chorion, body-stalk, yolk-sac, and embryo, which are also the various regions in which independent blood-vessel formation has occurred, or where this process is still more or less active. As will be seen later, these vascular areas are not only almost entirely independent of each other, but the primitive vessels within these various regions show certain differentiating characters.

#### CHORION.

Blood-vessels are present in large numbers throughout that portion of the vesicle wall which forms a part of the series with the embryo (fig. 3). The remainder of the chorion is also doubtless vascularized, but probably to a somewhat less extent. In the villi vessels are abundant as slender anastomosing channels or cords, continuous with the deeper vessels of the chorionic wall, presenting the picture of a loose, wide-meshed plexus. While for the most part forming a continuous network, there are certainly many detached strands, although, in view of the beginning abnormal cytological changes, which are more marked here than anywhere else in the specimen, this condition need not be looked upon as representing the usual method of development. The general swelling of the stroma in many of the villi may be in some measure responsible for the presence of what appear to be solid cords of cells rather than open vessels, although the latter do occur, often quite small but not infrequently of considerable size, particularly near the bases of the larger villi.

In the chorion proper, vascular channels are much more numerous and well defined, while the stroma is in a practically normal condition. The vascular picture here is in marked contrast with that in the villi, or indeed with that of all other parts of the ovum. There exists a rich plexus of vessels occupying the entire thickness of vesicle wall. They have in general an arrangement parallel with the surface and vary considerably in caliber. In contradistinction to the vessels in the villi

those in the chorion are widely open, even though many of them are very small. That a few of them might be solid can not be excluded, but the appearance in all cases is rather an extremely fine lumen or simply an approximation of the walls. A second and quite conspicuous distinction in these vessels is their relatively thick walls, due to the increase in number and greater condensation of the cytoplasmic processes immediately around them, so that the vessels, aside from their lumina, are quite prominent features in a section through the vesicle wall. Near the attachment of the embryo these vessels are larger and rather more numerous and have already established a slender connection with the vascular channels in the body-stalk. Formed elements are found, with certainty, nowhere in the chorionic vessels except in the immediate neighborhood of the body-stalk. They are present here only in very small numbers, having made their way upward from the larger vessels farther down in the stalk. Hofbauer cells are occasionally present in the villi and abundant in the chorion, particularly near the attachment of the embryo.

#### BODY-STALK.

It is in the body-stalk that vascular channels show their greatest development at this stage, where, as has been previously mentioned, they are largely responsible for the size and shape of this structure (figs. 3 and 4).

About the level of the origin of the allantois, we may place the lower or embryonic extremity of the two umbilical arteries; that is, the limit of those portions of the arteries which are formed earlier than the part upon the yolk-sac, and *in loco* within the body-stalk. The vessel on the left extends to a slightly lower level than that on the right and is in addition distinctly larger, although in both cases the arteries end quite abruptly instead of running out gradually as one or more smaller channels. For a very short distance these arteries are represented by spaces in the mesenchyme, devoid of a definite endothelial coat, but containing each a well-marked blood island connected with the surrounding stroma by numerous cytoplasmic processes. A recognizable limit between a definite vessel and the apparently neutral mesenchyme is entirely absent, although the transition is to some extent bridged by the presence of blood islands. Followed distally, the left artery rapidly acquires a definite coat, although its lumen is yet almost entirely filled by a large, rather compact blood island attached to the walls by numerous cytoplasmic strands (fig. 9). Blood-islands have been noted in the body-stalk on many occasions, as by Debeyre (1912), Grosser (1913), and Bremer (1914). In our embryo they resemble the blood-islands of the yolk-sac much more than those of the body-stalk described by the investigators just mentioned, at least as far as we can make out from their descriptions or illustrations.

The right artery is not only much smaller at first, but on the side toward the embryo its endothelial wall is deficient for a short distance, where its lumen becomes continuous with an extensive, irregular, but not definitely lined space, by means of which an open connection is established between the artery and the posterior part of the vitelline plexus (fig. 10). This channel can be traced forward and inward through the wall of the yolk-sac and splanchnopleure until, as a much smaller but

more definitely lined vessel, it becomes continuous with the small offshoot from the right aorta, the first vitelline (umbilical) artery. On the left side we can make out no connection between the umbilical artery and the vitelline plexus, although the latter shows much the same condition as on the right side except for the communication with the artery. There may well be some exchange of fluid through the loose tissue on the left side, but the more open anastomosis on the right may help explain the smaller size of the artery on this side, since a free flow to or from the yolk-sac is possible.

Traced away from the embryo, the blood-islands in the umbilical arteries gradually become smaller and looser, their connections with the vessel-walls grow less conspicuous, while the individual elements become rounded and more distinct and also fewer in number until both vessels are entirely empty. These early blood-cells, where they are not especially numerous, are attached to the anterior wall of the vessel, *i. e.*, on the side toward the embryo. In this location the wall is often less sharply defined than where there are no blood-cells forming, although such cells may be connected with a perfectly definite vessel-wall.

Both arteries present, low down, a few very short branches which are usually much less distinctly lined than the main vessels. A little farther from the embryo a number of ventral branches are found which anastomose and increase in size until there is formed a plexus of large, irregular vessels entirely filling the body-stalk between the amnion in front and the umbilical arteries and allantois behind. Distal to the giving off of these branches, the arteries are somewhat reduced and also more nearly equal in size. They become, however, progressively larger, especially the left, but give off very few branches until, near the free end of the allantois, they rapidly lose their identity by extensive anastomoses with the venous plexus in front. Small, scattered masses of blood-cells are found in both arteries, being more numerous in the left. At the very distal extremity of the left artery, in the channels which connect it with the ventral plexus, there is again blood-island formation. The right artery, although it has many connections with the plexus, can be followed farther toward the chorion than the left.

Ventral to the umbilical arteries and the allantois which courses between them lies the dense, irregular vascular plexus referred to above. Beginning low down in the body-stalk, where it is connected with the arteries, it increases rapidly in size and complexity and at a higher level has incorporated in it the two arteries. Beyond this point of union the plexus dwindles very markedly, so that the distal portion of the body-stalk is occupied by but a few small vessels, through which a narrow connection is set up with the vessels in the chorion. The walls of the plexus are not always as sharply defined as in the arteries, being also distinctly thinner and much less conspicuous. Small anastomosing channels, offshoots from the plexus, are especially in evidence immediately around the allantois. Blood-cells are present to about the same extent as in the arteries. No direct connections exist between the plexus (the future umbilical veins) and either the yolk-sac or the beginning umbilical veins which form in the body of the embryo. This latter communication

doubtless forms at a slightly more advanced stage. It is at the chorionic end of the body-stalk that the greatest transformation would be required to bring about separate arterial and venous channels, instead of the single set of vessels which occupies this location at present.

The stroma of the body-stalk varies somewhat in different localities. It is densest and most cellular close to the embryo; at a little distance its cellular content becomes much less marked, while the cytoplasmic reticulum is very conspicuous. Along the posterior border, near the allantois and the umbilical arteries, this tissue is always much less rich in nuclei than around the plexus in front. Often the wide space between the arteries, allantois, and the investing mesothelium is bridged by a very delicate network of cytodesmata almost devoid of nuclei. At the smaller, chorionic end of the stalk, where the venous plexus is running out, the stroma gradually loses its delicate reticular appearance, becomes denser, and assumes a more fibrous aspect much like the mesoderm of the chorionic wall. The vessels in this part of the stalk, which establish the slender and circuitous connection between the plexus and the chorionic vessels, are quite small and thick-walled, and so in both respects more like those of the chorion than those of the body-stalk. They may be looked upon, therefore, as ingrowths from the chorion to meet the independently formed vessels of the stalk. Over the distal part of the body-stalk the mesothelial investment is gradually lost, and in fact close to its attachment to the chorion the limits of the stalk fade almost imperceptibly into the adjacent coagulum in the exocoelom. From the mesothelium there are found short, tubular or funnel-shaped ingrowths, but these are few in number and have no relation to the underlying vessels.

#### YOLK-SAC.

On account of the extreme distortion of the yolk-sac, due to folding and partial collapse, it is not always possible to locate exactly many of the vascular rudiments. Blood-islands are most numerous in the region of the fundus and are also scattered sparsely over the remainder of the vesicle, being rather more frequent laterally and posteriorly, while a few are found quite close to the embryo. Vessels in various stages of development are most conspicuous in these same areas, but no special attempt has been made to trace them or to determine their relations more definitely. On what appears to be the posterior surface of the sac, there are a considerable number of large, well-defined channels which are not even remotely connected by open vessels with those close to the embryo. As the embryo is approached, all the vascular features become less frequent, more scattered, and more difficult to recognize, especially lateral to the anterior part of the embryo. Any connection between the vessels or heart of the embryo and those of the adjacent yolk-sac anteriorly by way of the vitelline (omphalomesenteric) veins is at best very attenuated and indirect; a continuous, open endothelium-lined path is not present; for, whatever interchange of fluids may be going on between the embryo and yolk-sac in this region, there are no corresponding morphological features to be recognized.

Posteriorly, however, nearer the attachment of the body-stalk, conditions prevail which may be described as a vitelline plexus (fig. 4), much better developed

here than farther forward. This plexus is made up of short, open endothelial channels, solid cords, scattered angiocytes, and occasional small blood-islands, with the better-developed vessels exhibiting a tendency to assume a course at right angles to the axis of the embryo. It is impossible to determine the extent to which these various vascular primordia may be united at this stage to form a more or less continuous network. Conditions here are more like the "rete periintestinale" of Felix (1910) than those shown by Bremer (1912) in the rabbit. The posterior and mesial limit of the vitelline plexus on the right side is formed by a large, fairly definite channel, for the most part quite unconnected with the general plexus in front of and lateral to it. Near its origin on the yolk-sac it exhibits a small, patent, but not yet definitely walled communication with the umbilical artery in the body-stalk. Traced inward and forward in the splanchnopleure it becomes progressively larger, its proximal portion being a distinct endothelium-lined tube. It possesses here a few short sprouts and then, considerably reduced in size, turns inward to join what seems to be the posterior end of the dorsal aorta (fig. 4). Just where it passes inward to meet the aorta, a small branch runs forward which is apparently destined to establish a second, more anterior connection between the aorta and vitelline plexus. Both the aortic and the vitelline ends of this latter vessel are in evidence, but the intervening portion is rather problematical, at best a slender cellular connection. We have here a nascent vitelline artery, the second of the series of roots of the future umbilical artery. On the left side no indication can be discovered of any connection between the aorta and the plexus. There is, however, a well-marked blood-channel already laid down on the periphery of the plexus, but still lacking its connections with the aorta in front and the body-stalk behind. At the aortic end a communication may be in process of formation by means of single cells, but the line of section is much less favorable for determining this than on the right side.

As just noted, the anterior part of the vitelline plexus is much less developed than the posterior. A connection between the former, the radicles of the vitelline or omphalomesenteric veins, and the proximal portion of the vein as it lies in the septum transversum, is either absent or so small as to escape detection. If there is an interruption it occurs just at the lateral border of the embryonic body. Substantially the same conditions are present on both sides. If not already present there will be established here very soon a second connection between the intra-embryonic and extraembryonic vessels, in this case by way of the venous end of the heart. Apparently the posterior (aortic) connection antedates the anterior or omphalomesenteric union.

#### HEART AND EMBRYONIC VESSELS.

In considering the cardiac plexus (figs. 4, 7, and 8) we may begin with the omphalomesenteric roots, single on either side, beginning in the septum transversum near the lateral border of the embryo. Passing inward and forward through the septum, beneath the dorsal recesses, they turn cephalad under cover of the myoepericardial mantle and unite with each other to form a single median mass. Of the two vessels, without regard to their structure, whether hollow or otherwise, the left is rather larger than the right. Small where they may be called the omphalomesen-

teric veins, and again where they unite in the median line, they are in the interval of a plexiform nature, slightly more open on the right, and dip down on both sides as far as the lowest limit of the myoepicardial mantle. Two small cross anastomoses are present between these caudal halves of the heart plexus. About its middle and for a short extent the plexus is essentially a single median mass, fairly uniform and irregularly stellate or crescentic in section. Cephalad it broadens out rapidly, becomes more complicated and very markedly plexiform, while its constituent elements again assume a roughly symmetrical, bilateral arrangement. At the same time it begins to extend around onto the lateral surface of the pharynx. At the level of the thyroid, high up under the mantle, the cardiac mass breaks up into two roughly symmetrical portions (the right more markedly plexiform) which pass cephalad and dorsad over the ventro-lateral surfaces of the pharynx and rapidly run out on either side on the roof of the fore-gut near its lateral margins. These structures represent the first two aortic arches and are perfectly definite endothelium-lined channels. They cross the lateral wall of the pharynx some distance in front of what we have called the first entodermic pocket, about midway between this and the buccopharyngeal membrane. At their plexiform origins both arches are sharply limited endothelial channels lying close to the pharyngeal entoderm. From the anterior convexity of the course described by these vessels there is given off a short sprout, the beginning of the internal carotid. Beyond the origin of the carotid the dorsal aortæ can be traced for only a very short distance, when they fade out in the aortic grooves on the roof of the fore-gut in the region dorsal to the first pocket. There are no indications of a second arch unless one chooses to put such an interpretation upon certain irregularities found along the lateral border of the plexus in its anterior third and at the base of the first arch.

Concerning the structure of the heart plexus (text-figure A and fig. 11) a few words are necessary, since the reconstructions give no adequate expression of its essential characters. Only the lateral extremities of the omphalomesenteric veins and the anterior, bifurcated end of the plexus, where the first arches take origin, are genuine endothelium-lined vessels. Between these points the heart is represented by a very irregular, cellular mass, roughly crescentic in section, its concavity directed backward toward the fore-gut. The illustrations do not bring out fully the great irregularity in the surface of this mass, since it has not been possible to reproduce the numberless cell processes with which it is thickly studded. The entire cardiac plexus is extensively vacuolated, the cavities being for the most part separate. Toward the arterial end of the heart these spaces become more frequent, larger, and more often confluent. There is in this stage a freer pathway for diffusion currents outside the plexus, in the wide space underneath the mantle, than there is within the plexus itself, only the two extreme ends of which are pervious. A certain similarity obtains between conditions represented here and those shown by Parker (1915, plate I, fig. 5) in a 15-16 somite embryo of *Perameles nasuta*, but only as regards the general form of the heart, since the vascular development at this stage in *Perameles* is comparatively very far advanced. In her text-figure 14 the heart in cross-section is quite like that of our embryo, except that it presents

two separate endothelial tubes instead of a single angiocystic mass. One may conclude that in man the two halves of the heart fuse at a very early period in their development, if there is actually a stage in which they are two such independent structures. It is conceivable that in the heart before us we might later have found two quite independent endothelial tubes, but the probability seems very remote. In man fusion antedates the complete canalization of the heart, while in most forms the reverse is the case (Parker, l. c.; Bremer, 1912; Schulte, 1916; Wang, 1918).

As regards the actual processes which give rise to the lumen of the heart, the same principles obtain in man as have been described in the cat by Schulte (l. c.). Compared with endothelium formation elsewhere, there is in the heart a relatively large amount of mesenchyme and very little endothelium. We can find nothing indicative of the origin of this mesenchyme or of its being increased in amount except by its own proliferation. It is everywhere at a considerable distance from the myoepericardial mantle, but its most caudal extensions lie very close to the entoderm. The entire heart has obviously arisen *in loco* and not by the invasion of vasculogenic elements from without. It is not possible to say to what extent the heart, as shown in figures 7 and 8, is to be derived from a single paired or even unpaired primordium by a simple process of growth; there has doubtless been not a little accretion of angioblastic material, and this probably more extensive at the cephalic end than elsewhere. The continued formation of angiocysts, their extension and coalescence, will soon transform the impervious mass as it now exists into an open passage between the omphalomesenteric veins and the first aortic arches. By this time we might expect to find a free communication between the venous end of the heart and the anterior part of the vitelline plexus and also a dorsal aorta continuous and patent throughout its extent.

Posterior to the first pocket the dorsal aortae are in process of formation, as evidenced by the presence of a number of small vesicles, or even less definitely limited spaces, in the rather dense mesenchyme close to the roof of the fore-gut. About opposite the intestinal portal the right aorta gradually becomes more evident and can be traced backward, lying close to the entoderm, as far as or possibly a little beyond the point where it has its lateral connection with the posterior portion of the vitelline plexus, and thence with the artery of the body-stalk (fig. 4). Toward its posterior end the aorta is distinctly dilated and there is here a possible second, more anterior vitelline artery in process of formation. Anterior to this dilation is a small, much constricted, but probably pervious segment of the vessel. From the intestinal portal to the vitelline artery the aorta is for the most part a definitely lined channel; the constriction just noted may possibly be solid, and also near the origin of the vitelline artery its walls are, in a few places, almost deficient. Whether its posterior end is open or really closed off is very difficult to determine. Beyond the latter point a few scattered but conspicuous cells are found, quite different from the other cells near them, especially as regards their larger, longer, and more deeply staining processes. They are to be looked upon as material for the further growth and extension of the aorta or its branches. Situated in the line of the aorta and laterally toward the yolk-sac, these cells show the orientation described for similar



cells in the cat by Schulte (1914), forecasting, as it were, the long series of vitelline arteries which is to follow. There are in addition, also at the posterior end of the aorta, indications of a very few short, mesially directed branches, not always closed off from the wide intercellular spaces adjoining, which represent the first dorsal rami of the aorta. The exact location of the vitelline artery can not be determined; continuing the segments backward would place it about the region of the sixth, the future third cervical. Felix places the anterior connection with the aorta at the seventh segment, in the stage of 5-6 somites, while in a 2.6 mm. embryo with 13-14 somites this connection has shifted back to the tenth segment on the right side and beyond the twelfth on the left.

On the left side certain minor differences are to be observed. In the region of the somites the aorta is larger than on the right. This is followed by a short stretch where the vessel is possibly interrupted but represented, at least in part, by a solid chain of large cells. Its posterior end is enlarged like that on the right, but, instead of being open, is occupied by a small blood island (fig. 12). The conditions here must be essentially the same as those described by Miller and McWhorter in the chick (1914), where the posterior third of the aorta on the operated side is represented by an elongated, cord-like blood island, whose cells "are identical with the cells in the blood islands of the normal area opaca" (l. c., p. 209). In this particular case, as well as in our own, the diffusion, not to mention any circulation, must be extremely tardy in this solid vessel. With the establishment of even very slender connections, such as are present on the opposite side in both embryos, and the ensuing rise in the rate of fluid interchange, we may expect a certain change in the appearance of the blood islands such as are found in the umbilical veins of our own embryo, or their gradual disappearance as well. The only formed elements which we have found in the embryonic vessels, aside from the blood island just noted, are a few cells in the caudal portion of the right aorta, both conditions recalling the cell clusters described in this vessel at much later stages in other animals (Emmel, 1916; Jordan, 1917). As regards branches on the left side, very little can be made out. The same angioblastic cells are present as on the right side, but they are rather less conspicuous. If there is a vitelline artery already laid down here it is very indefinite and located at the caudal end of the aorta in the region occupied by the blood island. Both aortæ lie very close to the entoderm; the wide space intervening between these vessels and the mesoderm is bridged by great numbers of cell processes of varying size and shape and is also comparatively free from nuclei. This space is rather wider than that between the mesoderm and ectoderm. The surface of the mesodermic mass toward the entoderm is much more irregular and there are more isolated mesenchymal elements here than underneath the ectoderm. From the mesoderm there are undoubtedly many cells migrating out, where they may very easily come into intimate relation with the aorta or assist in forming some of its first branches (Schulte, 1914).

It is not only in the splanchnopleure that vasculogenesis is in progress, but also, although to a much less extent, in the somatopleure as well. There is to be found on the somatopleure on the left side, very near its reflection to form the amnion, a

very definitely lined, thin-walled vessel—the left umbilical vein (figs. 2 and 6). It is of considerable antero-posterior extent and in its cephalic portion is a very sharply defined channel, but with extremely thin walls. At this end it runs out as a solid spindle-shaped sprout in a region almost devoid of cells. Its posterior extremity is gradually lost in the loose mesenchyme under the ectoderm. The vein presents two or three mesial branches, more distinct in front, through which a connection will be set up with the earlier formed omphalomesenteric root of the heart, the vitello-umbilical vein. Conditions on the right side are too uncertain to warrant description. On both sides, however, there occur, farther back, scattered vasoformative cells and small angioblasts in the somatopleure, or even in the amnion close by, marking out the course of the umbilical vein backward toward the body-stalk. At present, however, the embryonic part of the umbilical vein is entirely isolated and independent. A few short branches come off the venous plexus of the body-stalk at its lower ends; these are more conspicuous on the right side and may aid later in completing the afferent umbilical channel.

#### MYOEPICARDIAL MANTLE AND PERICARDIAL CÆLUM.

The pericardial cavity and myoepicardial mantle, the latter with its contained plexiform heart already described, are of particular interest at this stage (text-figure A, and figs. 5, 6, and 11). In transverse section the cavity throughout is crescentic in outline and corresponds, in its antero-posterior extent, quite closely with that of the fore-gut. The floor of the cavity is concave, narrow, and roughened internally by a number of small, radiating ridges in the thickened mesothelium. The cephalic limits of the cavity project upward as two narrow slits on either side of the fore-gut (or mouth) lateral to the buccopharyngeal membrane. Similar diverticula of the pericardial cavity have been noted in a 4.9 mm. embryo (Ingalls, 1907, l. c., p. 553). The recess on the right side is somewhat more extensive, terminating in three finger-like prolongations. As the dorsal wall of the cavity we may describe the region about the two extremities or horns of the crescent which the cavity presents on section. Cephalad this is nothing more than the bottom of a narrow cleft between the splanchnic mesoderm (myoepicardial mantle) and the somatopleure. Farther back this cleft gradually widens out, especially on the right side, due in part to the narrowing of the mesocardium—a sort of undermining.

This increase in width continues to a point about opposite the slight constriction which can be seen in the myoepicardial mantle. Just below, *i. e.*, posterior to this, there is a sudden increase in the transverse dimensions of the cavity, due to the presence at this level of two deep, well-marked, dorsally or dorso-caudally directed, roughly funnel-shaped diverticula which penetrate for some distance into the mass of mesoderm which farther back is beginning to break up into segments. These diverticula take origin from the widest part of the pericardial cœlum and moreover close to its lateral wall on either side. Mesially they are in relation with, or even extend dorsally beyond, the dorso-lateral grooves of the fore-gut. Of the outpocketings just noted (*recessus parietales dorsales*) the right is better defined and more extensive in all its measurements, and is possibly situated a trifle more cephalad than the left. As far as can be determined they are yet blind, having

effected no connection with the coelom elsewhere, although we can not deny the possibility of such a connection on the left side. From the deepest point of the recess on the left side there extends backward for a short distance into the paraxial mesoderm (that is, into a region definitely lateral to that in which more caudally the myocoels are to be found) a very slender cleft which possibly, at its posterior end, is in relation with some of the coelomic spaces already noted (p. 56) as ingrowths, in part at least, from the extra-embryonic coelom. A second less notable cleft appears at a level slightly more caudad. On the right side essentially the same picture is presented as described above, except that the smaller, more caudal extension is missing. As may be seen, the dorsal recesses are much nearer the floor than the roof of the pericardial cavity; later this relation is reversed. However, it may be noted in passing that the upper part of the pericardial cavity is in relation with vessels which will later come to lie without this cavity, viz., the aortic arches. Under the inner, mesial wall of these recesses lie the dorso-lateral grooves of the fore-gut as previously noted; the future pulmonary anlage is more ventral and possibly also farther cephalad. Anteriorly they are roofed in by the somatopleure near its reflection to form the amnion. Their floor below is splanchnopleure, which mesially and ventrally forms a sort of sling, constituting the floor of the pericardial cavity, the whole being the septum transversum, around the dorsal border of which, at the anterior intestinal portal, the fore-gut and mid-gut communicate.

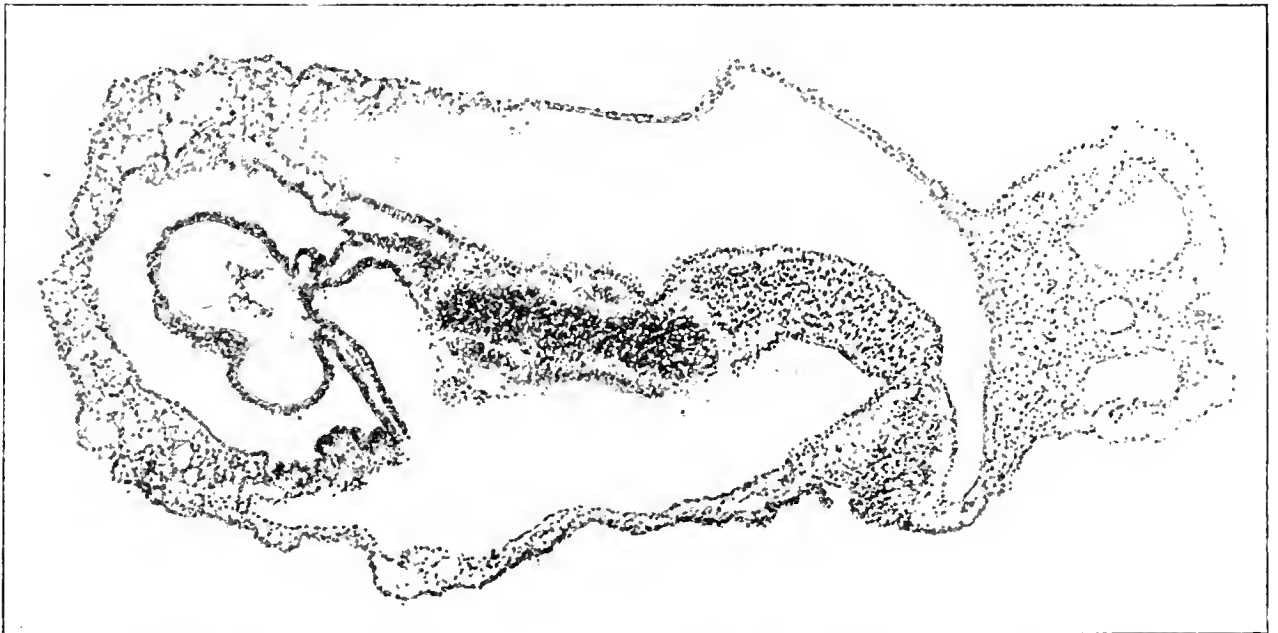


FIGURE A. Section 12-3-6,  $\times 90$ . The line of this section is shown in figure 3 on plate 2. Transversely the plane of section is somewhat oblique, so that structures on the left of the median line (above in the illustration) are cut at a higher level than those on the right. The section cuts just behind the primitive node, through the anterior intestinal portal and approximately, though obliquely, through the middle of the heart. On the right in the figure appears the body-stalk with the two umbilical veins and allantois between them. Three cavities are seen: above in the illustration is the amniotic cavity; below is the yolk-sac, communicating anteriorly with the foregut; farther forward, in the median line, is the pericardial coelom with its contained heart. The central, densely cellular mass is a tangential section of the left neural fold. Between the ectoderm of the foregut and the superficial ectoderm, the mesoderm can be traced forward to the point where it splits to become continuous with the visceral and parietal layers of the pericardial cavity. (Cf. also text and fig. 11, plate 5.)

Into the pericardial cavity, and indeed determining its shape although by no means filling it, projects the myoepicardial mantle. Its ventral and lateral surfaces are free; above and below it is reflected back as the parietal mesothelium, while dorsally this same reflection constitutes the posterior mesocardium. The two layers of the mesocardium are, however, widely separated, for between them lies the ventral keel of the fore-gut, even beyond what may be considered as the ventral limits of the mesocardium, while farther cephalad is the bulging floor of the pharynx. In the region of the dorsal recesses the two layers of mesocardium are most closely approximated but still separated by the fore-gut. It is this undermining which will soon free the heart except at its two ends, the communication thus established between the two sides persisting as the transverse sinus of the pericardium.

The myoepicardial mantle or, to be brief but less exact, the heart, is practically straight and of almost uniform width, but slightly broader below; its ventral, free surface is distinctly convex antero-posteriorly, as well as from side to side. This ventral surface is rather more strongly convex below than above, and again along its left margin, and passes insensibly into the lateral surfaces. Of these the left is the simpler, presenting caudally and dorsally a slight bulging due to the undermining just dorsal to it. The right side is throughout more strongly convex and is traversed about its middle by a deep transverse furrow below which the heart is distinctly thinner dorso-ventrally. The ventral end of this furrow is continuous with a much shallower, broader groove which passes caudad and slightly mesad over the ventral surface of the heart. The deep furrow on the right, together with a much more diffuse but roughly corresponding depression on the left, brings about a slight constriction of the heart about or a little below the middle. This constriction corresponds approximately to the anterior part of the narrowest portion of the cardiac plexus. The relief of the right side of the heart is in marked contrast with that on the left, in that the former shows a well-marked bulging above the transverse groove, while below this groove is a small, but very distinct, shoulder-like prominence. On the left side is a slight prominence anteriorly which is separated by a gentle concavity from a more pronounced elevation at the caudal end of the heart. It must be remembered that what we have just described as the heart—namely, the myoepicardial mantle—particularly the very anterior end of it, has its form determined far more by the pharynx beneath it than by the vascular primordia within. To what extent the form of the mantle and its external relief are influenced at this stage by the structures beneath is a question, but it would seem that the development of the mantle is in advance of the endothelial elements within, and so, in a measure, independent of them. Further, there are found here not only the future heart, but also the ventral aorta and the beginning of the first arches.

In a structure relatively so short and really comprising at one end less and at the other end more than the future heart, one can not expect to find much indication of the later differentiation of the tubular heart. The moderate constriction in the mantle described above really does not involve the ventral surface of the heart. If we identify the deep incisure on the right side as the beginning bulbo-ventricular groove, then, but only as regards the mantle, the atrial and descending portions of

the ventricular loop are conspicuously shorter than the remainder from which will arise the ascending limb of the loop and the bulbus. This prominent shoulder on the right is very similar to that shown in cat embryos (Schulte, 1906), except that here, due to the late fusion of the mantles, the same prominence with the bulbo-ventricular groove above is formed on both sides, in each half of the myoepicardial mantle. In the heart of No. 391 (2 mm.) as shown by Mall (1912), the groove is farther from the attached, venous end of the heart and is, moreover, in its proper position on the *left* side. Were the relations of the early endothelial tube within more in accord with the form of the mantle one would feel less compunction in hanging on this little projecture on the right side of the heart speculations *à propos* of an incipient dextrocardia or situs inversus, without, however, being able to offer much more to substantiate such a claim, or anything by way of explanation.

Careful examination of the myocardial wall fails to reveal anything which might be construed as distortion or post-mortem change of any kind. In the region of the groove there is a slight thickening of the mantle and its free, cœlomic surface is distinctly more irregular than elsewhere from the heaping up of its cells. At the dorsal end of the bulbo-ventricular groove is a deep triangular depression continued forward and backward along the line of the mesocardium. On the left side the undermining of the mantle is well marked only in its caudal half, the deepest point being distinctly below, caudad to the center of the mantle. The establishment of a connection here across the median line, the future transverse sinus of the pericardium, awaits only the withdrawal of the ventral keel of the fore-gut. This pushing inward of the mesocardium at a definitely more caudal point on the left side (on the right this process is more extensive but also more anterior), together with the deep groove on the right side and the fact that the ventral, transverse convexity of the mantle is sharpest toward the left side of this surface, leads one to the conclusion that there is developing in this case a reversed ventricular loop—that is, a loop directed toward the left instead of toward the right. Another bit of evidence which might be adduced in this connection is the fact that the right lateral border of the cardiac plexus is more concave than the left, while the median fused portion of the plexus shows a very definite keel, directed ventrally and to the left. This last-mentioned character is most noticeable on section, as if the endothelial structures were reaching out toward the left, anticipating the formation of a ventricular loop whose apex will be directed toward that side.

As regards the relations of the myoepicardial mantle and its inclosed plexus, the evidence here also points to a beginning reversed ventricular loop. The shallow sagittal groove already noted on the ventral surface of the mantle in its caudal third is situated slightly to the right of the open space between the omphalomesenteric roots; in other words, it overlies the left border of the expanded portion of the right venous root. This sagittal groove is located to the right of the median line. Traced upward, it turns outward, toward the right, to become continuous with the ventral end of the bulbo-ventricular groove. This shallow, sagittal furrow will probably later be completely effaced, since we can hardly see that it might represent the atrio-ventricular constriction. Whether or not it is an indication of a possi-

ble earlier and greater independence of the two halves of the mantle, which appears doubtful, must remain for the present an open question. At the point where the grooves become confluent they are situated to the right of the plexus, so that the shoulder on the right is quite out of relation with the plexus, containing only the fine fibrillar network to be described later. On the whole, then, the endothelial component of the heart is shifted a little toward the left within the mantle, besides showing a slight but definite bowing toward the same side. While obviously the plexus must follow the bending of the tubular mantle, made possible by the early breaking through of the mesocardium, there is nothing at present to prevent the plexus from undergoing considerable changes in position within, and independent of, the mantle. All things considered, one can not well avoid the conclusion that we have before us about the earliest recognizable stage of dextrocardia, infrequent enough in the adult, to which might have been added later a more or less complete *situs inversus viscerum*.

The apparently low, caudal location of the bulbo-ventricular groove is to be explained by conditions under the upper part of the mantle. There is found here, yet in relation with the pericardial cavity, the anterior, most obviously plexiform segment of the so-called heart plexus, which represents, however, the ventral aorta, first arches, and very possibly other aortic arches (Bremer, 1912), as well as the distal extremity of the bulbus. This portion of the mantle is also much thinner than that farther back, where it will form the wall of the ventricular loop, and the protoplasmic network is distinctly less delicate and regular.

As regards the future subdivisions of the endothelial portion of the heart at this stage, little more than their obvious spatial sequence can be recognized. In its caudal, expanded third is represented the sinus venosus, the wide transverse extent of which is already an accomplished fact. There remains only the complete fusion of its two lateral components, already inaugurated by two small connecting channels. The anterior third of the endothelial heart is frankly a plexus, the distal portion of which is made up of bilaterally arranged, open endothelium-lined vessels. From this segment must be derived the termination of the bulbus, the ventral aorta, and the anterior aortic arches. The remaining unpaired middle third of the heart plexus contains, therefore, the bulk of the future organ, aside from the mantle. Any definite limits can not be given, but in the formation of the ventricular loop which will arise from its rapid growth and elongation, it seems probable that the caudal third of the plexus will be encroached upon more and drawn into the ventricular loop, as atrium, to a greater extent than the anterior third will be incorporated into the bulbus.

Between the myoepicardial mantle and the endocardial primordium within, there exists a wide space which is more extensive and characteristic in the ventral and lateral regions than in the region dorsal to the heart plexus (text-figure A and fig. 11). This interval is bridged over by innumerable fine protoplasmic fibers which have their origin, or attachment, on the mantle externally and the surface of the plexus internally. They were described long ago by His, and more recently by Mall (1912), and there can be no doubt but that they represent an essential and perfectly normal constituent of the embryonic heart. It may be granted, of course,

that their appearance and arrangement may be altered in a variety of ways by reagents or post-mortem changes. The extent and importance of these intercellular and interepithelial connections of early development (the cytodesmata) may be seen from the detailed accounts of Szily (1904, 1908) and Held (1909). Taken en masse, as they are found throughout the embryo, they make up the mesostroma of Studnička (1911, 1912). Aside from their obvious office of retaining the early cell masses and layers in proper order and arrangement (Szily), they would also afford adequate means for the necessary diffusion of fluids at this stage, while later they may play an important rôle in connection with developing nerve paths (Held).

The embryonic heart offers an example of the special development of the cytodesmata just mentioned. In the particular case in question their arrangement is essentially radial, extending from the future endothelial tube within to the under surface of the mantle externally, and also, but to a slightly less extent, to the ventral wall of the fore-gut behind. As a rule, the course described by the fibrils is rather wavy and irregular, often simulating a loose, much drawn out reticulum, and they show a distinct tendency to clump together, especially internally, where they spring from the various prominences and ridges of the plexus. That they exert any traction upon the nascent endothelium, or later upon the heart tube, drawing them out at divers points as has been suggested, is altogether possible, but appears to us unlikely. Often between the fibrils there occur regular, open spaces, possibly to some extent of the nature of artefacts, and where there are cells in close relation with them they may simulate angiocysts. Identical conditions are figured by Szily in the chick heart (i. e., 1908, figs. 5 and 8). A large space of this kind is found quite constantly in the dorsal concavity of the plexus, between it and the fore-gut. The great development of such a protoplasmic, intercellular network between the myocardial and endocardial layers of the heart wall is doubtless to be looked upon as a preparatory feature, facilitating or initiating the later invasion of the space thus occupied by the ventricular myocardium on the one hand and, on the other, by the endothelium at various points in the formation of the endocardial cushions and other connective tissue of endothelial origin. Toward the anterior limits of the myoendocardial space the characteristic arrangement of the fibrils is gradually obscured; they become more irregular, less numerous, and the whole picture is that of a coarser, less orderly framework, until it finally becomes indistinguishable from the ordinary mesostroma of the neighboring somatopleure. The arrangement of the reticulum in the heart under consideration is quite different from that shown by Szily (i. e., 1904) in the heart of chick embryos, where the network is looser and the fibrils are arranged without any special regularity, no predominantly radial disposition being in evidence. Similar differences are obvious in the section through the heart of a 15-somite human embryo as given by Tandler (1912). Here, although it is of a much later stage, the network, as in the chick, has about as indefinite an arrangement as could be desired. The nearest approach to the conditions present in our case are those shown by the former writer, but taken from the bulbus cordis of a 32-hour chick embryo (i. e., 1908, figs. 5 and 6).

The inner basal surface of the mantle, to which are attached the fibrils, is remarkably smooth and even, more so in fact than the same surface on any of the

other cell-layers of the embryo except the medullary folds and otic plates. Closer examination of this surface, however, reveals a fine crenation of the edge on section, representing the points of union between the fibrils and the mesothelial cells of which they constitute a part (cf. Szily, l. c., 1908, fig. 6). Anteriorly, where the fibrillar network loses its delicate, uniform characters, the under surface of the mantle suffers in a similar way, becoming very irregular and uneven. The variations in the nature of the mesostroma in different regions of the embryo are essentially quantitative in character. All conceivable gradations are represented, as may be seen in the examples furnished by Szily. Free cells or small cell-masses in the reticulum are practically restricted to the anterior third of the plexus, and here again they are more in evidence around the caudal limits of the plexus, where considerable remodeling will take place, than farther forward where definite blood-vessels represent the beginning of the first arches.

The free, coelomic surface of the mantle is relatively rough and uneven; the cells are frequently clumped together in small (at times hollow) masses projecting into the pericardial cavity. The mantle is thickest behind and gradually thins out to the line of reflection as the parietal layer at the top of the pericardial cavity. Details of its structure can not be made out; in its anterior portion there is but a single layer of cells; elsewhere and particularly low down there may be more than one. Nowhere, however, is there any break in the clear-cut basal surface of the mantle or any indication on the part of its cells of an invasion of the underlying reticulum. The parietal layer of the pericardial mesothelium is a single layer throughout. Thinnest ventrally, it becomes thicker over the lateral walls, while dorsally and where it forms the mesocardium its cells are cuboidal or low columnar in type. In the dorsal recesses, where they are expanded to join the general pericardial cavity, their walls exhibit considerable irregularity in the form of deep, narrow clefts or tiny outpocketings lined by low columnar cells.

A consideration of the vascular features presented by this particular example of early human development confirms one in the idea that the ability of the mesoderm to give rise to vascular endothelium, at least at certain stages and in man, is practically coextensive with the limits of this category of embryonic cells, indicating a certain catholicity in this respect. As regards free blood-cells, the case is apparently somewhat different. There are, as previously noted, four separate regions in which blood-vessels arise; their connections are secondary, being established at various times and in a number of different places. These regions are the chorion, body-stalk, yolk-sac, and embryo. To these might be added the amnion, unless one draws the line between this membrane and the somatopleure so as to leave all the vasofactive material, such as the angioecysts of the umbilical line, well within the embryonic body. The sites of blood-cell formation are most widely distributed in the yolk-sac, while in the body of the embryo they seem to be very sharply restricted (aorta). (Closer phylogenetic relation of the dorsal aorta with the vitelline plexus.) In the chorion there are, at present, no indications of the production of formed blood elements.



In the body-stalk and chorion the process of vessel formation, by accretion and accessions from without, may already have been superseded by the direct growth and extension of preexisting vessels. In the yolk-sac and embryo both processes are still going on hand in hand. There remains, however, much to be done in the way of linking up, not only the intraembryonic vessels with each other and with the heart, but also in establishing relations between the intrasomatic and extrasomatic channels by way of the heart, aortæ, and umbilical veins. There is an unmistakable precocity in the vascular development in man, a certain element of haste almost, so that after a given stage has been reached the ground plan of the embryonic circulatory system is sketched out with all possible expedition. Obviously, the most promising method of procedure would be to begin construction at every suitable point. The paramount importance of an adequate circulatory mechanism, as well as its extreme susceptibility, is too well known to call for comment. It is likewise unnecessary to rehearse the evidence that the vessels of the embryonic body are largely formed *in loco* instead of by any invasion from without (Hahn, 1909; Miller and McWhorter, 1914; Schulte, 1914; Reagan, 1915; Sabin, 1917).

In the particular case in question three main groups of embryonic vessels may be recognized—the heart, aortæ, and umbilical veins, each group completely isolated, only the aorta having a connection with the extraembryonic vessels and this with certainty only on one side. The aorta and umbilical vein are both still in process of formation at a number of separate points. To what extent this might also have been true for the heart and first arches we can not say, but doubtless the principles involved were essentially the same. Conditions here are such that the many connections still required to complete the vascular circuit may be made within a very short period of time. It would be useless to speculate concerning priority or sequence, since there must be considerable variation; but in any case the union of the intraembryonic and extraembryonic portions of the umbilical vein would appear to be a relatively late event.

The vascular system, as we find it in this embryo, is really of little more importance to its possessor at this particular moment than are the future respiratory and excretory systems, of which there are as yet not even the faintest traces. The special organs for these last-named functions will appear in their own good time. In the meantime, however, these and other functions will be discharged in other ways, but even now, as later, only upon the basis of an adequate circulatory mechanism. At first the modest needs of the embryo, as regards a circulating or diffusible medium, will be met by the relatively great surface which its component parts present to the surrounding fluid, as in the yolk-sac and coelom. There can be no doubt that important nutritive material finds its way to the young embryo through the coelom, or secondarily through the yolk-sac. Without saying that the fluid within the umbilical vesicle differs materially from that outside, one may still conceive that its lining entoderm may play some small, though evanescent rôle, and that its mesoderm and blood-channels have something more to do than the formation of early blood-cells and vitelline vessels.

In addition to the extensive absorptive or excretive surfaces offered by the early embryo, we have a second intermediary mechanism for adequate diffusion in

the form of the widely distributed mesostroma. The obstacles which this last-named tissue offers to the countless tiny currents resulting from cell activity must be almost *nil*. It is in large measure in these Lilliputian forces, as well as in the various and varying chemical changes which are constantly going on, that one must seek the explanation for the earliest vasculogenic conditions. Cell growth and migrations, cell form and orientation, vacuolation and the formations of cysts and definite channels are all, in part, the local reaction to a present stimulus. Endothelium comes into existence in response to certain influences, and in the face of new conditions it may again revert or give rise to the indifferent tissue from which it sprang. Even after the establishment of a complete, closed circulation, the wide intercellular, often avascular spaces of the embryo must play an important rôle in the exchange of various fluids. Gradually, however, this feature becomes less conspicuous, but in the last analysis the adult conditions are exactly the same, where the individual cells live, move, and have their being in the same primitive way, in the tissue fluids which bathe them.

From the very first there has been what we may call a physiological circulation, howbeit very primitive, but nevertheless quite sufficient. The necessary interchanges and transference of various substances are soon facilitated and accelerated by the gradual appearance of freer pathways and more sharply limited channels in definite localities. These early vessels, with their thin or at times deficient walls, must confer a material benefit upon the adjacent regions, even before the heart is capable of strengthening or directing the feeble currents within them. Soon, of course, the early, primitive arrangements must give way before the powerful pulsations of a functioning heart, which remains henceforth a *sine qua non* of further development.

That the vascular system, as we find it here, can not be injected goes without saying. In the first place there is a most conspicuous lack of continuity, and even where present the vessels do not always present a definite wall separating their lumina from the wide intercellular spaces without. Extravasations under any conditions of intravascular pressure would obviously be a foregone conclusion. One speaks of extravasation because the starting-point is the lumen of the vessel; but here, in many cases, the vessels might be injected from the loose mesostroma around them. The differences between vessel walls and deficiencies in the same are morphological rather than physiological, distinctions of degree rather than of quality, for in both instances there is an interchange of material in both directions.

We would take occasion at this time to express our thanks to Dr. George L. Streeter for so generously placing the facilities of the Carnegie Laboratory at our disposal. Appreciation is also due to Mr. O. O. Heard for invaluable aid rendered in preparing the models from which the accompanying illustrations were made; and to Mr. James F. Didusch for the excellent manner in which these illustrations were carried out.

## BIBLIOGRAPHY.

- BREMER, J. L., 1912. The development of the aorta and the aortic arches in rabbits. *Am. Jour. Anat.*, vol. 13.
- , 1914. The earliest blood-vessel in man. *Ibid.*, vol. 16.
- DANDY, W. E., 1910. A human embryo with seven pairs of somites measuring about 2 mm. in length. *Am. Jour. Anat.*, vol. 10.
- DEBEYRE, A., 1912. Description d'un embryon humain de 0 mm. 9. *Jour. de l'Anat. et de la Physiol.*, t. 18.
- EMMEL, V. E., 1916. The cell clusters in the dorsal aorta of mammalian embryos. *Am. Jour. Anat.*, vol. 19.
- ETERNOD, A. C. F., 1899. Premiers stades de la circulation sanguine dans l'œuf et l'embryon humains. *Anat. Anz.*, Bd. 15.
- , 1909. L'œuf humain implantation et gestation, trophoderme et placenta. Geneve.
- , 1913. Les premiers stades de développement de l'œuf humain. 27th International Congress of Medicine, London, 1913. Section I. Anatomy and Embryology.
- EVANS, H. M., and G. W. BARTELMIZ, 1917. A human embryo of seven to eight somites. *Anat. Record*, vol. 11, p. 355-356.
- FELIX, W., 1910. Zur Entwicklungsgeschichte der Rumpfartern des menschlichen Embryo. *Morph. Jahrb.*, Bd. 41.
- GROSSER, O., 1913. Ein menschlicher Embryo mit Chordakanal. *Anat. Hefte*, Bd. 47.
- HABN, HERMAN, 1909. Experimentelle Studien über die Entstehung des Blutes und der ersten Gefäßen beim Huhnchen. I Theil. Intraembryonale Gefäße. *Arch. f. Entwicklungsmechanik*, Bd. 27.
- HELD, H., 1909. Die Entwicklung des Nervengewebes bei den Wirbeltieren. Leipzig.
- HIS, W., 1880-5. Anatomie menschlicher Embryonen. Leipzig.
- INGALLS, N. W., 1907. Beschreibung eines menschlichen Embryos von 4.9 mm. *Arch. f. mik. Anat.*, Bd. 70.
- , 1918. A human embryo before the appearance of the myotomes. *Contributions to Embryology*, vol. 7, Carnegie Inst. Wash. Pub. No. 227.
- JORDAN, H. E., 1910. A microscopic study of the umbilical vesicle of a 13 mm. human embryo, with special reference to the endodermal tubules and the blood islands. *Anat. Anz.*, Bd. 37.
- , 1917. Aortic clusters in vertebrate embryos. *Anat. Record*, vol. 11, p. 372.
- KEIBEL, F., and C. ELZE, 1908. Normentafeln zur Entwicklungsgeschichte des Menschen. Jena.
- KRÖMER, 1903. Wachsmoell eines jungen menschlichen Embryo. *Verh. d. Ges. f. Gynäkologie*.
- MALL, F. P., 1912. On the development of the human heart. *Am. Jour. Anat.*, vol. 13.
- MILLER, A. M., and J. E. McWHORTER, 1914. Experiments on the development of blood-vessels in the area pellucida and embryonic body of the chick. *Anat. Record*, vol. 8.
- PARKER, KATHERINE M., 1915. The early development of the heart and anterior vessels in Marsupials, with special reference to Paramoles. *Proc. Zool. Soc. London*. Part III.
- REAGEN, F. P., 1915. Vascularization phenomena in fragments of embryonic bodies completely isolated from yolk-sac blastoderm. *Anat. Record*, vol. 9.
- SABIN, F. R., 1917. Origin and development of the primitive vessels of the chick and of the pig. *Contributions to Embryology*, vol. 6, Carnegie Inst. Wash. Pub. No. 226.
- SCHULTE, H. VON W., 1914. Early stages in vasculogenesis in the cat (*Felis domestica*), with special reference to the mesenchymal origin of endothelium. *Memoirs Wistar Institute*, No. 3.
- , 1916. The fusion of the cardiac anlagen and the formation of the cardiac loop in the cat (*Felis domestica*). *Am. Jour. Anat.*, vol. 20.
- SPEE, GRAF, 1896. Zur Demonstration über die Entwicklung der Drüsen des menschlichen Dottersacks. *Anat. Anz.*, Bd. 12.
- STUDNÍČKA, F. K., 1911. Das Mesenchym und das Mesostroma der Froschlaven und deren Produkte. *Anat. Anz.*, Bd. 40.
- , 1912. Die Plasmodesmen und die Cytodesmen. *Ibid.*
- V. SZILY, A., 1901. Zur Glaskörperfrage. *Anat. Anz.*, Bd. 24.
- , 1908. Ueber das Entstehen eines fibrillaren Stützgewebes in Embryo und dessen Verhältnis zur Glaskörperfrage. *Anat. Hefte*, Bd. 35.
- TANDLER, J., 1912. The development of the heart. *Manual of Human Embryology*, Keibel and Mall, vol. 2, p. 534.
- WANG, C. C., 1918. The earliest stages of development of the blood-vessels and of the heart in ferret embryos. *Jour. Anat. and Physiol.*, vol. 52.
- WILSON, J. T., 1914. Observations upon young human embryos. *Jour. Anat. and Physiol.*, vol. 48.

## DESCRIPTIONS OF PLATES.

## PLATE 1.

- FIG. 1. Left lateral view of model of embryonic body viewed in the plane of section.  $\times 100$ . Yolk-sac, amnion, and body-stalk have been cut away.
- FIG. 2. Dorsal view of the same model. Both views show open neural groove. Otic plates and V ganglia appear as darker, rounded areas, the former larger and farther lateral, in the region of the rhombencephalon. Outlines of the underlying somites and in figure 2 the left umbilical vein. At the posterior end of the body the broad, dark line indicates the primitive-streak region with the primitive node at its anterior end and the cloacal membrane at the posterior end. Projecting from the cut surface of the body-stalk are the two umbilical arteries, with their branches to form the ventral venous plexus (cf. figs. 3 and 4); between the arteries is the allantois. In figure 1, first ectodermic pocket in front of left otic plate, opposite midbrain flexure.

## PLATE 2.

- FIG. 3. Chorion, body-stalk, and embryo, the last on sagittal section, view as in figure 1.  $\times 90$ . Ectoderm is shown in yellow, entoderm in green, vessels in red. Chorion shows numerous small vessels and the slender connection with the large venous plexus of body-stalk. Lower anastomosis between umbilical artery and ventral venous plexus not shown. Distal portion of allantois in contact with mesothelium of body-stalk. Primitive streak between primitive node and cloacal membrane. Heart plexus suspended between myoepicardial mantle and fore-gut (cf. figs. 7 and 8 on plate 4). Line of section 12-3-6, text-figure A, is indicated.

## PLATE 3.

- FIG. 4. Vascular system as seen from the right side.  $\times 100$ . Color scheme as in figure 3. The ectoderm has been cut away close to the border of the medullary folds. The mesoderm of the embryo and adjacent yolk-sac has been removed to show the vessels embedded in it. In the vitelline plexus and that part of it which represents the yolk-sac portion of the vitelline (umbilical) artery, the endothelial vessels are represented in darker color than the less definitely lined channels. The same is true for the anterior portion of the dorsal aorta and the isolated vesicles in the roof of the fore-gut. Scattered blood-islands and other vascular formations are seen through the mesoderm of the yolk-sac. Anterior to the branch of the aorta (marked vitelline artery) is a second, more doubtful connection between the aorta and the vitelline plexus.

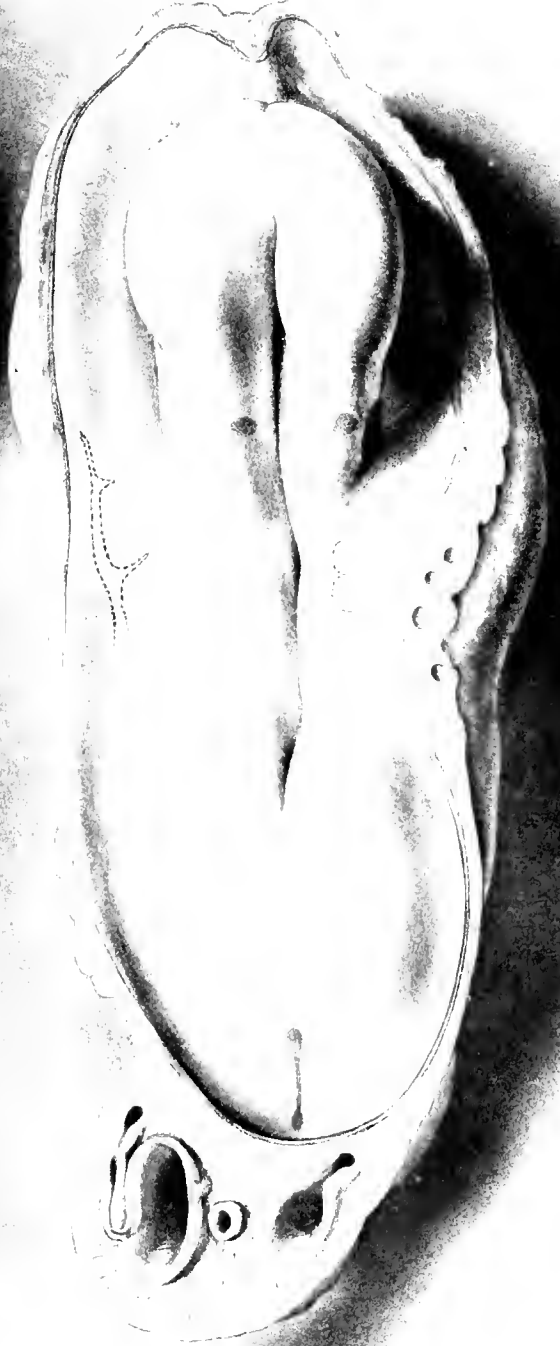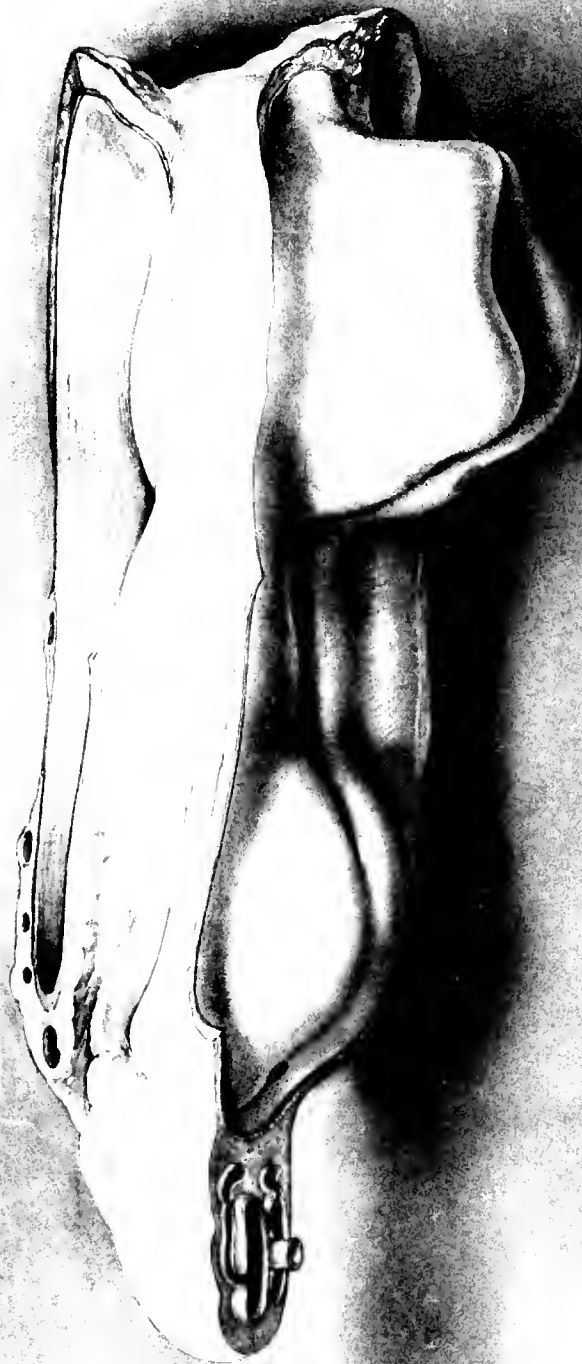## PLATE 4.

- FIG. 5. Right ventrolateral view of heart, myoepicardial mantle, and pericardial cavity.  $\times 100$ . Ventral wall, toward exocoelom, has been removed (cf. fig. 3).
- FIG. 6. Ventral view of same model, slightly from the left side. The vein in the splanchnopleure on the right side is the yolk-sac portion of the omphalomesenteric vein, as yet unconnected with the heart.
- FIG. 7. Right ventrolateral view of cardiac plexus.  $\times 200$ .
- FIG. 8. Same model in ventral view. For position of heart plexus within the body, see figures 3 and 4.

## PLATE 5.

(Further details concerning the figures on this plate will be found in the text.)

- FIG. 9. Section 12-1-2.  $\times 350$ . Portion of body-stalk low down, showing blood-islands in left umbilical artery. Toward the yolk-sac, above in the illustration, the lumen of the artery communicates freely with the spaces in the mesenchyme.
- FIG. 10. Section 12-1-6.  $\times 350$ . Right umbilical artery in body-stalk, at a slightly higher level than figure 9. The vessel wall is here much better defined than that shown in figure 9. The blood-island is also less dense and almost free within the vessel. Toward the yolk-sac the changes in the vessel wall and relation of its lumen to the wide tissue spaces in front can be seen. This represents the first indication of a connection between the vessels in the embryo and those of the body-stalk; in this case between the right dorsal aorta and the right umbilical artery, through the intermediation of the caudal portion of the vitelline plexus and of the vitelline artery.
- FIG. 11. Section 12-3-5.  $\times 350$ . Detail of text-figure A. Section through heart, about the middle of the organ. The thickening of the mantle on the right side of the heart is only apparent, being due to the sudden change in curvature at this level.
- FIG. 12. Section 12-2-6.  $\times 600$ . Caudal end of left dorsal aorta, represented by an elongated blood island. Beginning lumen formation near its posterior end. The mesoderm in this region has not yet begun to segment.





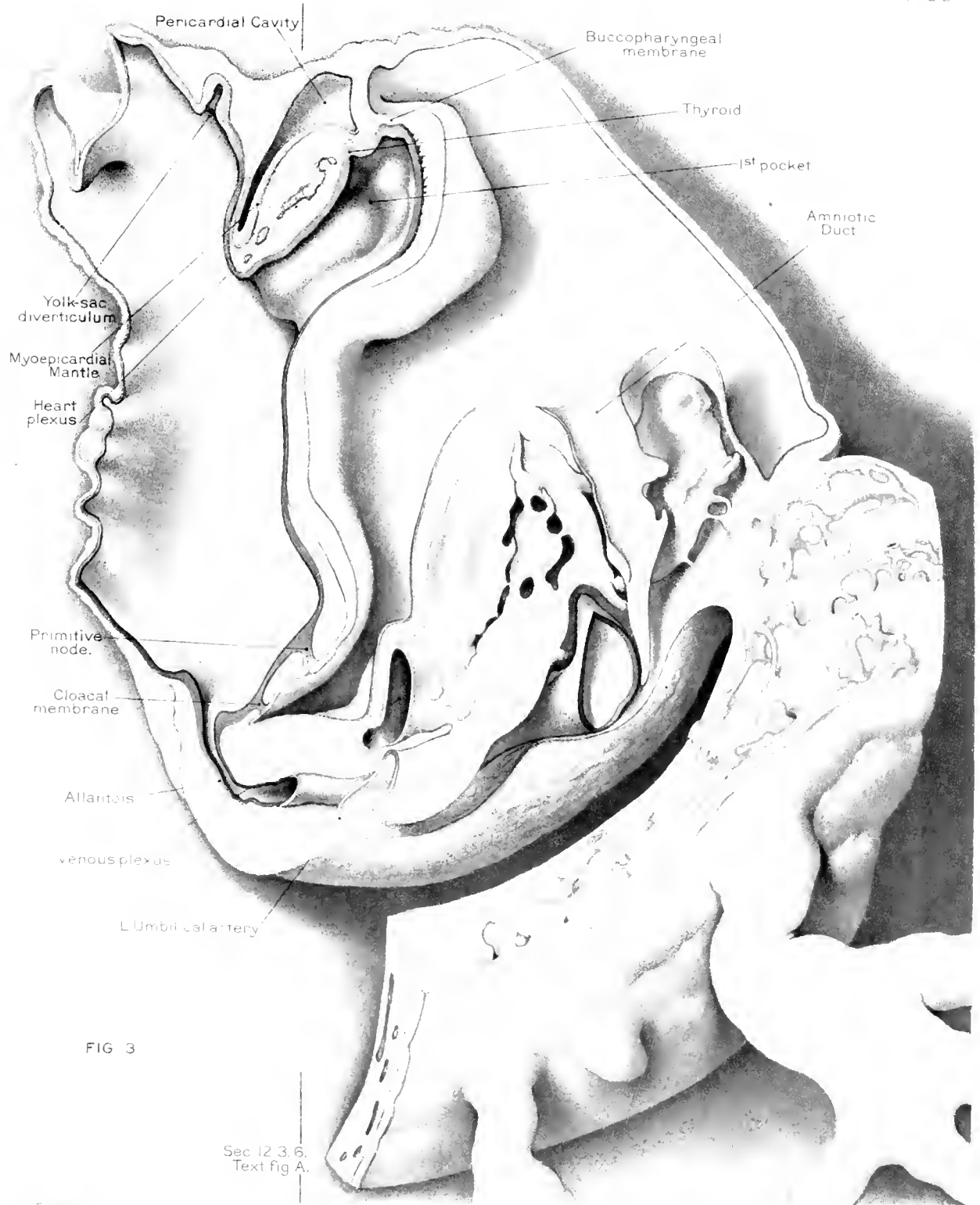
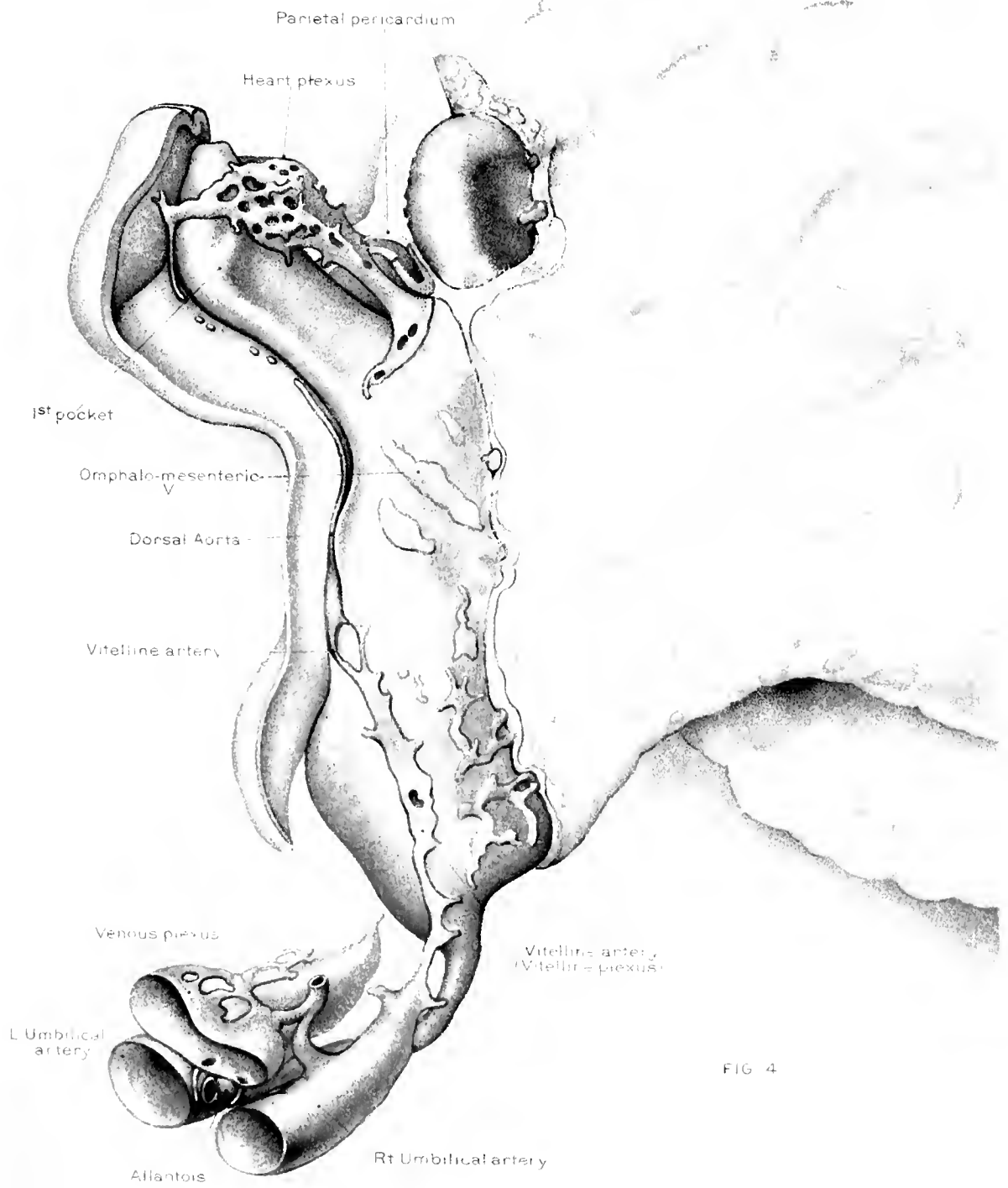


FIG 3

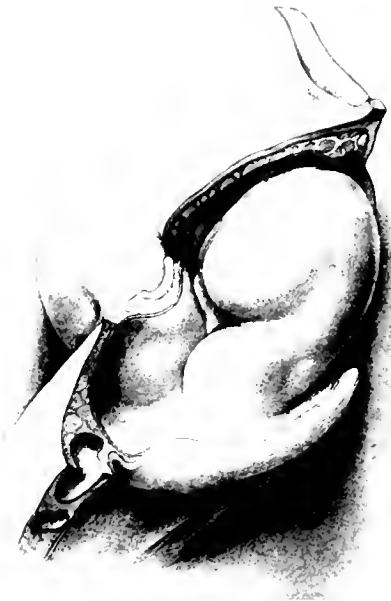Sec 12 3. 6.  
Text fig A.







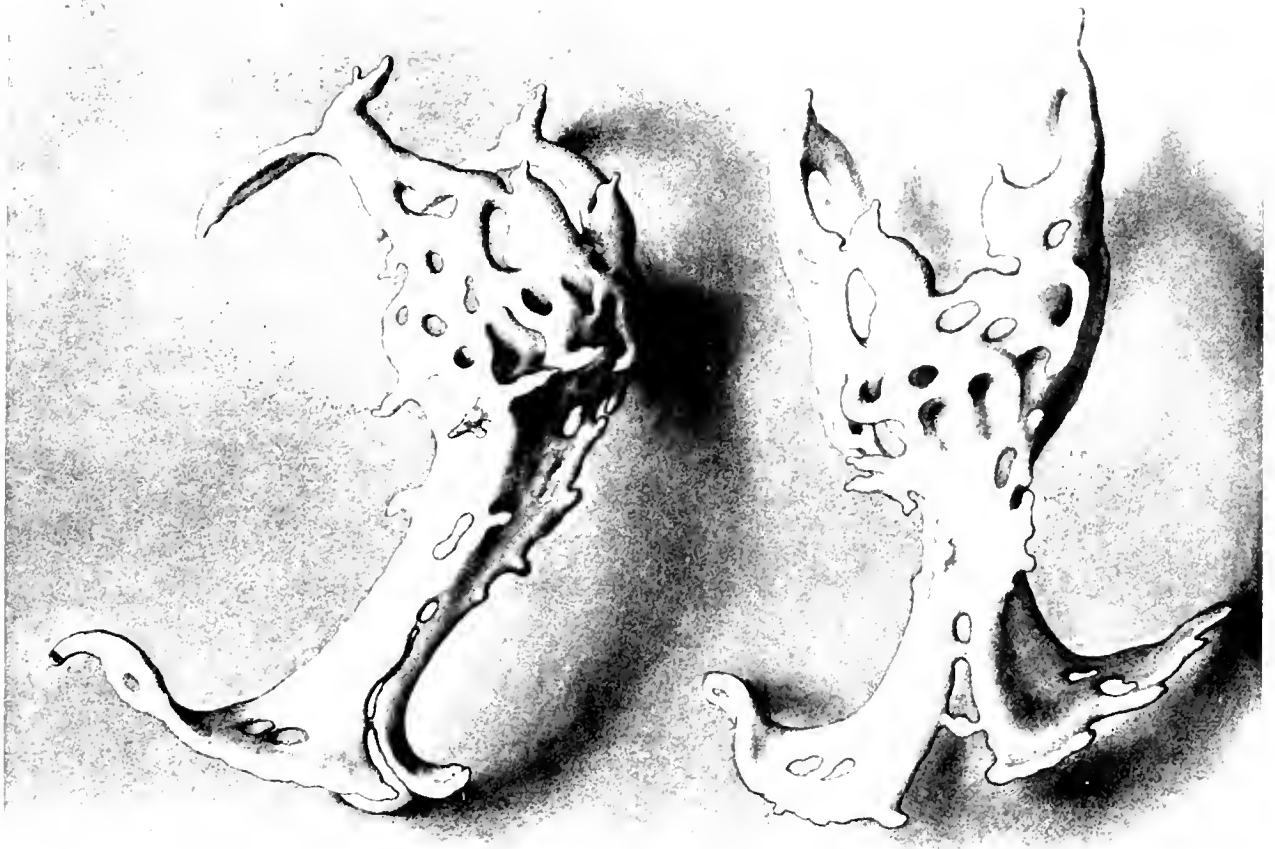



5



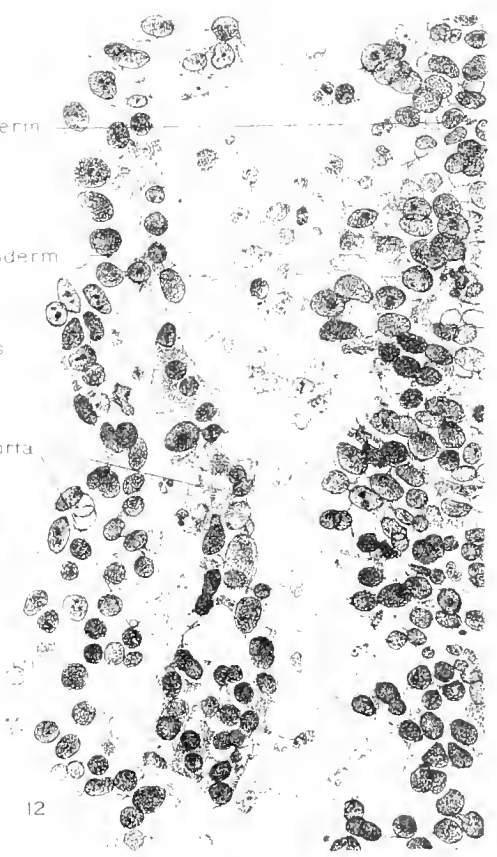
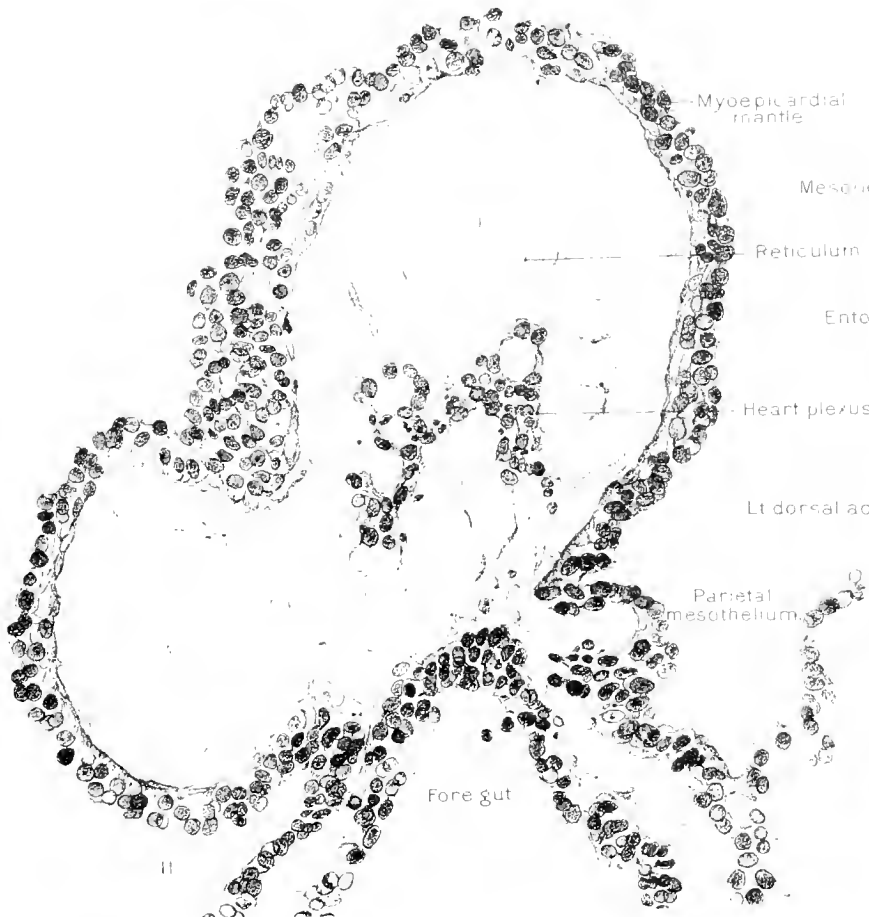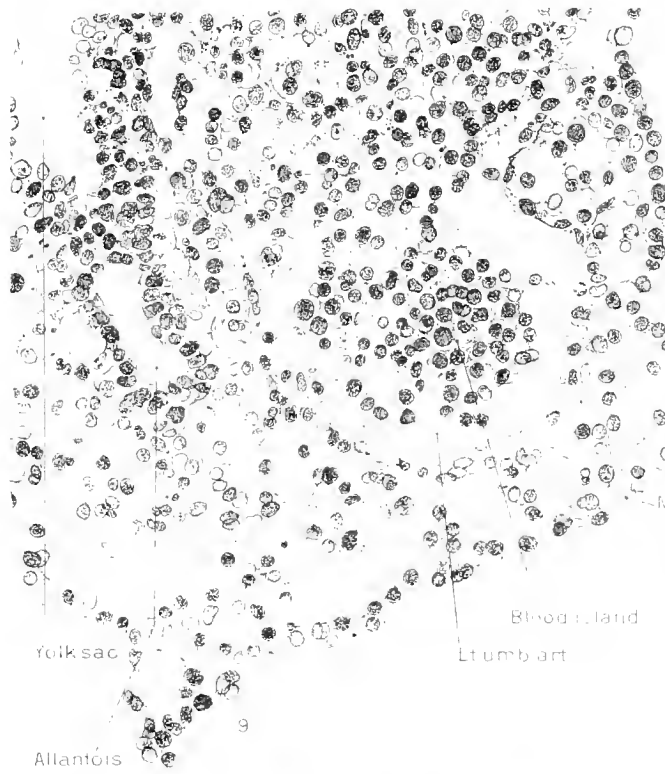
6



7

8







CONTRIBUTIONS TO EMBRYOLOGY, No. 53.

---

THE EFFECTS OF INANITION IN THE PREGNANT ALBINO RAT,  
WITH SPECIAL REFERENCE TO THE CHANGES IN THE  
RELATIVE WEIGHTS OF THE VARIOUS PARTS,  
SYSTEMS, AND ORGANS OF THE OFFSPRING.

---

BY LEE WILLIS BARRY, M. D., PH. D.,

*Of the Departments of Obstetrics and Gynecology and of Anatomy, University of Minnesota.*

---

## CONTENTS.

	PAGE.
Materials and methods	93
Breeding	93
Period and severity of starvation	94
Preventing the mothers from eating their young	94
Autopsies	95
General effects of underfeeding	97
Blighting of ovum	97
Length of gestation	98
Abortion and premature delivery	98
Sterility	99
Stillbirths and viability of the newborn	99
Size of litters	100
Weight of fetus	100
Relative weights and lengths of body parts	101
Discussion	125
Summary	127
Bibliography	135



# THE EFFECTS OF INANITION IN THE PREGNANT ALBINO RAT, WITH SPECIAL REFERENCE TO THE CHANGES IN THE RELATIVE WEIGHTS OF THE VARIOUS PARTS, SYSTEMS, AND ORGANS OF THE OFFSPRING.

BY LEE WILLIS BARRY, M. D., PH. D.

That a restriction of the diet of the mother during pregnancy usually results in a decrease in the weight of the offspring has long been known. Prochownick (1899, 1901) obtained a marked reduction in the weight of the human newborn by a restriction of the mother's diet during the last weeks of pregnancy. Rudolski (1893) starved rabbits and a dog during pregnancy and noted a reduction in the size of the offspring. Paton (1903) underfed pregnant guinea-pigs and obtained a marked reduction in the weight of the young. Reeb (1905) underfed rabbits and dogs during pregnancy and obtained young greatly reduced in weight. However, none of the above made any observations upon the changes in the relative weights of the various organs, systems, and parts of the newborn which might occur during inanition of the pregnant mother. The main object of this investigation, therefore, is to show the effect of inanition in the pregnant albino rat upon the changes in the relative weights of the various systems, organs, and parts of her newborn. Observations were made also on the possibility of blighting of the ovum, death of the fetus *in utero*, prolongation of gestation, abortions, and premature deliveries during inanition of the mother.

The work was done in the Departments of Obstetrics and of Anatomy of the University of Minnesota, under the supervision of Doctors J. C. Litzenberg and C. M. Jackson, to whom I am deeply indebted for valuable aid and suggestions.

## MATERIALS AND METHODS.

For the present investigations, two series of adult female rats (*Mus norvegicus albinus*) were used for inanition during pregnancy. Those in series A are adult females from the colony at the Institute of Anatomy, which were kindly given over to my use by Dr. C. M. Jackson; Series B consists of adult females from several sources. A few were reared from normal litters in Series A; some were purchased from a local animal dealer, and others were obtained from the departments of Physiology and Psychology of the University. Unfortunately, however, the exact age of very few of the females was known.

## BREEDING.

Since the influence of inanition on the length of gestation was to be noted, and in order to exclude the possibility of some of the small rats being the result of premature birth, it was very important to know the approximate date of copulation.

Three methods were used: (1) Kirkham and Burr (1913) have shown that the female albino rat usually ovulates within 20 to 48 hours after the birth of a litter, and impregnation occurs 1 to 4 days after the casting of a litter. A few of my females became pregnant by this method, the males being left with the mother

during the second night following delivery. This method was abandoned, however, since out of a very large number of females delivering only a few became pregnant.

(2) The second method was to place several males alone in small wire cages and once each day the different females were placed with the males. If the female was in heat, copulation usually took place at once. The female was not removed at once, but was left with the male for a period varying from 15 minutes to an hour. If not in heat, the female usually resented the advances of the male, in which case she was removed and replaced by another female. After successful pairing with the male, the female was weighed. Her weight, together with her number, was recorded, and she was placed in a cage with other females that had paired. It was found better to place the female in with the male, because when the process was reversed the male, suddenly finding himself thrust into a strange cage, paid very scant attention to the female, but would spend all his time attempting to escape from the strange cage. The majority of the females were paired by this method.

(3) The third method employed consisted in placing several males in a cage with a number of females. They were left together constantly and inspected at intervals of 6 hours during the day and once, in the evening. When a female in the cage became in heat, the males would copulate with her with such frequency that in a short time the vagina became distended, reddened, and at times would bleed slightly. After a little experience, one can readily distinguish the females that have copulated by the distended, reddened, and at times slightly bloody vaginal orifice.

#### PERIOD AND SEVERITY OF STARVATION.

In the beginning of the investigations it was decided to starve one group of females throughout pregnancy and another group during the last half only. The results from starvation were so disappointing that this part was abandoned. Of 17 females that had been observed to copulate and were starved from this time for periods varying from 16 to 26 days, only one female gave birth to a litter, 4 of the 17 died, and the others were so weakened that they were saved only with difficulty. In the second group 59 females were starved severely during the last half of pregnancy (or suspected pregnancy), beginning on the eleventh day after copulation. The animals were weighed daily and their weights recorded. The amount of food (usually not more than 1 gram) which they received daily varied with their loss in weight and general condition. The food consisted of whole-wheat bread (Graham) soaked in whole milk. (See table I for amount of food given each female during starvation.) Water from the city supply was allowed in the cages at all times.

#### PREVENTING THE MOTHERS FROM EATING THEIR YOUNG.

A difficulty soon experienced was the eating of the young by the starving mothers. Early in the investigation several of the mothers ate and mutilated their newborn young, rendering them worthless for dissection purposes. Various muzzles were devised but without success. The method finally adopted was to place the pregnant female in a cage with a wire bottom, the meshes of which were 1 cm. square, thus allowing the newborn rats to drop through onto a clean piece of paper beneath. Thus, not only were the newborns saved for dissection, but any abortions or premature deliveries might be noted.

Throughout the period of inanition the pregnant females were kept in a specially warmed room in order to prevent death from chilling or pneumonia.

#### AUTOPSIES.

In this investigation 99 rats were autopsied, 60 of which were from mothers underfed during the last half of pregnancy, 29 were normal fetuses removed from the recently killed mother, and 10 were normal newborns. In order to compare the effect of prenatal inanition in the newborn rat (test), it was necessary to compare this test rat with a normal (control) fetus of the same body-weight from an unstarved mother.

The mothers from which the control fetuses were obtained were chloroformed. After death the abdomen was slit open and the fetuses and placentae removed from the uterine horns. The fetus was removed from the amniotic sac and the umbilical cord severed by crushing in order to prevent bleeding, close to the belly wall. The fetus was quickly wiped dry of excess fluid, killed by chloroform, measured, weighed, and dissected. These are designated the "prenatal controls." The "test rats" are newborn rats from the underfed mothers. The "normal newborns" are newborn rats from normal litters.

The series and number of the mother, the number of the litter, and the order in the litter for each individual dissected is shown in table 4. A or B with the number following denote the series and number of the mother in the series; the number following this denotes the number of litters the mother has borne during the experiment, while the number following the decimal point denotes the number of the individual rat in the litter. For example, B2-2.1 would show that the rat was number 1 in the second litter from the mother number 2, Series B.

It will be noted that these rats (table 4) are arranged in five groups in accordance with their net body-weights. Group I contains the test rats and prenatal controls whose net body-weights range from approximately 2 to 2.5 grams; Group II, those ranging from 2.5 to 3 grams; Group III, those ranging from 3 to 3.5 grams; Group IV, those ranging from 3.5 to 4 grams, and Group V, those ranging from 4 to 4.5 grams. This grouping was done in order to facilitate computations and to render apparent any variations according to the size of the rats. Since no sexual differences were found in the organs and parts, the sexes are combined in the groups and computations. All computations were made on the average weights of the organs and parts. The original individual data will be filed at the Wistar Institute of Anatomy, Philadelphia, where they will be available for reference.

All the test rats autopsied were born by the natural method, although the length of gestation was occasionally prolonged.

The autopsy technique used was the same as that described by Jackson and Lowery (1912) and Jackson (1913), with a few modifications. Their technique was as follows: After killing with chloroform, the gross body-weight and lengths of body (nose-anus) and tail were recorded. The head was removed on a plane just anterior to the larynx and posterior to the cranium, and weighed. The trunk was

suspended, thus allowing the blood (unmeasured) to escape. The eyeballs and brain were then removed and placed in a moist chamber. The trunk was next dissected and the viscera removed and weighed individually in the following sequence: thyroid gland, thymus, heart (opened and blood clots removed), lungs, liver, spleen, stomach and intestines (including contents, mesentery and pancreas, also weighed without contents), suprarenals, kidneys, gonads, and spinal cord.

The extremities were removed at the shoulder and hip joints and weighed. The skin was next removed from the trunk and extremities and weighed; the skeleton and musculature were weighed together; then the musculature was dissected off and its weight determined by subtracting the weight of the skeleton from the combined weight.

As soon as possible after birth of the inanition test-rats, and immediately after the removal of the prenatal controls from the mother, they were killed by chloroform, if not already dead. Each was then placed upon its back and extended by allowing one end of a steel ruler (300 by 35 by 2 mm., weight 263.5 grams) to rest upon the abdomen and neck. In this way the amount of extension was found to be much more constant than by trying to hold the body extended by means of the hand.

The distance from the tip of the nose to the anus (nose-anus length) and from the tip of the tail to the anus (tail-length) was carefully measured by calipers and the distance read off on a millimeter scale.

Jackson and Lowrey weighed the stomach, intestines, and pancreas together with mesentery. In my investigation, however, the stomach, intestines, and pancreas were weighed separately. The technique was as follows: The rat was placed belly down and the skin, muscles, and other tissues dissected from the left lumbar region and an incision made through the peritoneum just below the costal margin. By gentle pressure upon the abdomen, the stomach, spleen, and part of the pancreas were forced through the opening. The spleen was now easily separated from the stomach and pancreas and placed in a moist chamber. The stomach was then freed from its attachments to the liver and pancreas, seized at its junction with the esophagus with a small pair of forceps, firmly compressed to prevent the escape of any of the gastric contents, and severed at that point and also at the pylorus. The stomach was then weighed in a closed container, opened, its contents allowed to escape, and the interior cleaned with moist filter paper, after which it was reweighed. The intestines were removed as described by Jackson and Lowrey (1912) and weighed with and without their contents, after the pancreas had been removed. By subtracting the weight of the contents from the body-weight, the net body-weight was obtained, and this was used as a basis for computations.

It was found that the "gold dust" preparation, used by Jackson (1915) to free the skeleton of its periosteum and ligaments, acted too strongly upon the delicate skeletons in my series, resulting in a loss of the cartilages. Consequently, the skeletons were cleaned as thoroughly as possible of muscles and ligaments merely by dissection. These are designated as "moist" skeletons. The moist skeletons were dried for 1 month (to a constant weight) in an oven at a temperature of 85° to 95° C. to obtain their dry weight.

## GENERAL EFFECTS OF UNDERFEEDING.

## BLIGHTING OF OVUM.

In one experiment 17 female albino rats were underfed for varying periods of 16 to 26 days from the time of observed copulation. Only 1 (A 6) gave birth to a litter after 24 days. This mother received daily 10 grams of food until the eleventh day after copulation, and thereafter 1 gram daily until delivery, starvation being severe only in the last half of pregnancy. Her fetuses were autopsied and included with the data. Of the 17 rats, 4 died of starvation. Autopsy revealed no pneumonia or other disease.

In another series 59 females were underfed from the eleventh day after copulation to delivery, death, or the discovery of no existing pregnancy. Of this number, 19 (table 1), or 32 per cent, gave birth to litters; 12, or 20 per cent, died during pregnancy (table 2); and 27, or 46 per cent, did not give birth to litters (table 3).

Huber (1915) found that in the rat, on the sixth day after copulation, localized thickenings of the uterine mucosa, sufficient to cause localized swellings of the uterine tube, were evident. Stotsenburg (1915) has shown that on the thirteenth day of pregnancy the average weight of the rat fetus is 0.040 gram. It is interesting to note that in my pregnant rats it was found that the swellings in the uterine horns could be palpated through the abdominal wall of the living animal between the tenth and eleventh days after copulation. None of the females (16 in number) underfed from the time of copulation, and not having litters, showed swellings in the uterine horns at any time palpable through the abdominal wall. In the 27 females (table 3) observed to copulate and underfed from the eleventh day thereafter (no litters resulting), swellings in the uterine horns were palpated in 15 cases, doubtful in 3, and not palpable in 9. Of the 27 animals, 5 died during the starvation period; 4 of these were autopsied, 1 (A 63) showing definite swellings in the uterine horns (2 in right, 3 in left, about 8 mm. in diameter), the other three showing no macroscopic evidence of pregnancy.

Microscopic examination of sections of the uterine swellings (in A 63) revealed a mass of degenerating tissue with no evidence of any fetus. One female (B 64) was refed 10 days (after being underfed 12 days) and killed. At autopsy 4 swellings in the left and 5 in the right uterine horn were found, averaging about 1 cm. in diameter. Microscopic examination of these showed a mass of degenerating tissue with no evidences of any fetal tissue. Apparently these were cases of blighted ova or early embryos. What was the fate of the swelling palpated in the other rats starved? Were they absorbed? This question needs further investigation.

It is significant to note that of the 17 females starved from the time of copulation, only one became visibly pregnant and no swellings were ever palpated in the remaining 16. Does starvation early in pregnancy inhibit implantation by lessening the amount of pabulum or embryotroph necessary to the nourishment of the ovum, or by uterine circulatory changes or a condition of acidosis? Or does it cause a blighting of the ovum after implantation? This also needs further investigation.

## LENGTH OF GESTATION.

According to Stotsenburg (1914), the length of gestation in the non-lactating albino rat varies from 21 days and 15 hours to 22 days and 16 hours. The length of gestation in my starved mothers varied from 21 to 26 days; 8 of the 22 total are above the 23-day limit—6 with a gestation-period of 24 days, 1 of 29, 1 of 26. Thus, severe inanition during the last half of pregnancy usually lengthens the duration of gestation comparatively little. This is rather surprising, in view of the fact that King (1913) found the gestation period markedly lengthened in pregnant nursing rats. King says:

"The period of gestation is always prolonged when a female is suckling six or more young. In these cases the number of young in the second litter seems to have less influence on the length of the gestation period than has the number of young suckled, but if both litters are very large, the gestation period may be extended to 34 days."

Daniel (1910) in investigations on the mouse, formulated the following law (quoted by King, 1913, as 'Daniel's law'): "The period of gestation, in lactating mothers, varies directly with the number of young suckled."

Both Daniel and King seem to have overlooked the work on the prolongation of gestation in different species of rats by Lataste (1891), in which he states:

"On voit que, d'une façon générale et sauf perturbations accidentelles, le retard de la gestation, dans une même espèce, est proportionnel au nombre des petits allaités, un nouveau jour de retard correspondant à un nourrisson de plus."

He proved that the retardation of gestation was due to a delay of the implantation of the ovum during the first 6 to 10 days of pregnancy, due probably to a lack of proper nourishment for the ovum as it enters the uterine cavity. He found that traumatizing the mother early in pregnancy markedly prolonged gestation, while at later periods there was no effect. This is in harmony with my observation that there is very little prolongation of gestation in starvation during the latter half of pregnancy.

## ABORTION AND PREMATURE DELIVERY.

Although my females were kept in cages with meshed-wire bottoms, so that the products of conception might fall through, no abortions or premature deliveries were observed. Rudolski (1893), in inanition experiments on rabbits and a dog, stated that premature deliveries seldom occurred, and that abortions were never observed. Prochownick (1901) cites 48 cases in which women were placed on a restricted diet during the last half of pregnancy, with no abortions or premature deliveries resulting. He also reviewed the earlier literature upon the subject. Paton (1903) observed no abortions or premature deliveries in guinea-pigs starved during pregnancy. Reeb (1905) observed premature deliveries in 2 rabbits starved from the beginning of pregnancy, but none in rabbits or dogs starved during the last half of pregnancy.

Although no abortions or premature deliveries were observed, it is interesting to note that 5 of the 12 females that died during pregnancy (table 2) began to bleed from the vagina 1 to 3 days before the end of the normal gestation period. In one

of these (B 64), the fetuses had evidently been dead for some time, as upon section and microscopic examination of the swellings in the uterine horns, a degenerating mass of material was found, in which no fetal structures were distinguishable. Rat B 58 (table 2), killed after refeeding 10 days, showed a similar condition in the uterine horns; but the death of the fetuses evidently occurred earlier, as the swellings of the uterine horns were smaller (5 to 8 mm. in diameter, as compared to 9 to 15 mm. diameter in B 64).

Macroscopic examination of the placenta of the rats dying after hemorrhage revealed no separation of the placenta and no evidence of beginning labor. Are these cases to be regarded as beginning abortions in which the fetuses have died *in utero* and therefore analogous to missed abortions occurring in the human? This subject requires further investigation, checked up by careful microscopic examination to determine whether this bleeding is due to a beginning abortion or is the result of degenerative changes in the placenta itself, or perhaps due to changes in the maternal blood.

#### STERILITY.

From the total number of 76 females starved during pregnancy (or suspected pregnancy), only 4 became pregnant a second time (B 2, B 29, B 43, and B 44, tables 1, 2, and 3). Of the 76 starved, 21 died, a mortality of 27 per cent. Although the remaining 55 were placed with the males frequently, only 4, or 7 per cent, became pregnant after starvation. Thus it appears that inanition during pregnancy produces a condition of sterility in the majority of the females. Whether this sterility is absolute or only temporary can not be as yet stated, since a sufficient period has not elapsed since the starvation of many of the females.

Jackson and Stewart (1919) likewise found that starvation in young female rats produced sterility in a large number of cases.

#### STILLBIRTHS AND VIABILITY OF THE NEWBORN.

From the data in table 1, it is seen that from a total of 129 newborn young from mothers starved during pregnancy, 41 were found dead after delivery. Whether these were dead *in utero*, died during delivery, or afterwards, it is impossible to state. At birth, the newborn dropped through the wire bottom of the cage, and as many were born inclosed within the amniotic sac, death may have resulted from suffocation. The living seemed to be quite vigorous. As they were autopsied as soon as possible after birth, no statements can be made concerning the viability and after-life of these newborn. King (1916), however, has made a study of the growth of albino rats undersized at birth (one a female weighing but 2.6 grams). She states:

“A very small weight at birth indicates that a rat has a handicap in its organization, that environment, however favorable, can not overcome. Such animals, although they appear vigorous and healthy during their growth period and after reaching the adult state, are unquestionably subnormal in regard to the size of the body and the central nervous system.”

## SIZE OF LITTERS.

The average number of young per litter observed in my rats starved during pregnancy was 5.9. King (1915) found an average of 7.0 per litter in 1,089 litters. Apparently starvation during the last half of pregnancy has at least no marked effect on the number of young per litter.

## WEIGHT OF FETUS.

Rudolski (1893) starved rabbits and a dog during pregnancy and found that on one-half to one-third of their normal diet the mothers gave birth to healthy, normal offspring and that at times these litters even exceeded in weight those from mothers on a normal diet. However, upon greater reduction (one-fifth to one-thirtieth) of their normal diet, the mothers gave birth to young many of which were dead-born or died soon after birth. The body dimensions were reduced in size. The offspring were toothless and gelatinous in structure, showing a poor development of the subcutaneous tissues and a marked reduction in the amount of fat.

Prochownik (1901), in a report of 48 cases in which women with contracted pelves were placed on a restricted diet during the last months of pregnancy, found the weight of the newborn to be markedly reduced. The average birth-weight was 2,960 and 2,735 grams, respectively, in 24 males and 24 females. Thus, the males were 11 to 14 per cent and the females 14 to 15 per cent below the average weight for that part of Europe (Hamburg). The length, head circumference, and ossification of the cranial bones were not affected. There was, however, a reduction in the amount of subcutaneous fat.

Paton (1903), in a series of female guinea-pigs kept upon a "low diet" during pregnancy, found the average weight of the litters to be 28 per cent below that in mothers kept upon a normal diet.

Reeb (1905) obtained a marked reduction in the size of the young in rabbits and a dog placed upon a reduced diet during the last half of pregnancy. Although the pregnant rabbits suffered an average loss of but 7.1 per cent in body-weight during inanition, the individual newborn showed a reduction of 20 to 60 per cent in weight as compared with young from the same mothers on a full diet. The dog lost 8.1 per cent during starvation in pregnancy and the individual young showed a loss of 29 per cent as compared with controls from the same dog on a normal diet.

All the above experiments were carried out by a quantitative reduction in diet. Evvard (1912), however, has shown that undersized young with lessened vigor and vitality result when young pregnant sows (gilts) are fed on corn (maize) alone, in large quantities, but unsupplemented by a diet rich in ash and protein. He attributes this reduction in size and vigor of the offspring chiefly to a lack of calcium salts in a diet of corn alone. Later, Evvard, Dox, and Guernsey (1914) found that normal litters resulted if the corn diet was supplemented by calcium chloride (or calcium carbonate) and blood protein.

Hart, McCollum, Steenbock, and Humphrey (1919) fed a diet of corn, grain, and wheat straw to pregnant heifers. The resulting offspring were weak and often dead-born. However, when a suitable salt mixture was added to the above diet,



normal calves resulted. Osborne and Mendel (1914) have shown that the maize kernel (corn) is deficient in certain salts and amino acids which are necessary to normal growth (in the rat).

From my data on the weights of individual rats from mothers starved during the last half of pregnancy, the average gross weight of the newborn is approximately 3 grams. The average gross weight of the normal newborn rat in the same colony has been found to be approximately 5 grams (Stewart, 1918*a*), the average in my 10 normal newborn being 4.92 grams. Consequently, underfeeding during the last half of pregnancy apparently causes a reduction of about 40 per cent in the average birth-weight of the newborn albino rat. The gross body-weight of the individual test rats ranged from 2.1 to 4.4 grams. The average percentage loss of weight of the mother during starvation (table 1) was 28 per cent, the loss ranging from 11 to 39 per cent. There is no constant relation between the loss in body-weight of the mother and the size of the newborn or the number in the litter. However, it should be noted that in general the percentage loss of weight was greatest in the heaviest rats which frequently bore the heaviest fetuses. Also, as might be expected, the weight of the newborn tends to be inversely proportional to the loss in the weight of the mother. Thus, the heaviest newborns (4.3 grams) were from a mother losing only 11 per cent in weight.

Just what effect this loss or retardation in birth-weight has upon the relative weights of the various parts, systems, and organs of the newborn rat (or other animals) has not hitherto been ascertained, so far as appears from the available literature. These effects of prenatal starvation, and a comparison of the results obtained in postnatal starvation, will now be considered for the various organs and parts. In each case the data for the normal newborn will be given first; then the prenatal norm, and finally the condition in the corresponding groups of test rats will be compared. This will enable us to see whether, in these stunted test rats with retarded body-weight, the various parts retain their normal proportions, as found in the normal (younger) fetuses of the same body-weight; or, if not, the character and extent of the disproportions which have arisen. Finally, a comparison will be made with the known effects of postnatal inanition.

#### RELATIVE WEIGHTS AND LENGTHS OF BODY PARTS.

*Ratio of body-weight to body-length.*—In the 10 normal newborn rats dissected, the average body length was 51 mm. (net body-weight 4.92 grams); Stewart (1918*a*), using litters from the same colony, found the average body-length to be 50.3 mm. (net body-weight 5.03 grams.)

The ratio of the body-weight (grams) to the body-length (millimeters) in my newborns was 0.096. In Stewart's series (1918*a*) the ratio is 0.099. The Wistar norm ratio (Donaldson, 1915) is 0.10 for a 51 mm. rat. In my prenatal fetal controls (table 5), the ratio of the body-weight to the body-length is 0.061 in Group I, and increases through all the groups until in Group V it is 0.092. The ratio for the test rats in Group I is 0.061 and increases through all the groups at nearly the same rate as the prenatal controls to 0.089 in Group V.

By comparing the prenatal and newborn norms, it is found that the smaller the fetus *in utero*, the smaller is the figure representing the body weight to body-length ratio; in other words, the younger the fetus (from 2 to 4.1 grams), the less the weight per millimeter of body length. The test rats follow this same law, the ratio being very similar to that in the corresponding normal controls or the same weight or length. Therefore, it may be stated that the growth ratio, or the relation between fetal body-weight and body-length, is not disturbed by starving the mother during pregnancy.

*Ratio of tail-length to body-length.*—The ratio  $\frac{\text{tail-length}}{\text{nose-anus length}}$  is called the "tail ratio." In my normal newborns the tail ratio  $\left(\frac{\text{tail-length, 16.4 mm.}}{\text{body-length, 51 mm.}}\right)$  is 0.311 (sexes combined). Stewart (1918a), in litters from the same colony, found a tail ratio of 0.318 (sexes combined). Jackson (1915a), using litters from both Minnesota and Missouri, found a tail ratio of 0.36 in the newborn (sexes combined). The tail ratio for the prenatal controls in Group I is 0.339 (all females); for the test rats, 0.324; for the controls in Group II, 0.288, for the test rats, 0.310; for the controls in Group III, 0.313, for the test rats 0.327; for the controls in Group IV, 0.300, for the test rats, 0.326; for the controls in Group V, 0.296, and for the test rats, 0.323. The tail ratio for the prenatal norm averaged for all five groups is 0.307; for the test rats, 0.322. From these data it is apparent that the ratio of the tail-length to the body-length during the later prenatal growth of the rat (from 2 to 4.1 grams) is about the same as that found at birth; also that inanition in the mother during pregnancy has very slight influence upon the tail ratio of the offspring.

If the absolute data are directly compared, the tail-length in the test rats in all the groups (table 5) is slightly above that of the prenatal norms of the same average body-weight, being 2.8 per cent above in Group I and 13.1 per cent on Group V, showing an average gain of 6 per cent above the norm in all the groups combined. This gain in tail-length, therefore, appears to be less marked in the smaller rats, becoming greater as the size of the body approaches that normal at birth. It agrees with the observations of Jackson (1915a) and Stewart (1918), that postnatal starvation in growing rats tends to produce relatively long-tailed individuals.

*Head.*—Jackson and Lowrey (1912) give the weight of the head in the newborn albino rat as 1.147 grams, or 21.65 per cent of the body-weight, 5.3 grams (sexes combined). In my normal newborn series the weight of the head is 1.041 grams, or 21.2 per cent of the body-weight, 4.92 grams.

In my prenatal controls, the average weight of the head forms 24.2, 23.0, 22.7, 21.0, and 20.5 per cent of the body-weight in Groups I, II, III, IV, and V, respectively (computed from table 5). Thus, in the prenatal controls, the head has a higher relative weight in the smaller than in the larger rats, which fact agrees very well with the law formulated by Jackson (1909): "A relatively large embryonic head is characteristic of vertebrates in general." The head in the smaller prenatal controls also has a higher relative (percentage) weight than in the normal newborns, the difference decreasing with the increase in the weight of the prenatal controls.

In my test rats the average weight of the head forms 24.0, 24.1, 23.5, 22.3, and 22.0 per cent of the body-weight from Group I to Group V, respectively (computed from table 5). Therefore, the relative weight of the head is slightly higher in the test rat than in the prenatal controls (except in Group I).

The absolute weight of the head in the test rats exceeds that of the corresponding prenatal controls by 2.8, 6.0, 3.8, 6.5, and 7.6 per cent in groups I, II, III, IV, and V, respectively, averaging 5.3 per cent above in the test rats. Thus in prenatal inanition the head shows a slight increase in weight, which is due partly to the increase in weight of the brain, eyeballs, and the integument covering the head.

In postnatal inanition in young rats, a stronger tendency for the head to increase in weight, even when the body-weight has been held constant, has been noted (table 6). Stewart (1918*a*) found the head to increase 45 per cent in weight (as compared with controls of the same body-weight) in rats held at a constant body-weight from birth to 16 days. In a series of rats stunted by underfeeding from birth to 3 weeks (body-weight 10 grams), the average increase in the weight of the head was 16 per cent, as compared with controls of the same body-weight. In rats underfed from age of 3 to 10 weeks, there was an apparent increase in head-weight of 2.1 per cent as compared with controls of the same body-weight (Jackson, 1915*a*). This slight gain in weight is attributed to the slight gain in skeletal weight, which in the head probably overbalances the loss in weight of the integument.

In both acute and chronic inanition in adult rats, the head increases markedly in relative weight and loses slightly in absolute weight (Jackson, 1915).

From the foregoing it appears that the head manifests its strongest relative growth tendency in rats underfed from birth to 16 days. That this growth tendency, though apparently less intense, is present before birth is evidenced by the increase of the head-weight of the test rats as compared with prenatal controls of the same body-weight.

*Extremities and trunk.*—In my normal newborn series, the fore limbs form 7.0 per cent and the hind limbs 7.6 per cent of the body-weight, 4.92 grams. This is a lower relative weight than given by Jackson and Lowrey (1912) for the relative weight of the extremities in the newborn rat of 5.3 grams, their figures being 7.39 and 9.45 per cent for the fore and hind limbs, respectively. This difference is probably due to a variation in technique. Although the fore and hind limbs were always severed from the body at the shoulder and hip joints, respectively, it was extremely difficult to leave the same amount of skin and muscle attached to the limb in each case.

In my prenatal controls, the fore limbs form 5.3, 6.8, 7.4, 6.7, and 7.1 per cent of the body-weight in Groups I to V, respectively (computed from table 5). Thus the relative weight of the fore limbs in the smaller prenatal control fetuses is less than in the normal newborn, but this difference (in relative weight) decreases with the increase in the size of the fetus.

In the test rats, the fore limbs form 6.8, 6.8, 7.2, 7.3, and 7.1 per cent of the body-weight in Groups I to V, respectively (computed from table 5). Thus, with

the exception of Group I (in which the relative weight of the fore limbs in the tests quite markedly exceeds that of the prenatal controls), there is very little difference in the relative weights in the fore limbs of the test rats and prenatal controls, in both of which the fore limbs form a relatively smaller percentage of the body-weight, especially in the smaller rats, than in the normal newborn.

The absolute weight of the fore limbs in the test rats in Group I exceeds that of the prenatal controls by 34 per cent (table 5). In the other groups, however, the difference between the absolute weights of the fore limbs of the test rats and prenatal controls is so irregular that it would be extremely hazardous to draw any conclusions, the average in the test rats being 8 per cent above that of the prenatal controls.

The hind limbs in my prenatal controls form 5.2, 6.3, 6.8, 7.0, and 7.0 per cent of the body-weight in Groups I to V, respectively (computed from table 5). Therefore, as compared with the normal newborn, the hind limbs in the prenatal controls (fetuses) have a lower relative weight, and as in the case of the fore limbs, this difference in relative weight is most marked in the smaller rats (fetuses) and decreases with the increase in size of the prenatal control (fetus).

In my test rats the hind limbs form 6.7, 7.5, 7.4, 7.9, and 7.9 per cent of the body-weight in Groups I to V, respectively (computed from table 5). Therefore, in the test rats, the hind limbs form a higher relative percentage of the body-weight than in the prenatal controls. It thus appears that in the test rats the hind limbs are growing faster than the body as a whole.

The absolute weight of the hind limbs in my test rats exceeds that of the prenatal controls in all the groups, being 36.4, 19.5, 9, 13, and 20 per cent above in Groups I, II, III, IV, and V, respectively (table 5), the average being 19.5 per cent.

It is to be noted that in the prenatal controls the hind limbs, as compared with the fore limbs, have a lower or just equal absolute weight, and the earlier in pregnancy the fetus is removed from the mother the larger are the fore limbs as compared with the hind limbs. This is in accord with the law of cranio-caudal progression in growth as formulated by Jackson (1909). This also may explain the larger size of the hind limbs in the test rats, since in the prenatal controls this growth tendency in the hind limbs has not had sufficient time to develop, due to their shorter sojourn *in utero*, as compared with the test rats, which, although undersized, were born at term.

Jackson and Lowrey (1912), in newborn rats, found the weight of the trunk to be 3.36 grams. In my newborns, the trunk weighs 3.16 grams and forms 64.4 per cent of the average body-weight, 4.92 grams. In my prenatal controls the trunk forms 65.2, 64.0, 63.4, 65.4, and 65.3 per cent of the body-weight in Groups I to V, respectively (computed from table 5). Thus the relative weight of the trunk in the prenatal controls is slighter than in the newborn rats. In my test rats the trunk forms 62.7, 62.3, 62.3, 65.5, and 63.3 per cent of the body-weight in Groups I to V, respectively (computed from table 5).

Thus in the test rat the trunk has about the same relative weight as in the newborn rat, while the relative weight is slightly higher in the prenatal controls

corresponding to the smaller size of their heads and extremities. The difference in the size of the trunk, however, is slight, as evidenced by the fact that its absolute weight in the test rats shows an average loss of but 1.6 per cent. This loss of weight in the trunk compensates for the larger head and extremities in the tests.

Consequently it appears that in prenatal retardation by inanition there is a slight increase in the weight of the fore limbs especially in the smaller rats, a more marked increase in the hind limbs, and a slight decrease in the weight of the trunk. In postnatal starvation in young rats held at a constant body-weight there was very little change in the weights of the trunk and extremities as compared with controls of the same body-weight. In general, there was a slight increase in the weight of the head, counterbalanced by a slight decrease in the weight of the trunk and extremities (Jackson, 1915*a*; Stewart, 1918). During inanition in adult rats, both the head and extremities appear to increase in relative weight, while the trunk decreases (Jackson, 1915; see table 6).

*Integument.*—In my normal newborns the average weight of the integument is 0.794 gram (16.1 per cent of body-weight, 4.92 grams). Stewart (1918*a*), in newborn litters from the same colony, found the weight of the integument to be 0.754 gram (15 per cent of the body-weight, 5.03 grams). These values are slightly lower than that given by Jackson and Lowrey (1912), which was 0.930 gram (19.8 per cent of body-weight). The difference is probably due to a variation in technique, as it is difficult to remove the skin with uniformity.

In my prenatal controls the weight of the integument forms 11.0, 12.8, 13.4, 13.9, and 14.2 per cent of the body-weight in Groups I to V, respectively (computed from table 5). Thus it is evident that the weight of the normal integument is relatively less in the fetus, increasing progressively up to birth.

In my test rats the weight of the integument forms 12.4, 13.6, 15.3, 15.3, and 14.5 per cent of the body-weight in Groups I to V, respectively (computed from table 5). The integument in the test rats thus forms a relatively higher percentage of the body-weight (in all the groups) than in the prenatal controls.

The absolute weight (see table 5) of the integument in the test rats exceeds that of the prenatal controls by 18 per cent in Group I, 6.4 per cent in Group II, 14.6 per cent in Group III, 10 per cent in Group IV, and 3 per cent in Group V. The average increase in all the groups is 10.4 per cent. Although this increase in weight is irregular, it has a downward trend from Group I to Group V and shows that the nearer the prenatal controls and test rats approach their normal birth-weight, the less is the difference in the relative (percentage) and absolute weights of their integuments. This increase may be due to the longer interval the test rats remained *in utero* as compared with the prenatal controls, or to the fact that the skin has a stronger growth tendency at this time as compared with some of the other parts of the body. It is interesting to note (see table 6) that Stewart (1918) found the integument to remain at a constant weight in rats starved from birth to 3 weeks of age, while in older rats starved for longer or shorter periods the loss in weight of the integument was quite marked. In a younger series kept at a maintenance diet

from birth to 11 to 22 days. Stewart (1918*a*) found the absolute weight of the integument in the test rats to be 25 per cent above that in the controls of the same body-weight. Jackson (1915) found the integument to lose weight in nearly the same proportion as the whole body in acute and chronic inanition in adult rats.

*Skeleton.*—As explained under the section on materials and methods, my “moist” skeleton probably corresponds closely to that referred to by Jackson (1915*a*) as the cartilaginous skeleton. Since the “gold dust” solution used to rid the skeleton of its ligaments and periosteum acted too strongly upon the skeleton in my very small rats, causing a disintegration of the cartilages, no attempts were made to obtain anything corresponding to the cartilaginous skeleton. My observations on the “dried skeleton” are consequently on the dried ligamentous skeleton. Jackson and Lowrey (1912) obtained a value of 0.810 gram for the ligamentous skeleton in the newborn rats, while in my normal newborn the “moist” skeleton weighs but 0.381 gram, 7.8 per cent of body-weight, 4.92 grams. However, this agrees very well with the weight of the newborn moist skeleton of 0.377 gram or 9.0 per cent body-weight—4.92 grams—given by Conrow (1915). It must be stated, however, that despite the greatest care taken in cleaning the skeletons, their range of weight was very great, even in rats of equal weights (see table 5).

In my prenatal controls, the weight of the moist skeleton forms 7.2, 7.2, 7.4, 7.1, and 6.7 per cent of the body-weight in Groups I to V, respectively (computed from table 5). Thus the moist skeleton in the prenatal controls has a relative weight slightly below that of the normal newborn rat.

In my test rats the weight of the moist skeleton forms 5.0, 7.0, 7.4, 7.2, and 7.0 per cent of the body-weight in Groups I to V, respectively (computed from table 5). Thus there is very little difference in the relative weight of the moist skeleton in the test rats and prenatal controls, except in Group I, where its relative weight in the test rats is considerably below that of the prenatal controls. This difference is probably due to errors in technique.

By comparing the absolute weights of the moist skeleton in the test rats with the prenatal controls in table 5, it will be seen that in Group I the absolute weight of the moist skeleton in the test rats is 27 per cent less than in the prenatal controls of the same body-weight. Since such a marked difference can not be accounted for by any change in body-length (in fact, the average body-length of the test rats is 7.3 per cent greater than in the prenatal controls of this group), it must be attributed to errors in technique. In the other four groups the difference in the absolute weights of the moist skeleton in the test rats and prenatal controls is very slight and wholly within the limits of error, considering the difficulties of technique. Probably there is very little real difference between the absolute weight of the moist skeleton in test rats and prenatal controls, but one can hardly reach any definite conclusion.

It should be noted, however, that in postnatal inanition the skeleton (undried) shows its greatest increase in weight, 32 per cent, in rats underfed from the age of 3 weeks to 1 year (Stewart, 1918). In rats underfed from birth to 16 days the gain in

the skeleton (with musculature) is but 6 per cent (Stewart, 1918*a*). This seems to show that the growth tendency in the skeleton is relatively weak at birth, which may explain its apparent loss of weight in my test rats.

In my normal newborn series the weight of the dried skeleton is 0.089 gram or 1.8 per cent of the body-weight, 4.92 grams. Conrow (1915) found the dried skeleton to be 1.9 per cent of the body-weight in the normal newborn rat (body-weight, 4.2 grams; calculated weight of dried skeleton, 0.081 gram).

In my prenatal controls the weight of the dried skeleton forms 1.4, 1.5, 1.5, 1.7, and 1.6 per cent of the body-weight in Groups I to V, respectively (computed from table 5). Thus the dried skeleton in the prenatal control has a relative weight slightly below that of the normal newborn rat.

In my test rats the weight of the dried skeleton forms 1.5, 1.8, 1.7, 1.8, and 1.7 per cent of the body-weight in Groups I to V, respectively (computed from table 5). Thus the relative weight of the dried skeleton in the test rats is slightly higher than in the prenatal controls.

Concerning the absolute weight of the dried skeleton, however (see table 5), the results obtained are different from those in the case of the moist skeleton. Although in Groups I, II, and III (see table 5) the absolute weights of the moist skeletons in the test rats were 27, 1.8, and 5.0 per cent below the prenatal controls of the respective groups, and 0.4 and 0.01 per cent above in groups IV and V, respectively, the absolute weight for the dried skeleton of the test rats exceeds that of the prenatal controls in all five groups, the excess being 7, 20, 14, 9, and 9 per cent, respectively, from Group I to V (see table 5), averaging 12 per cent above for all groups.

This increase in the weight of the dried skeleton in the test rats is evidently due to an increase of dry substance in the bones, cartilages, and ligaments. Therefore, since the dry skeleton shows a relatively greater increase in the test rats as compared with the prenatal controls of the same body-weight, it is apparent that, although the body-weight is retarded, the relative percentages of solid substance and water in the test rats tend to approach that found in the normal newborn rat. The tendency of the skeleton to grow in mass (although at a retarded rate) in cases of underfeeding in rats was observed by Jackson (1915*a*) and by Stewart (1918). Lowrey (1913) found that in the postnatal growth of the rat the amount of dry substance in the ligamentous skeleton increases with age, being 18.1 per cent at birth, 33.3 per cent at 20 days, 39.2 per cent at 6 weeks, 45.9 per cent at 10 weeks, 50.4 per cent at 5 months, and 52.6 per cent at 1 year.

No observations were made on any of the skeletons to determine whether there was any variation in the normal process of differentiation (developmental changes) between the test rats and prenatal controls. Jackson (1915*a*) and Stewart (1918), however, found that during maintenance of body-weight by underfeeding in young rats, skeletal growth and differentiation occurred apparently in a normal manner, although at a retarded rate.

*Musculature.*—The musculature was not weighed separately, but was weighed together with the skeleton and its weight obtained by subtracting the latter from the combined weight. The weight given by Jackson and Lowrey (1912) for the newborn rat is 1.15 grams or 24 per cent of body-weight, 5.3 grams; while in my newborns the weight of the musculature was 1.77 grams or 36 per cent of the body-weight, 4.92 grams. This marked difference is probably due to a variation in technique, as in all my rats the fat was included with the musculature. The reason for this difference in technique is obvious, because in the small rats the fat was poorly differentiated from the muscle.

In my prenatal controls the musculature forms 28, 32, 32, 36.5, and 37.5 per cent of the body-weight in Groups I to V, respectively (computed from table 5). Thus in the prenatal controls it is evident that the relative weight of the musculature is less in the smaller rats, increasing progressively up to birth.

In my test rats the musculature forms 28, 30, 31, 33, and 34 per cent of the body-weight in Groups I to V, respectively (computed from table 5). Thus, in both the test rats and prenatal controls there is apparently an increasing tendency for the musculature to make up a larger proportion of the body-weight as the rat increases in size; that is, the muscle is growing at a relatively faster rate than the remainder of the body, the increase being slightly more marked in the prenatal controls than in the test rats.

The absolute weight of the musculature in the test rats is slightly below that of the prenatal controls with the exception of Group I (see table 5), in which its absolute weight in the test rats is 7 per cent above that in the prenatal controls. Taking the groups as a whole, the absolute weight of the musculature in the test rats is but 5 per cent below that in the prenatal controls. This difference is slight, and may in part be due to a decrease in the fat in the test rats. On account of the difficulties encountered in separating the fat from the musculature, they were weighed together, as previously stated.

In postnatal inanition in young rats, there is apparently a slight gain in weight of the musculature. It shows an increase of but 6, 8, 10, and 3 per cent, respectively, in rats underfed from birth to 16 days, from birth to 3 weeks, from birth to 10 weeks, and from 3 to 10 weeks of age (Stewart, 1918, 1918*a*; Jackson, 1915*a*). The greatest gain observed (25 per cent) was in rats underfed from 10 weeks to 8 months of age (Jackson, 1915*a*). In both acute and chronic inanition in adult rats the musculature loses in about the same proportion as the body as a whole (Jackson, 1915).

In general, it appears that the musculature manifests a relatively weak growth tendency during both prenatal and postnatal inanition, with even a slight loss in the former.

*Visceral group.*—The visceral group includes the brain, spinal cord, eyeballs, and thyroid, as well as the abdominal and thoracic viscera. Jackson and Lowrey (1912) give the weight of the visceral group in the newborn as 0.954 gram, or 18 per cent of the body-weight, 5.3 grams. Stewart (1918*a*) gives the visceral group a



weight of 0.871 gram, or 17.3 per cent of the body-weight, 5.03 grams. The visceral group in my normal newborn series weighs 0.817 gram, or 16.6 per cent of the body-weight, 4.92 grams.

In my prenatal controls the weight of the visceral group forms 23, 21, 18.5, 19.5, and 19 per cent of the body-weight in Groups I to V, respectively (computed from table 5). Therefore it is evident that the relative weight of the visceral group in the prenatal controls (fetuses) exceeds that of the normal newborn rat. This difference is most marked in the smaller rats (fetuses), decreasing as the birth-weight is approached, showing that in the fetal life of the rat (from 2 to 4.1 grams) the viscera constitute a larger proportion of the body-weight than at birth.

In my test rats the weight of the visceral group forms 16.2, 16.6, 16.6, 16.2, and 15.2 per cent of the body-weight in Groups I to V, respectively (computed from table 5). Thus, in the test rats the visceral group forms a slightly smaller percentage of the body-weight than in the normal newborn, while in the prenatal controls the converse is true. The relative weight of the visceral group is markedly lower in the test rats than in the prenatal controls.

In my test rats the absolute weight of the visceral group is less than that of the prenatal controls in all the groups (table 5). In Groups I to V the absolute weight of the visceral group in the test rats is 27, 21, 7, 17, and 20 per cent below that of the prenatal controls in the corresponding groups, averaging 18.4 per cent below.

Thus in prenatal inanition the visceral group shows a marked retardation in growth. This is due chiefly to the retarded growth of the liver and lungs.

These results are directly opposed to those in postnatal inanition shortly after birth. Stewart (1918, 1918*a*) found that the absolute weight of the visceral group exceeded that of controls of the same body by 46, 28, and 38 per cent in rats underfed from birth to an average of 16 days, from birth to 3 weeks of age, and from birth to 10 weeks of age, respectively (table 6). In rats underfed from the age of 3 weeks to 10 weeks and from the age of 3 weeks to 1 year, there was no marked change in the weight of the visceral group (Jackson, 1915*a*; Stewart, 1918); while in rats underfed from 10 weeks of age to 8 months, Jackson (1915*a*) found the weight of the visceral group to be 12 per cent below the normal. He found that the visceral group as a whole undergoes very little change in relative weight in adult rats during either acute or chronic inanition.

From the foregoing data it is evident that the growth tendency of the visceral group in the rat during inanition is relatively weak before birth, strongest shortly after birth, and decreases gradually thereafter.

*Remainder.*—The "remainder" is obtained by subtracting the weight of the integument, "moist" skeleton, musculature, and viscera from the net body-weight. It thus includes the loss by evaporation of fluids which escape from the body during dissection, also the larynx, trachea, esophagus, salivary and lymph glands, large vessels, and pieces of fat in the omentum. The remainder may vary with the amount of fat removed from different portions of the body.

In general, no attempt was made to remove any of the fat, such as the "nuchal fat pad," retroperitoneal fat, etc., all of which was included in the musculature.

In my normal newborns (body-weight 4.92 grams) the average weight of the remainder was 1.05 grams (21 per cent of body-weight); Stewart (1918*a*) found its weight to be 1.52 grams (30 per cent of net body-weight, 5.03 grams). This weight is considerably higher than mine, probably due to the fact that he included more fat with the remainder than with the musculature. Jackson and Lowrey (1912), however, found its weight to be 0.97 gram (20.56 per cent of body-weight, 5.3 grams), a value very close to mine.

In my prenatal controls the weight of the remainder forms 31, 27, 28, 23, and 23 per cent of the body-weight in Groups I to V, respectively (computed from table 5). Thus the relative weight of the remainder in the smaller prenatal control rats (fetuses) markedly exceeds that of the normal newborn rat, the difference decreasing as the normal birth-weight is approached.

In my test rats the weight of the remainder forms 37, 34, 31, 28, and 30 per cent of the body-weight in Groups I to V, respectively (computed from table 5). Therefore the relative weight of the remainder in the test rats exceeds that of the prenatal controls in all the groups.

The absolute weight of the remainder in my test rats was considerably above that of my prenatal controls in all the groups, the average being 25.4 per cent above (see table 5).

This relative and absolute increase in the remainder is directly opposed to the results obtained in investigations on postnatal starvation (see table 6). In rats held at a constant weight from birth to 16 days, in another group underfed from birth to 3 weeks (body-weight 10 grams), and in another series underfed from birth to 10 weeks, Stewart (1918*a*, 1918) found in the remainder a decrease of 59, 40, and 23 per cent, respectively, as compared with normal controls of the same body-weight. In rats underfed from the age of 3 to 10 weeks, however, Jackson (1915*a*) found but 2 per cent decrease in the remainder. In young rats underfed up to 1 year of age he found a decrease of but 5 per cent, while in Stewart's series (1918) there is a decrease of 33 per cent. In acute and chronic inanition in adult rats there is a definite decrease in the weight of the remainder, probably due to a loss of fat (Jackson, 1915).

Why the remainder should decrease during postnatal starvation and increase during prenatal inanition is difficult to explain. Possibly there is a larger amount of circulating fluids (blood, lymph, etc.) in my test rats than in the prenatal controls. This increase in the remainder evidently compensates for the loss in weight of the visceral group. This is the converse of what occurs in postnatal starvation, as found by Stewart (1918*a*) in the rats held at birth-weight.

*Brain.*—In my normal newborns the average weight of the brain is 0.235 gram (4.8 per cent of the body-weight, 4.92 grams). Stewart (1918*a*) gives the weight of the brain in the newborn as 0.224 gram (4.5 per cent of the body-weight, 5.03 grams). Jackson (1913) found the weight of the brain in the newborn rat to be 4.8 per cent of the gross body-weight.

In my prenatal controls the weight of the brain forms 6.2, 5.6, 5.0, 4.8, and 4.4 per cent of the body-weight in Groups I to V, respectively (computed from table 5). Thus in the prenatal controls the relative weight of the brain in the smaller rats (fetuses) is greater than that of the normal newborn, this difference in relative weight decreasing, however, as the birth-weight is approached.

In my test rats the weight of the brain forms 6.6, 6.2, 5.6, 5.3, and 5.0 per cent of the body-weight in Groups I to V, respectively (computed from table 5). Thus, in the test rats the brain forms a slightly higher per cent of the body-weight than in the prenatal controls; in both, the smaller the rat, the greater is the weight of the brain relative to the body-weight. Since in the test rats, especially in the smaller ones, the brain tends to form a relatively larger part of the body-weight than in either the normal newborns or in the prenatal controls, it may be quite safely assumed that in a state of inanition of the mother the brain of the fetus has a greater growth tendency than does the remainder of the body as a whole.

In the test rats the absolute weight of the brain exceeds by 12 to 13 per cent (average 12.5 per cent) that in the corresponding prenatal norms, constantly throughout all the groups (see table 5).

Comparing these results with those obtained in postnatal inanition by Jackson and Stewart (see table 6), it is seen that the brain shows its greatest tendency to increase in weight in rats underfed from birth to 16 days (Stewart, 1918*a*). Here the brain shows a gain of 125 per cent in absolute weight above controls of the same body-weight. This gain drops to 60 per cent in rats (body-weight 10 grams) underfed from birth to 3 weeks (Stewart, 1918); and in rats starved from birth to 10 weeks the gain is but 8 per cent. In rats underfed from 3 weeks after birth to 10 weeks of age the brain shows little or no change (Jackson, 1915*a*).

Hatai (1904) found a decrease of 5 per cent in the absolute weight of the brain in young rats losing 30 per cent of their body-weight on an unfavorable diet of starch and beef fat. Later (1908) he found no change in the brain-weight in rats stunted on an unfavorable diet, as compared with normal rats of the same body-weight.

Donaldson (1911), in young rats held at maintenance from 30 to 51 days of age, found the brain-weight to average 7 per cent less than in normal controls of the same age. If a comparison is made, however, with the calculated initial brain-weight, as he points out, the average weight of the brain is 3.6 per cent greater in the underfed rats.

In adult rats, during both acute and chronic inanition, Jackson (1915) observed that the brain even loses slightly in weight.

From the foregoing results, it may be assumed that in the rat during inanition the brain possesses its strongest growth tendency at birth and that this tendency decreases with age (see table 6). Whether this growth impulse is stronger or weaker before birth is hard to decide. From a comparison of the data it would seem to be weaker before birth, since in my test rats from underfed mothers the weight of the absolute brain increased but 12.5 per cent above that of the prenatal norms, while

Stewart (1918a), in starvation 17 to 22 days after birth, found the absolute weight of the brain to gain 125 per cent above that of the controls of the same body-weight. It must be remarked, however, that in my tests the exact character and extent of the inanition of the fetus are somewhat uncertain.

*Spinal cord.*—In my normal newborns the spinal cord weighs 0.036 gram (0.71 per cent of the body-weight, 4.92 grams). Stewart (1918a) gives the weight of the spinal cord in the newborn as 0.035 gram (0.70 per cent of the body-weight, 5.0 grams). The Wistar norm (Donaldson, 1915) for the spinal-cord weight is 0.034 gram at body-weight of 4.95 grams.

The weight of the spinal cord in my prenatal controls forms 1.12, 1.00, 0.91, 0.83, and 0.75 per cent of the body-weight in Groups I to V, respectively (computed from table 5). Thus it is evident that the spinal cord, similar to the brain, in the prenatal controls has a higher relative weight than in the normal newborn rat.

In my test rats the weight of the spinal cord forms 1.13, 1.01, 0.86, 0.80, and 0.75 per cent of the body-weight in Groups I to V, respectively (computed from table 5).

Thus, in the smaller rats, both the test rats and prenatal controls, as compared to the normal newborns, the spinal cord forms a relatively higher percentage of the body-weight, this tendency lessening with the increase in size of the rats, until in the larger rats this difference in relative weight disappears.

From the data in table 5, the absolute weight of the spinal cord is lower in the test rats than in the prenatal controls, with the exception of Groups I and II, where it is respectively 6 and 2 per cent higher in the test rats. The absolute weight in all the groups averages but 0.26 per cent higher in the prenatal controls than in the test rats. This is such a slight difference that it might very well be attributed to errors in technique, since it is very difficult to remove the cord intact from these small rats and also to sever the head from the trunk at exactly the same place. Probably there is very little change in the spinal cord of the fetus during inanition in the mother. The fact that the body-length in the tests and controls varies but little (1 per cent higher in the test rats) would lead one to expect but little difference in the corresponding weights of the spinal cord.

The results obtained in postnatal inanition, however, might lead one to expect an increase in the size of the cord in the stunted individual. Bechterew (1895), in acute inanition of puppies and kittens, made a study of the central nervous system after death of the animal and found the least loss in the spinal cord. Donaldson (1911) found a slight increase in the weight of the spinal cord in young rats, held at body-weight of 34 grams from 30 to 51 days of age. Jackson (1915) found no change in the weight of the spinal cord in acute inanition in adult rats, while in chronic inanition in adult rats he found a slight decrease in the weight.

In newborn rats, however, Stewart (1918a) noted a marked tendency for the cord to continue growing during inanition in which the body is kept at nearly constant weight. From the data in table 6, it is evident in underfed young rats that the spinal cord possesses a very strong growth tendency, greatest at or shortly

after birth, but also present up to adult life. It should be noted that this growth tendency persists for a longer time in the cord than in the brain, probably due to the fact that the brain normally completes its postnatal growth at a relatively earlier age than does the cord.

Why the cord should lose while the brain gains in weight during fetal inanition is difficult to explain. So far as their normal growth tendency during the fetal period is concerned, both appear to be decreasing in about the same relative proportion, judging from a comparison of their prenatal growth norms.

*Eyeballs.*—The eyeballs in my normal newborns weigh 0.025 gram and form 0.50 per cent of the body-weight, 4.92 grams. In Stewart's (1918*a*) newborn they weighed 0.0235 gram and formed 0.47 per cent of the body-weight, 5.03 grams. Jackson (1913) gives the weight of the eyeballs in the newborn as 0.025 gram and 0.53 per cent of the body-weight.

In my prenatal controls the eyeballs form 0.38, 0.42, 0.42, 0.38, and 0.37 per cent of the body-weight in Groups I to V, respectively (computed from table 5). Compared with the normal newborn rat, the relative weight of the eyeballs is much lower in the prenatal controls.

In my test rats the eyeballs form 0.57, 0.52, 0.50, 0.48, and 0.46 per cent of the body-weight in Groups I to V, respectively (computed from table 5). Thus it is evident that the eyeballs in the test rats have a much higher relative weight than in the prenatal controls. In the test rats the relative weight of the eyeballs is about the same as that of the normal newborn. (In the smaller rats it is slightly higher.)

The absolute weight of the eyeballs is markedly higher in the test rats than in the controls in all the groups (table 5), being most pronounced in Group I (the smallest rats), in which the average absolute weight of the eyeballs of the test rats is 56 per cent above that in the prenatal controls. It is interesting to note that, in the range of their weights, in Group I the heaviest eyeballs in the prenatal control just equal the lightest in the test rats. In the other groups the eyeballs in the test rats show an increase in absolute weight above the prenatal controls of over 20 per cent. The average total excess of the absolute weight of the eyeballs in the test rats above that in the prenatal controls is 31.4 per cent.

These results are quite in accord with those obtained in postnatal inanition, although less marked. In postnatal inanition the strongest growth capacity of the eyeball is exhibited in newborns underfed from birth to an average of 16 days (Stewart, 1918*a*), the increase being 146 per cent (table 6). This growth capacity of the eyeball during inanition then decreases somewhat, but rises again in older rats and persists in animals underfed up to 1 year of age. In older rats (adults), in both acute and chronic inanition, the eyeballs lose slightly in weight according to Jackson (1915). He suggests that this remarkable capacity of the eyeball to continue its growth during inanition may be due to its power to absorb water, which makes up so large a proportion of its composition.

*Thymus.*—In my normal newborns, the average weight of the thymus is 0.0070 gram or 0.14 per cent of the body-weight, 4.92 grams. Stewart (1918*a*) gives the

weight of the thymus in the newborn as 0.0079 gram or 0.15 per cent of the body-weight—5.03 grams. The Wistar norm (Donaldson, 1915) is 0.0080 gram, body-weight, 4.9 grams.

In my prenatal controls the thymus forms 0.11, 0.13, 0.13, 0.13, and 0.12 per cent of the body-weight in Groups I to V, respectively (computed from table 5). Thus the relative weight of the thymus in the prenatal controls is slightly lower than in the normal newborn rat.

In my test rats the thymus forms 0.08, 0.09, 0.11, 0.11, and 0.10 per cent of the body weight in Groups I to V, respectively (computed from table 5). Thus the thymus forms a much smaller part of the body-weight in the test rats than in the prenatal controls; that is, its growth has been retarded in the test rats. This is more clearly brought out by a comparison of the absolute weights. In Group I the absolute weight of the thymus, in the test rats, is 29 per cent below that of the prenatal controls; in Group II, 33 per cent below; in Group III, 12 per cent below; in Group IV, 16 per cent below; and in Group V, 15 per cent below, averaging 21 per cent below for all groups. Thus it is seen that the growth of the thymus is considerably retarded in the rat fetus during inanition of the mother.

These results also agree with the loss of weight (hunger involution) of the thymus in cases of postnatal inanition. Jonson (1909), in young rabbits, kept a constant body-weight by underfeeding for 4 weeks, found the weight of the thymus to be reduced to one-thirtieth of that in the controls, the greatest loss of weight being in the cortex. He also found that the reduction in weight of the thymus was proportionate to the loss of the body-fat. This reduction in weight of the thymus in rabbits is much more marked than that obtained by Jackson and Stewart upon rats. Jackson (1915*a*) found a loss of 90 per cent in the thymus in young rats held at maintenance from the age of 3 to 10 weeks and also in young rats underfed 10 weeks to 8 months. Stewart (1913 and 1918*a*) found losses of 80, 30, and 49 per cent, respectively, in the weights of the thymus in young rats underfed from birth to 10 weeks, from birth to 3 weeks, and held at birth-weight for 16 days. Jackson (1915) found no marked change in the weight of the thymus in cases of acute and chronic inanition in adult rats, at which age involution of the thymus had already occurred. The thymus normally reaches its maximum absolute weight in the rat at 85 days (Hatai, 1914) and at 1 year it has undergone a complete age involution (Jackson, 1913).

*Heart.*—In my normal newborns, the average weight of the heart is 0.027 gram or 0.55 per cent of the body-weight, 4.92 grams. Jackson (1913) gives its weight in the newborn as 0.030 gram, or 0.65 per cent of the body-weight, 5.08 grams. Stewart (1918*a*) gives a weight of 0.031 gram, or 0.61 per cent of the body-weight, 5.03 grams.

In my prenatal controls the weight of the heart forms 0.49, 0.52, 0.49, 0.50, and 0.44 per cent of the body-weight in Groups I to V, respectively (computed from table 5). Thus the relative weight of the heart in the prenatal controls is considerably less than in the normal newborn rat.

In my test rats the weight of the heart forms 0.55, 0.53, 0.54, 0.53, and 0.49 per cent of the body-weight in Groups I to V, respectively (computed from table 5). Thus the relative weight of the heart in the test rats is slightly higher than in the prenatal controls. The relative weight in both the test rats and prenatal controls is less than that in the normal newborn rats. It is also evident that in both the prenatal controls and test rats the relative weight of the heart is greater in the smaller as compared with the larger rats.

The absolute weight of the heart is constantly higher in the test rats than in the prenatal controls, the difference being most marked in Group I (table 5) in which the heart weight in the test is 17 per cent higher than that in the prenatal controls. This difference, however, is not so pronounced in the other groups, averaging for all groups 8 per cent above in the test rats.

This gain in heart-weight in prenatal starvation agrees with the results of Stewart (1918*a*), who noted a gain of 26 per cent in absolute weight of the heart in test rats kept at a birth-weight of about 5 grams for an average of 16 days. However, in another series (Stewart, 1918) starved from birth to 3 weeks (body-weight 10 grams), the heart showed a loss of 5 per cent. In still another group, underfed from birth to 10 weeks (body-weight 24 grams), Stewart (1918) found a gain of 27 per cent in the weight of the heart. In slightly older rats, underfed for various periods, the heart loses slightly (Jackson, 1915*a*; Stewart, 1918), while in adult rats the heart shows a decided loss in both acute and chronic inanition (Jackson, 1915).

*Lungs.*—Jackson (1913) gives the absolute weight of the lungs as 0.078 gram or 1.6 per cent of the body-weight, 5.1 grams. The Wistar norm (Donaldson, 1915) is 0.079 gram, or 1.6 per cent of the body-weight, 4.9 grams. In my newborn controls the weight of the lungs is 0.073 gram, or 1.5 per cent of the body-weight, 4.92 grams.

In my prenatal controls the lungs form 2.8, 2.7, 2.3, 2.0, and 2.1 per cent of the body-weight in Groups I to V, respectively (computed from table 5). Thus the relative weight of the lungs is markedly higher in the prenatal controls than in the normal newborn rats. This difference in relative weight is greatest in the smaller rats and decreases as the birth-weight is approached.

In my test rats the lungs form 1.2, 1.5, 1.4, 1.5, and 1.3 per cent of the body-weight in Groups I to V, respectively (computed from table 5). Thus, in the test rats the lungs have a relative weight which is about that of the normal newborn rat, whereas in the prenatal controls the relative weight is approximately double that at birth.

The absolute weight of the lungs in the test rats is 54, 44, 40, 23, and 36 per cent below that of the prenatal controls in Groups I to V, respectively, averaging 39.4 below for all groups. It is interesting to note that in the range of the individual weights the largest lungs in the test rats about equal in size the smallest in the controls.

This lack of ability of the lungs to grow, manifested by a subnormal weight during prenatal inanition, agrees with the results obtained in the postnatal starva-

tion experiments (table 6). Stewart (1918*a*) found a slight gain (3 per cent) in the lungs of rats underfed from birth to an average of 16 days. On underfeeding from birth to 3 weeks, and from birth to 10 weeks of age, the lungs showed a loss of 26 per cent in both series (Stewart, 1918). Jackson (1915*a*) found that the lungs lose 15 per cent in rats starved from the age of 3 weeks to 10 weeks. He also found a loss of 13 per cent in the lungs in a group underfed between the ages of 10 weeks and 8 months. Stewart (1918), however, found the lungs in rats underfed from an age of 3 weeks to 1 year to gain in weight 28 per cent (probably pathological). Jackson (1915) found that the lungs show a tendency to lose weight in adult rats in both acute and chronic inanition and that this loss of weight is about in proportion to the loss of the body as a whole. Consequently, it may be concluded that the lungs exhibit a very weak growth tendency during prenatal as well as during postnatal conditions of inanition.

*Liver.*—The Wistar norm (Donaldson, 1915) for the liver of the newborn rat is 0.205 gram, with a body-weight of 4.9 grams. Stewart (1918*a*) gives the weight as 0.245 gram or 4.9 per cent of the body-weight, 5.03 grams. Jackson (1913) finds a weight of 0.230 gram or 4.3 per cent of the body weight. In my newborns the weight of the liver is 0.250 gram or 5.1 per cent of the body-weight, 4.92 grams.

In my prenatal controls the liver forms 9.1, 8.7, 7.8, 8.1, and 7.7 per cent of the body-weight in Groups I to V, respectively (computed from table 5). Thus the relative weight of the liver in the prenatal controls markedly exceeds that of the normal newborn rat. This difference in relative weight decreases, however, as the normal birth-weight is approached.

In my test rats the liver forms 4.1, 4.5, 4.6, 4.9, and 4.4 per cent of the body-weight in Groups I to V, respectively (computed from table 5). In the smaller test rats, the liver forms a relatively smaller percentage of the body-weight than in the normal newborns. In the prenatal controls, however, the liver forms a much higher relative percentage of the body-weight than in either the normal newborns or in the test rats.

In the test rats the absolute weight of the liver is markedly subnormal in all the groups (table 5), averaging 45 per cent below that of the prenatal controls. In the range of the individual weights in the same groups the highest weight for the liver in the test rats is much below the lowest weight in the prenatal control. Thus in prenatal inanition the growth of the liver is markedly retarded, reaching an absolute weight of approximately one-half that of the prenatal controls.

In postnatal inanition, Stewart (1918*a*) found that the liver loses 23 per cent in rats held at a constant weight from birth to an average of 16 days (table 6). In two other groups underfed from birth to 3 weeks, and from birth to 10 weeks, he found that the liver gains in weight 17 and 64 per cent, respectively. Jackson (1915*a*), in young rats underfed from the age of 3 weeks to 10 weeks, found a gain of 10 per cent in the liver-weight. In rats starved for a longer period, or where it was begun later, the liver shows a loss of weight (Jackson, 1915*a*; Stewart, 1918). Jackson (1915) found that the liver loses markedly in cases of acute and chronic inanition in adult rats.



Thus it would seem that in prenatal life and for a period up to several days after birth, the liver during inanition has a very weak growth tendency, which becomes stronger after the first week of postnatal life and persists up to 6 weeks or 2 months of age, then decreases until it is very weak again as the adult stage is approached.

*Spleen.*—The Wistar norm (Donaldson, 1915) for the spleen in the newborn rat is 0.008 for a body-weight of 4.9 grams. Jackson (1913) gives the weight of the spleen as 0.010 gram, or 0.22 per cent of the body-weight. Stewart (1918*a*) finds the weight to be 0.011 gram, or 0.22 per cent of the body-weight, 5.03 grams. In my normal newborns the average weight of the spleen is 0.010 gram, or 0.20 per cent of the body-weight, 4.92 grams.

The spleen in the prenatal controls forms 0.08, 0.08, 0.13, 0.14, and 0.15 per cent of the body-weight in Groups I to V, respectively, while in the test rats in the corresponding groups it forms 0.12, 0.12, 0.16, 0.17, and 0.21 per cent of the body-weight (computed from table 5). Thus the spleen in the prenatal controls forms a much smaller proportion of the body-weight than it does in the normal newborn; that is, in the rat fetus the spleen is at first relatively small (0.08 per cent of body-weight in a 2.19-gram fetus), but gradually increases in size up to shortly before birth (0.15 per cent of the body-weight in a 4.19-gram fetus), when, in order to reach its normal relative percentage of the newborn body-weight, it must increase rapidly in size (an increase from 0.15 to 0.22 per cent of the body-weight while the fetus is growing from 4.19 to 5.0 grams).

Jackson (1909) in referring to the human fetus says:

“The spleen is at first relatively small, but increases slowly to an average of 0.176 per cent of the whole body in the seventh month. About this time it appears to increase rapidly in relative size, averaging over 0.4 per cent in the eighth and ninth months. In the full-term still-born (143 cases) the spleen averages 0.32 per cent of the total body weight, and in the live-born (101 cases) 0.43 per cent.”

Lowrey (1911) finds practically the same course of growth in the spleen of the pig fetus.

Thus it appears that the prenatal growth of the spleen in the rat is similar to that observed in the human and the pig. In all three animals the spleen apparently develops a strong growth tendency shortly before birth. This probably explains the increase in the relative weight of the spleen in the test rats. Since the test rats have a longer time in the uterus, this late growth tendency in the spleen has more opportunity to develop than in the prenatal controls.

The absolute weight of the spleen in the test rats is constantly higher than that in the prenatal controls in all the groups (see table 5), averaging 34 per cent above.

This growth of the spleen during prenatal inanition agrees very well with the results obtained during postnatal starvation. Stewart (1918*a*) found the spleen to gain 38 per cent in rats kept at birth-weight for an average of 16 days of age. In another series (Stewart, 1918) underfed from birth to 3 weeks of age, the spleen lost 49 per cent. In a third series, starved from birth to 10 weeks of age, the spleen

gained 24 per cent. Jackson (1915*a*) found the spleen to lose 42 per cent in rats starved from 3 weeks of age to 10 weeks. In two series starved during later periods (Jackson, 1915*a*; Stewart, 1918) there was no material change in its weight.

In adult rats in chronic inanition the reduction in the weight of the spleen is about the same as that for the whole body, while in acute inanition the loss is much greater (Jackson, 1915).

*Intestines.*—The intestines, with their contents, have an average weight of 0.141 gram and form 3.0 per cent of the body-weight (4.92 grams) in my normal newborns. The empty intestines have an average weight of 0.062 gram or 1.3 per cent of the body-weight.

In my prenatal controls the intestines with contents form 1.6, 1.9, 1.9, 2.4, and 2.3 per cent of the body-weight (computed from table 5). Thus the relative weight of the intestines with contents is considerably less in the prenatal controls than in the normal newborn rat, the difference decreasing, however, as the prenatal control fetuses approach their birth-weight.

In my test rats the intestines with contents form 1.8, 2.2, 2.5, 2.4, and 2.4 per cent of the body-weight in Groups I to V, respectively (computed from table 5.) Thus the relative weight of the intestines with contents is slightly higher in the test rats than in the prenatal controls.

The empty intestines in my prenatal controls form 0.64, 0.75, 0.76, 0.93, and 1.60 per cent of the body-weight in Groups I to V, respectively (computed from table 5). Thus it is evident that the relative weight of the empty intestines is lower in the fetus, increasing progressively up to birth.

In my test rats the empty intestines form 0.60, 0.71, 0.95, 0.82, and 0.90 per cent of the body-weight in Groups I to V, respectively (computed from table 5). Therefore the relative weight of the empty intestines in the test rats is slightly less than that of the prenatal controls.

The absolute weight of the intestines with contents, in the test rats, exceeds that of the prenatal controls in Group I, II, III, and V by 24, 17, 31, and 2 per cent, respectively. In Group IV the absolute weight is 0.06 per cent lower in the test rats. From the foregoing it is evident that the intestinal contents in the smaller test rats markedly exceeds that of the smaller prenatal controls (fetuses), this difference disappearing in the larger rats, *i. e.*, as the normal birth-weight is approached.

The absolute weight of the empty intestines, however, in the test rats of Group I and II is below that of the prenatal controls, 3 and 5 per cent, respectively. In Group III in the test rats it is 27 per cent above, and in Groups IV and V it is 12 and 16 per cent respectively below that of the controls; averaging 2 per cent below in the test rats for all groups. This difference in absolute weight is slight and may be due to the difficulty of removing the intestinal contents in a uniform manner. It is difficult to explain on any other premises why the absolute weight of the intestines with contents in the test rats should exceed that of the controls by 15 per cent while below them 2 per cent in absolute weight when empty. Jackson (1915*a*), however,

in underfed young rats, found an increase in the intestinal contents, while the empty intestines lost in weight. Since the full stomach in my test rats weighs 3.7 per cent less than that of the prenatal controls, there may be a passage of stomach contents into the intestines, with a possible increase of meconium and mucus in the older rats (test), which may account for the increase in the absolute weight of the full intestines in the test rats.

There may be a retardation of the growth of the intestines during prenatal inanition while the stomach increases slightly in weight. However, on account of the irregularities of the results obtained, it would be hazardous to venture any definite conclusion.

It has been found, however, that in postnatal inanition the gastro-intestinal tract taken as a whole manifests a marked growth capacity in rats starved shortly after birth. Stewart (1918*a*) found that the intestines gained 40 per cent in weight in rats kept at a constant birth-weight for an average of 16 days. In two other groups, underfed from birth to 3 weeks of age and from birth to 10 weeks of age, Stewart (1918) found that the gastro-intestinal tract gained 17 and 100 per cent, respectively.

Jackson (1915*a*) also found that the gastro-intestinal tract gained 28 per cent in rats underfed from the age of 3 to 10 weeks. However, in cases of chronic inanition in rats underfed from the age of 3 weeks to 1 year (Stewart, 1918) and from the age of 10 weeks to 8 months (Jackson, 1915*a*), there is a loss in the gastro-intestinal tract of 27 and 26 per cent, respectively.

In adult rats, during both acute and chronic inanition, there is a marked decrease in the gastro-intestinal tract, both filled and empty, the loss being about 57 per cent in each group (Jackson, 1915).

*Stomach.*—As described under the section on materials and methods, the stomach in the test rats and controls was weighed as a separate organ, instead of being included with the intestines and pancreas as the gastro-intestinal group. However, the stomach and intestines were removed and weighed full and empty in a group of four normal newborn rats (average body-weight 5.0 grams). The average weight of the stomach and intestines with their contents was 0.317 gram. Their weight, empty, was 0.128 gram, a value which agrees very well with that of Jackson (1913), who gives their weights with and without contents as 0.297 and 0.117 gram respectively.

The full stomach in my normal newborns had an average weight of 0.1193 gram (2.4 per cent of body-weight, 4.92 grams). The empty stomach weighed 0.020 gram or 0.41 per cent of the body-weight. Hatai (1918) gives the weight of the empty stomach as 0.030 gram or 0.70 per cent of the body-weight, 4.2 grams. This value is considerably higher than mine, probably due to a variation in technique.

In my prenatal controls, the full stomach forms 0.7, 1.5, 1.5, 1.2, and 1.8 per cent of the body-weight in Groups I to V, respectively (computed from table 5). Thus the relative weight of the full stomach in the prenatal controls is much less than that in the normal newborn rat. The small relative weight of the full stomach

in Group I agrees with the observations of Jackson (1909) that in the human fetus the relative weight of the stomach with contents is at first but little larger than that for the empty stomach.

The full stomach in my test rats forms 1.9, 1.5, 1.5, 1.3, and 1.0 per cent of the body-weight in Groups I to V, respectively (computed from table 5). Thus the relative weight of the full stomach is greater in the smaller test rats, while the converse is true of the prenatal controls.

The absolute weight of the full stomach is variable, averaging 3.7 per cent less in the test rats than in prenatal controls (see table 5).

The empty stomach in my prenatal controls forms 0.31, 0.37, 0.39, 0.37, and 0.38 per cent of the body-weight in Groups I to V, respectively (computed from table 5). Thus the relative weight of the empty stomach in the prenatal controls is slightly less than that of the normal newborn rat, the difference in relative weight being most marked in Group I.

In my test rats the empty stomach forms 0.34, 0.38, 0.40, 0.38, and 0.39 per cent of the body-weight in Groups I to V, respectively (computed from table 5). Thus, with the exception of Group I, there is very little difference in the relative weight of the stomach in the test rats and in the prenatal controls.

In the largest rats (Group V) the stomach (in both the test rats and prenatal controls) has practically the same relative weight as in the normal newborn rat. Thus the normal relative weight of the stomach is disturbed very little by prenatal inanition. The stomach in the test rats shows an average of 5.6 per cent in absolute weight above the prenatal norms. The difference is most marked in Group I (the smallest rats), where the absolute weight in the test rats is 15 per cent above that of the controls (table 5).

*Pancreas.*—In postnatal inanition experiments on rats no direct observations have heretofore been made on the weight of the pancreas. Therefore no comparisons can be made with postnatal results.

Hatai (1918) gives the weight of the pancreas in the newborn rat as 0.0193 gram, or 0.45 per cent body-weight, 4.25 grams. In my normal newborns the weight of the pancreas is 0.0224 gram, or 0.45 per cent body-weight, 4.92 grams.

In my prenatal controls the weight of the pancreas forms 0.35, 0.38, 0.35, 0.45, and 0.42 per cent of the body-weight in Groups I to V, respectively (computed from table 5). Thus, in the smaller prenatal controls (fetuses) the pancreas has a lower relative weight than in the larger rats (fetuses) in which the pancreas has approximately the same relative weight as in the normal newborn rat.

In my test rats the average weight of the pancreas forms 0.31, 0.37, 0.42, 0.37, 0.46 per cent of the body-weight in Groups I to V, respectively (computed from table 5). Thus in the test rats, as in the prenatal controls, the pancreas in the smaller rats forms a lower percentage of body-weight than in the larger rats, in which the pancreas has a relative (percentage) weight about the same as that in the normal newborn rat; but the weight of the pancreas is extremely variable in its individual weight and average absolute weight throughout all the groups (see table 5).

In Group I the absolute weight of the pancreas in the test rats is less by 10 per cent than in the prenatal controls; in Group II it is 2 per cent less; in Group III it is 20 per cent heavier; in Group IV, 16 per cent lighter; while in Group V it is 9 per cent heavier. The average for all groups shows a deficit of 0.2 per cent in the test rats.

From the above it is seen that the weight of the pancreas is very variable. Its low weight in one group is balanced by its high weight in another. Prenatal inanition probably has very little effect upon the relative weight of the pancreas, as its average weight in the test rats is but 0.2 per cent below that in the prenatal norms for the various groups.

*Suprarenals.*—The weight of the suprarenals, according to the Wistar norm (Donaldson, 1915), is 0.0017 gram for a rat of 5.1 grams, or 0.034 per cent of the body-weight. Jackson (1913) gives the weight of the suprarenals in the newborn as 0.0019 gram (0.00188), or 0.039 per cent of the body-weight. In my normal newborns the weight of the suprarenals averages 0.0016 gram or 0.032 per cent of the body-weight, 4.92 grams.

The weight of the suprarenals in my prenatal controls forms 0.044, 0.050, 0.048, 0.049, and 0.045 per cent of the body-weight in Groups I to V, respectively (computed from table 5). Thus the relative weight of the suprarenals in the prenatal controls markedly exceeds that of the normal newborn rat.

In my test rats the average weight of the suprarenals forms 0.026, 0.023, 0.022, 0.024, and 0.024 per cent of the body-weight in Groups I to V, respectively (computed from table 5). Thus it is evident that the relative weight of the suprarenals in the test rats is less than one-half that in the prenatal controls. On the other hand, however, their relative weight in the prenatal controls greatly exceeds their relative weight at birth. Thus, in the prenatal norm fetuses studied (2.19 to 4.19 grams), the suprarenals are relatively larger than at birth. They are probably still larger, relatively, in earlier stages, although no data from their earlier size in the rat are available. Jackson (1909) found that in the human fetus the suprarenals increase rapidly to their maximum (relative volume) in the third fetal month, after which they decrease steadily in relative size.

In the test rats the suprarenals show an average weight 52 per cent below that of the prenatal controls (table 5). The excessively weak growth-tendency of the suprarenals during fetal inanition can not be explained as due to any peculiarity of their normal growth in rats at this time, for, as shown above, the prenatal controls maintain a nearly constant relative (percentage) weight during this period.

In postnatal inanition Stewart (1918*a*) found that in rats kept at birth-weight for 16 days the suprarenals gained 5 per cent in absolute weight over newborn controls, but with longer periods of starvation (underfed from birth to 3 weeks, body weight 10 grams), he found that the suprarenals increased markedly in weight (60 and 114 per cent, respectively).

Jackson (1915*a*) also found that the suprarenals manifested a marked growth tendency in young rats underfed from the age of 3 weeks to 10 weeks, the supra-

renals gaining 26 per cent. Stewart (1918), in chronic inanition in young rats, found that the suprarenals gained 48 per cent in absolute weight, while Jackson (1915*a*) found that the suprarenals lost during chronic inanition (26 per cent). In adult rats there is very little or no loss of absolute weight of the suprarenals during either acute or chronic inanition (Jackson, 1915).

From these observations it would appear that the suprarenals in the rat have a weak growth tendency during inanition in prenatal life and that it is still slight up to 16 days of age, reaching its maximum at a period between this time and 10 weeks, and declining thereafter.

*Kidneys.*—Jackson (1913) found the kidneys in the newborn rat to weigh 0.46 gram or 0.97 per cent of the body-weight. The Wistar norm (Donaldson, 1915) for the kidneys in the newborn is 0.48 gram, or 0.97 per cent of the body-weight, 4.95 grams; in my normal newborns the weight of the kidneys is 0.46 gram or 0.94 per cent of the body-weight, 4.92 grams.

In my prenatal controls the weight of the kidneys forms 0.58, 0.63, 0.54, 0.71 and 0.70 per cent of the body-weight in Groups I to V respectively (computed from table 5). Thus in the prenatal controls the relative weight of the kidneys is less than that in the normal newborn rats. The difference decreases, however, from the small to the larger rats (fetuses). Therefore it is evident that in the rat fetus (from 2 to 4.1 grams) the kidneys are growing faster than the body as a whole.

In my test rats the average weight of the kidneys forms 0.56, 0.67, 0.69, 0.67, and 0.71 per cent of the body-weight in Groups I to V respectively (computed from table 5). There is very little difference in the relative weight of the kidneys in the test rats and the prenatal controls, but in neither have the kidneys reached the relative (percentage) weight of the body which is normal at birth. In both, the kidneys are growing faster than the body as a whole.

The absolute weight of the kidney is variable. Comparing the test rats and the prenatal controls (table 5), it is seen that in some groups the absolute weight is higher in the test rats, in others in the prenatal controls. This makes the results seem of questionable significance. This variability can not be attributed to errors in technique, however, as the kidney is an organ easy to remove and clean. In the test rats the absolute weight of the kidneys shows an average weight of 6 per cent above the prenatal controls.

This increase of 6 per cent in the absolute weight of the kidney during prenatal inanition is not nearly so marked as that noted in young rats underfed for various periods after birth. Stewart (table 6) found that the kidneys showed a gain of 90 per cent in absolute weight in rats kept at a birth-weight for an average of 16 days; this gain was less marked if the underfeeding was prolonged to 3 weeks, being 21 per cent (Stewart, 1918). In rats underfed from birth to 10 weeks the kidneys showed a gain of 38 per cent. In rats underfed from the age of 3 weeks to 10 weeks, however, Jackson (1915*a*) found that the kidneys increased but 4 per cent; and in chronic inanition in young rats, where the starvation was begun from 3 to 10 weeks after

birth and continued to 8 months or a year (Jackson, 1915*a*; Stewart, 1918), the kidneys showed a slight loss in weight.

In both acute and chronic inanition in adult rats the kidneys lose in weight relatively slightly less than the body as a whole (Jackson, 1915).

*Testes and epididymides.*—The Wistar norm (Donaldson, 1915) for the weight of the testes in the newborn rat is 0.004 gram or 0.081 per cent of the body-weight, 4.9 grams. Stewart (1918*a*) gives the weight of the testes in the newborn as 0.0027 gram, or 0.053 per cent of the body-weight, 5.08 grams. In my normal newborn the average weight of the testes is 0.0029 gram, or 0.060 per cent of the body-weight, 4.92 grams. There are no prenatal control males in Group I, consequently no testes for comparison.

In my prenatal controls the weight of the testes forms 0.050, 0.047, 0.042, and 0.040 per cent of the body in groups II to V, respectively (computed from table 5). Thus the relative weight of the testes in the prenatal controls is considerably less than that in the newborn rat. It is to be noted that the relative weight is higher in the smaller rats and decreases as the birth-weight is approached. That is, the testes are lagging behind the body-growth as a whole. In order to reach the relative weight normal for the testes at birth, there must necessarily be a period of very active growth in the testes just before birth (in fetuses between the body-weights of 4.1 and 5 grams).

In my test rats the average weight of the testes forms 0.030, 0.052, 0.056, 0.048, and 0.050 per cent of the body-weight in Groups I to V, respectively (computed from table 5). Thus the relative weight of the testes is slightly higher in the test rats than in the prenatal controls. In both, however, the relative weight of the testes is markedly below that in the normal newborn rat.

The absolute weight of the testes in the test rats averages 16 per cent above the prenatal controls (in 4 groups).

In postnatal starvation, the testes during the first weeks of life manifest a remarkable growth tendency. Stewart (1918*a*) found that the absolute weight of the testes in rats kept at a constant birth-weight for 16 days exceeded that of newborn controls by 374 per cent (table 6), which was the strongest growth tendency exhibited by any organ in the body. In rats underfed from birth to 3 weeks, the increase in the absolute weight of the testes above that of controls of the same body-weight (10 grams) is less, being 188 per cent (Stewart, 1918). In a longer period of underfeeding (birth to 10 weeks), the testes show a gain in weight of but 51 per cent (Stewart, 1918); while in underfeeding from 3 weeks of age to 10 weeks the testes gain 34 per cent (Jackson, 1915*a*). With prolonged starvation, however, the testes may lose considerably (Stewart, 1918), or may show practically no change (Jackson, 1915*a*).

In both acute and chronic inanition, in adult rats, the testes lose at about the same relative rate as the body as a whole, the loss being slightly more marked in chronic inanition (Jackson, 1915).

From the foregoing it appears that during inanition the testes have their strongest growth tendency just after birth, and that this tendency rapidly decreases with the age of the rat. The weaker growth tendency before birth is evidenced by the weight of the testes during prenatal inanition, which is only 16 per cent above that of the prenatal controls of the same body-weight.

Stewart (1918*a*) gives the weight of the epididymides as 0.0016 gram in the newborn rat, body-weight 5.08 grams. Hatai (1918) finds that the weight of the epididymides is 0.0025 gram in the newborn, body-weight of 4.4 grams; in my normal newborns the weight of the epididymides was 0.0012 gram, body-weight 4.92 grams. This weight is slightly below that given by Stewart and is less than half the value given by Hatai. This difference is probably due to a variation in technique used in cleaning the organ.

There were no male prenatal controls in Group I (table 5).

In the other groups the absolute weight of the epididymides in the test rats is considerably above that of the prenatal controls, with the exception of Group III, where it is 12 per cent below. The epididymides, however, average 17 per cent higher in the test rats of the various groups. This is about the same as the relation noted in the testes.

In postnatal inanition the epididymides, like the testes, show their strongest growth tendency shortly after birth (Stewart, 1918, 1918*a*); this, however, disappears earlier in the epididymides than in the testes (see table 6).

*Ovaries.*—Jackson (1913) gives the weight of the ovaries in the newborn rat as 0.00078 gram, body-weight 5.0 grams. Stewart (1915*a*) found their weight to be 0.00110 gram in the newborn with a body-weight of 4.98 grams. In my normal newborns the weight of the ovaries was 0.00060 gram, body-weight 4.98 grams. This lower weight for the ovaries in my series is probably due to a variation in technique, since it is very difficult to free the ovary from its capsule and from the Fallopian tube.

The data on the ovaries are somewhat irregular and conflicting (table 5). In Groups I and II the absolute weight of the ovaries in the test rats exceeds that in the prenatal controls by 68 and 6 per cent, respectively; in Group III it is 37 per cent below; in Group IV it is 2.5 per cent above; in Group V, 33 per cent below. The average weight is 1.3 per cent higher in the test rats. It is hazardous to draw any conclusions from such irregular data, but probably the ovary is very little affected by prenatal inanition.

It is interesting to note, however, that the ovaries in postnatal inanition, in general, show a tendency to increase in weight. This tendency is very slight shortly after birth, since in young rats kept at a constant birth-weight for 16 days the ovaries showed a gain of but 5 per cent in absolute weight above the controls (Stewart, 1918*a*). In rats underfed from birth to 3 weeks the ovaries showed a gain of 83 per cent, and in rats starved from birth to 10 weeks the gain is 54 per cent, Stewart, 1918). In rats kept at a constant body-weight from 3 to 10 weeks of age



the ovaries lose 27 per cent (Jackson, 1915*a*). In longer periods of inanition Stewart (1918) found a gain of 17 per cent in the weight of the ovaries, while Jackson (1915*a*) found a loss of 54 per cent. It should be remarked, however, that Jackson began the underfeeding at 10 weeks instead of at 3 weeks, as in Stewart's series.

From these data it may be concluded that in prenatal life and up to a few days after birth, the growth tendency in the ovary during inanition is very slight; but that it soon reaches a maximum at a period between 2 and 3 weeks of age, declining later.

*Thyroid.*—The Wistar norm (Donaldson, 1915) for the weight of the thyroid gland is 0.00145 gram, or 0.027 per cent of the body-weight, 5.1 grams. Jackson (1913) gives the weight of the thyroid as 0.0012 gram, body-weight 5.1 grams. In my normal newborn series the thyroid weighed 0.0011 gram, or 0.022 per cent of the body-weight, 4.92 grams.

In my prenatal controls the weight of the thyroid forms 0.040, 0.030, 0.032, 0.029, and 0.029 per cent of the body-weight in Groups I to V, respectively (computed from table 5). Thus in the prenatal controls the thyroid forms a relatively higher percentage of the body-weight than in the normal newborn. Since the relative weight of the thyroid decreases as the birth-weight is approached, it is evident that the body as a whole is growing faster than the thyroid.

In my test rats the thyroid forms 0.024, 0.020, 0.023, 0.021, and 0.016 per cent of the body-weight in Groups I to V, respectively (computed from table 5). Thus in the test rats the thyroid has about the same relative weight as in the normal newborn rat and a lower relative weight than in the prenatal controls.

That the thyroid has been inhibited in its growth in the test rats is evident from a comparison of the absolute weights (table 5). The absolute weight of the thyroid in the test rats is 33, 28, 11, 29, and 45 per cent less than that in the prenatal controls in Groups I to V, respectively. Thus, the absolute weight of the thyroid is lower in all the groups, the average being 29 per cent.

In postnatal inanition the thyroid exhibits a tendency to gain slightly in weight in rats held at maintenance from birth to 16 days, or starved from birth to 3 weeks, or from birth to 10 weeks (Stewart, 1918, 1918*a*). In longer periods of starvation the thyroid loses quite markedly (Jackson, 1915*a*; Stewart, 1918).

In adult rats, during acute inanition, the thyroid suffers very little or no loss in weight, while during chronic inanition it loses relatively less than the body as a whole (Jackson, 1915).

#### DISCUSSION.

A comparison of the similarities and differences in the growth of the various organs and systems in both prenatal and postnatal inanition is so well shown in table 6 that a detailed discussion is deemed unnecessary. However, special attention will be called to certain points.

In the systems (see table 6) the "remainder" is constantly above normal in weight in prenatal inanition, while in postnatal inanition it shows a definite loss at various periods throughout the life of the rat.

The visceral group as a whole is subnormal in weight during prenatal inanition. In postnatal inanition, however, it shows a marked tendency to gain in weight in the younger rats (underfed from birth to an average of 16 days, and from birth to 10 weeks, Stewart, 1918*a*, 1918). When the underfeeding is begun at 3 weeks of age, the visceral group shows a slight gain or just maintains a growth equal to that of the controls. In cases of prolonged underfeeding in the young rats (under 1 year of age) and in adult life, the visceral group shows a decided loss. It should be noted, as before mentioned, that the gain or loss in the visceral group during inanition is dominated by a loss or gain in weight of the certain large organs, such as the liver, lungs, gastro-intestinal tract, and brain. In postnatal inanition the gain in the visceral group compensates for the loss in the "remainder," while in prenatal inanition the converse is true. Thus it is evident that the strongest growth tendency manifested by the visceral group during inanition is at a period just after birth and that it becomes progressively weaker thereafter.

The musculature has a subnormal weight in prenatal inanition and shows but a slight gain (musculature and skeleton combined) in rats underfed from birth to an average of 16 days of age (Stewart, 1918*a*). It is in rats underfed from birth to 3 weeks of age that the musculature manifests its greatest gain. This tendency to gain is present, but weaker, in rats underfed for longer periods (Jackson, 1915*a*; Stewart, 1918). In both acute and chronic inanition in adult rats the musculature loses in about the same proportion as the body as a whole (Jackson, 1915). It is evident, therefore, that the growth tendency in the musculature during inanition in the rat is weakest before birth, slightly stronger just after birth, and strongest at a period between birth and 3 weeks of age, declining thereafter.

The skeleton has a subnormal weight during prenatal inanition and shows a very slight gain in rats starved from birth to an average of 16 days. In young rats underfed for longer periods, up to adult life, the skeleton shows a marked tendency to gain. During inanition in adult rats the skeleton shows very little change in weight. Thus the growth tendency manifested by the skeleton during inanition is weakest before birth and slightly stronger from birth to 16 days of age. At 3 weeks of age, however, it is quite strong, increasing slightly toward adult life. It thus appears that the growth tendency manifested during inanition develops at a relatively later period in the skeleton than in the musculature, but persists longer in the former.

The integument manifests a moderately strong growth tendency during prenatal inanition and just after birth (in rats underfed to an average of 16 days of age). In rats underfed from birth to 3 weeks of age the integument shows no gain, and in rats starved for longer periods it shows a constant loss in weight.

In postnatal inanition the organs as a general rule manifest their strongest growth tendency in the youngest rats (underfed from birth to an average of 16 days (Stewart, 1918*a*). The liver, suprarenals and ovaries are exceptions to this rule. The liver loses markedly at this period as compared with a gain at later periods. The suprarenals and ovaries show a very slight gain as compared with marked gain in later periods.

With but few exceptions, those organs which show the most marked gain in the newborn rats (underfed from birth to 16 days) during postnatal inanition are also above normal in prenatal inanition. The spinal cord is the only exception. Also, all the organs which show a loss or only a slight gain in the newborn rats during postnatal inanition (excepting the indefinite "remainder") are subnormal in weight in prenatal inanition.

It should be noted that the organs and systems that are above the normal weight in prenatal inanition have apparently a lower growth capacity than that shown in postnatal inanition just after birth (see table 6), while those organs and systems which are below normal weight in prenatal inanition (with the exception of the thymus) suffer a greater loss than in postnatal inanition. From the foregoing it is evident in general that the organs and systems of the rat have a weaker growth tendency during prenatal than during postnatal inanition.

The present investigations, therefore, emphasize the fact that in different periods in the life of the rat certain organs and parts react differently, as manifested by their growth during inanition. This is probably due mainly to the varying intensity of the normal growth tendency in the organs and parts at different periods.

Jackson and Stewart (1918) have called attention to the fact that during inanition in the rat the varying intensity of growth tendency in the different organs and systems depends on four factors: (1) the duration of the period of inanition, (2) the age at which it occurs, (3) its severity, and (4) the character of the inanition.

In prenatal inanition the duration is known (period of starvation of mother). The age is known (length of gestation). The severity is apparently that sufficient to retard the growth of the entire body, an average of 40 per cent as compared with normal newborn controls. Attention may be called to the fact that some of the apparent differences in the growth tendencies of the organs and parts during prenatal and postnatal inanition may be due to the difference in the relative retardation of the body-growth. That is, while the body-growth (average) was retarded 40 per cent in prenatal inanition, it was retarded 66 per cent in Stewart's (1918a) series in starvation just after birth. The *real nature of the inanition, i. e.*, the amount of reduction in the various nutritive substances reaching the fetus during starvation of the mother, is unknown. The *exact character* of the inanition to which the fetus is subjected is, therefore, uncertain. However, from the nature of the changes in the relative weight of the organs and parts, it may be stated that the maternal organism during starvation in pregnancy makes extraordinary efforts, as is well known, to keep up the necessary supplies of nutritive substances to the growing fetus and thus protect it from the effects of inanition.

#### SUMMARY.

(1) Starvation instituted shortly after copulation in the female albino rat apparently results in an inhibition of pregnancy in the majority of cases. Whether this is due to an inhibition of the implantation, or to death of the ovum, has not been proved.

(2) Of 59 female albino rats starved from the eleventh day after copulation, early death of the fetus *in utero* occurred in 3 cases. Microscopic examination of the

swellings in the uterine horns revealed a mass of degenerating tissue, with no evidence of any fetal structures.

(3) The length of gestation in the mothers starved during the last half of pregnancy varied from 21 to 26 days. Eight (of the 22 total) were above the 23-day normal limit, 6 with a gestation-period of 24 days, 1 of 25, and 1 of 26. The average period of gestation was 23 days, or 1 day above the normal average.

(4) No abortions or premature deliveries were observed in any of the underfed rats.

(5) Of a total of 120 newborn from mothers starved during the last half of pregnancy, 41 were found dead after delivery. Whether these were dead *in utero*, or died during delivery or afterwards, is uncertain, since at birth they dropped through the wire bottom of the cage. Those living-born that were inclosed within the amniotic sac died of suffocation. Those found living seemed quite vigorous.

(6) The average number of observed young per litter, from mothers starved during the last half of pregnancy, was 5.9. (The normal average number of young per litter was 7.0 in 1,089 litters; King and Stotsenburg, 1915.)

(7) A condition of relative sterility apparently results in females starved during the last half of pregnancy. Of the total number starved but 4 became pregnant a second time.

(8) The average weight of the newborn from mothers starved severely during the last half of pregnancy was approximately 3 grams, or 40 per cent below the normal birth-weight of 5 grams.

(9) There was no constant relation between the percentage loss in weight of the mother and the weight of the newborn. In general, however, the largest females showed the largest relative loss in weight and bore the largest young; and the weight of the newborn tends to be inversely proportioned to the severity of the starvation.

(10) A prenatal norm for the various systems and organs was established by comparing the relative weights, at the various fetal stages, with those of the normal newborn.

(11) During prenatal inanition the tail grows in length faster than the remainder of the body, thus giving rise to relatively long-tailed individuals.

(12) Concerning the changes in the general body proportions during prenatal inanition, the head and limbs are slightly above normal weight, counterbalanced by a lower weight in the trunk.

(13) The observations on the various systems are summarized as follows: The "remainder" has a weight 25 per cent higher in the test rats than in the prenatal controls. The integument shows a weight averaging 10 per cent above normal in the test rats. The musculature and moist skeleton are slightly subnormal in weight in the test rats, being 5 and 7 per cent, respectively below the prenatal norm. However, the dried skeleton in the test rats has a weight 12 per cent above the prenatal norm. The visceral group, as a whole, has a markedly subnormal weight in the test rats, being 18 per cent below the prenatal norm. This is due chiefly to the subnormal weight of the liver and lungs. The low weight in the visceral group evidently compensates for the high weight of the "remainder."

(14) The weight changes observed in the individual organs in the test rats during prenatal inanition, as compared with normal fetuses of the same body-weight, show the following average percentage differences in weight:

Brain . . .	<i>p. ct.</i>	Lungs	<i>p. ct.</i>	Intestines with con-	<i>p. ct.</i>	Kidneys	<i>p. ct.</i>
Spinal cord	+12	Liver	-39	tents . . .	+15	Testes . . .	+6
Eyeballs . .	-0.26	Spleen	-45	Intestines empty	-2	Epididymides	+16
Thymus . . .	+31	Stomach with contents	+34	Pancreas	-0.26	Ovaries . . .	+17
Heart . . .	+21	Stomach empty . . .	-4	Suprarenals	-52	Thyroid . . .	+1.3
	+8		+6				-29

(15) In general, therefore, it may be stated that the spleen, eyeballs, epididymides, testes, and brain manifest a fairly strong growth tendency during prenatal inanition, the tendency decreasing in the order named. A slight growth tendency is manifested by the heart, kidneys, stomach, and ovaries, decreasing in the order named. A retardation in growth during prenatal inanition increasing in the order named is shown by the pancreas, spinal cord, intestines, thymus, thyroid, lungs, liver, and suprarenals.

(16) In general, the organs and systems that have been found to gain greatly during postnatal inanition (in the newborn rats) are, during prenatal inanition, also above normal weight, but to a much less degree; while those below or but slightly above normal weight during postnatal inanition show a still greater loss in prenatal inanition. Thus, during inanition, the growth impulse of the organs appears as a rule weaker in the prenatal than in the postnatal period. It should be noted, however, that the exact nature of the prenatal inanition is somewhat uncertain.

TABLE 1.—Data on female albino rats starved during last half of pregnancy and resulting litters.

Series and No.	Age.	Parity: M, multipara; P, primigravida.	Days starved.	Amount of food, during test.	Weight at time of copulation.	Weight at end of starvation.	Loss in body- weight.	Length of gesta- tion.	Number of young in litter.	Males living at birth.	Males dead at birth.	Females living at birth.	Females dead at birth.	Average weight of newborn.
	<i>days.</i>			<i>grams.</i>	<i>grams.</i>	<i>grams.</i>	<i>p. ct.</i>	<i>days.</i>						<i>grams.</i>
A 2	(?)	M	8	30	158	132	17	22	9	2	0	5	0	3.4
A 3	(?)	M	11	27	169	119	30	22	6	1	4	4	0	2.7
A 4	(?)	M	11	17	217	156	28	22	3	0	2	0	1	2.8
A 5	(?)	M	14	52	230	205	11	26	7	3	1	2	1	4.3
A 6 <sup>1</sup>	(?)	M	13	123	149	100	33	24	7	3	1	3	0	2.9
B 2	(?)	M	15	15	285	179	37	25	9	2	3	2	2	3.8
B 2	(?)	M	11	11	288	192	33	22	8	0	4	1	3	3.4
B 9	(?)	M	9	9	177	144	19	21	3	0	1	2	0	3.6
B 22	(?)	M	11	11	143	95	34	22	8	3	1	3	1	2.7
B 29	(?)	M	12	11	209	170	19	23	1	0	0	1	0	3.7
B 30	(?)	P	10	10	155	95	39	24	4	3	0	0	1	3.8
B 34	(?)	P	11	11	128	100	22	22	7	3	0	4	0	3.2
B 38	(?)	M	12	12	173	118	32	23	3	2	0	1	0	3.5
B 43	110	P	11	41	130	101	23	22	1	0	0	1	0	2.1
B 43	166	M	14	11	190	138	27	24	8	3	0	5	0	3.9
B 44	(?)	M	11	11	171	124	28	23	5	2	1	1	1	2.1
B 46	(?)	M	12	12	180	130	28	24	9	2	1	5	1	2.7
B 47	(?)	M	12	12	181	135	26	24	6	2	2	1	1	3.8
B 48	(?)	M	10	10	170	117	31	21	6	0	1	1	4	3.4
B 58	(?)	(?)	10	10	135	95	30	21	8	4	0	1	0	2.4
B 65	(?)	M	13	13	147	112	24	23	5	2	0	2	1	3.7
B 68	133	P	10	10	130	90	31	22	5	0	4	0	1	2.9

<sup>1</sup>Starved moderately for 11 days after copulation, then starved severely from eleventh to twenty-fourth day of pregnancy. Note: Rats B2 and B43 were underfed during two pregnancies.

TABLE 2.—Data on pregnant female rats starved from eleventh day, death resulting.

Series and No.	Age.	Parity: M, multipara; V, virgin.	Days starved.	Amount of food.	Weight at beginning of pregnancy.	Weight at death.	Loss of weight.	Length of gestation at time of death.	Number in litter.	Weights of individual fetuses.
A 7 <sup>1</sup>	days. (?)	M	10	grams. 26	grams. 181	grams. 143.5	p. ct. 21	420	11	grams. 2.9, 2.8, 3.2, 3.4, 3.1, 2.8, 3.2, 3.5, 3.1, 3.7, 2.7.
A 9 <sup>2</sup>	(?)	M	11	51	168	117	24	26	3	4.6, 4.6, 5.4.
A 10 <sup>3</sup>	(?)	M	10	24	173	127	27	20	2	1.0, 7.5.
B 6 <sup>3</sup>	(?)	M	7	7	187	124	31	420	3	1.3, 1.7, 1.4.
B 10 <sup>4</sup>	(?)	M	6	6	160	134	16	17	5	0.30, 0.32, 0.28, 0.40, 0.31.
B 33 <sup>3</sup>	194	V	8	8	150	109.5	27	18	7	0.65, 0.60, 0.70, 0.65, 0.65, 0.65, 0.75.
B 32 <sup>1</sup>	183	V	8	8	132	91	31	419	6	0.90, 1.2, 0.90, 0.80, 0.95, 1.1.
B 49 <sup>1</sup>	(?)	M	10	10	158	110.5	31	420	8	Not weighed.
B 68 <sup>4</sup>	170	M	7	7	148	98	34	18	7	0.20, 0.40, 0.30, 0.40, 0.32, 0.33, 0.29.
B 44 <sup>5</sup>	(?)	M	9	9	173	131	24	20	(?)	No autopsy.
B 57 <sup>3</sup>	143	M	9	9	149	98	34	21	(?)	Do.
B 58 <sup>3</sup>	(?)	M	11	11	141	111	21	22	7	Left in uterus.

<sup>1</sup> No hemorrhage.<sup>2</sup> Two blighted fetuses.<sup>3</sup> Died, hemorrhage.<sup>4</sup> Estimated.<sup>5</sup> Previously starved during last half of pregnancy (table 1). Died, hemorrhage.

TABLE 3.—Female albino rats starved from the eleventh day after copulation, no litters resulting.

Rat B 35 was 131 days old; age of others unknown.

Series and No.	Parity: M, multipara; V, virgin.	Weight at time of copulation.	Weight at end of starvation.	Loss of weight.	Amount of food during starvation.	Days after copulation when swellings in uterine horns were palpable.	Days starved.	Result: L, lived; D, died.
A 15	M	grams. 250	grams. 219	p. ct. 13	grams. 18	11	10	L
A 16	M	171	130	24	30	10	12	L
A 17	M	155	120	23	18	No.	10	L
A 18	M	198	180	9	20	No.	7	L
A 19 <sup>1</sup>	M	175	115	34	15	No.	15	D
A 20	M	181	143	21	12	11	12	L
A 21	M	197	139	29	10	16	17	L
A 22	M	200	125	37	34	10	12	L
A 23	M	210	198	6	35	No.	9	L
A 24	M	162	131	19	10	10	10	L
A 25	M	152	122	20	30	11	11	L
A 26	M	166	134	19	21	13?	9	L
A 27	V	91	66	28	80	11	14	L
A 28	M	118	106	11	65	10	11	L
A 29	M	134	101	25	98	No.	15	L
A 60	M	278	200	28	14	12	13	L
A 61 <sup>2</sup>	M	185	155	16	8	11	9	D
A 62	M	210	165	21	43	17?	15	L
A 63 <sup>3</sup>	M	210	155	26	11	11	11	D
A 64 <sup>1</sup>	M	160	110	31	30	11	11	D
A 65	M	150	133	11	55	11	12	L
B 91	M	174	137	22	14	11	14	L
B 92 <sup>2</sup>	M	189	147	22	8	No.	8	D
B 21	M	181	139	23	12	11	12	L
B 35	V	150	109	27	10	11	10	L
B 59	M	175	112	36	12	18?	12	L
B 64 <sup>4</sup>	V	116	81	31	12	10	12	L

<sup>1</sup> No macroscopic evidence of pregnancy at autopsy.<sup>2</sup> No autopsy record.<sup>3</sup> Autopsy exposed 2 swellings in left uterine horn, 3 in right.<sup>4</sup> Refed 10 days and killed; microscopic examination showed degeneration of swellings in uterine horns.

TABLE 4.—*Individual data for rats dissected.*

Group series and No.	Sex.	Net body-weight.	Group series and No.	Sex.	Net body-weight.	Group series and No.	Sex.	Net body-weight.
GROUP I.			GROUP III.			GROUP V.		
Prenatal norms (controls):			Prenatal norms (controls):			Prenatal norms (controls):		
B67-1.1.....	F	2 0101	B45-1.7.....	M	3 0026	B29-2.3.....	F	4 0720
B17-1.3.....	F	2 0846	B15-1.2.....	M	3 0238	B80-1.2.....	M	4 3114
B27-1.1.....	F	2 1839	B76-1.3.....	M	3 0448	Average.....		
B39-1.1.....	F	2 4765	B76-1.6.....	M	3 1916	4 1917		
Average.....			B45-1.3.....	F	3 2417	Starvation tests:		
2 1962			B76-1.4.....	M	3 3211	B48-1.5.....	F	4 0100
Starvation tests:			B80-1.5.....	M	3 3548	B47-1.4.....	M	4 0477
B2-2.1.....	M	2 0098	B29-2.1.....	F	3 4858	B43-2.2.....	F	4 1475
B4-1.1.....	F	2 1321	Average.....			A5-1.1.....	M	4 2791
B58-1.1.....	M	2 1425	3 2082			A5-1.3.....	M	4 2825
B58-1.3.....	F	2 2696	Starvation tests:			B2-1.8.....	M	Incomplete
A3-1.3.....	F	2 3341	B31-1.1.....	F	3 0106	B47-1.6.....	M	4 4238
B43-1.1.....	F	2 3633	A6-1.3.....	F	3 0628	Average.....		
A6-1.1.....	F	2 3774	A6-1.2.....	M	3 0802	4 2034		
B22-1.3.....	F	2 3852	A2-1.2.....	M	3 1060			
B46-1.2.....	F	2 4510	B34-1.2.....	M	3 1439			
B58-1.4.....	M	2 4823	B48-1.4.....	F	3 1720			
Average.....			A3-1.1.....	F	3 2138			
2 2947			B2-2.2.....	F	3 2578			
GROUP II.			B38-1.1.....	F	3 3056			
Prenatal norms (controls):			A6-1.4.....	M	3 3436			
B39-1.5.....	F	2 5362	B38-1.2.....	M	3 3962			
B60-1.2.....	F	2 5674	B48-1.1.....	M	3 4134			
B76-1.5.....	F	2 6251	B9-1.1.....	F	3 4488			
B39-1.6.....	M	2 6464	Average.....					
B39-1.7.....	F	2 7762	3 2226					
B15-1.1.....	M	2 8057	GROUP IV.					
B60-1.3.....	F	2 8208	Prenatal norms (controls):					
B39-1.9.....	M	2 3282	B82-1.2.....	M	3 5233			
B45-1.2.....	F	2 9195	B80-1.3.....	F	3 5500			
B60-1.6.....	M	2 9430	B82-1.1.....	M	3 5826			
Average.....			B80-1.4.....	M	3 8268			
2 7468			B29-2.4.....	M	3 9907			
Starvation tests:			Average.....					
A2-1.3.....	M	2 5590	3 6947					
B58-1.2.....	M	2 5990	Starvation tests:					
A3-1.2.....	F	2 6057	B43-2.1.....	F	3 5023			
A4-1.1.....	F	2 6606	B34-1.7.....	F	3 5066			
B2-2.3.....	F	2 6921	B9-1.2.....	F	3 5459			
B22-1.4.....	F	2 7388	A5-1.2.....	F	3 5751			
B22-1.7.....	M	2 7393	B2-1.6.....	F	3 5891			
B22-1.6.....	F	2 7668	B65-1.2.....	M	3 6123			
B48-1.6.....	F	2 7983	B2-2.4.....	F	3 6174			
B46-1.5.....	M	2 8576	B29-1.1.....	F	3 6467			
B16-1.4.....	F	2 9288	B30-1.3.....	M	3 7585			
B2-1.7.....	F	2 9412	B2-1.8.....	M	3 7757			
A4-1.2.....	M	2 9818	B66-1.4.....	F	3 7940			
B68-1.4.....	M	2 9951	B30-1.1.....	M	3 7959			
Average.....			B43-2.3.....	M	3 8267			
2 7758			B30-1.2.....	M	3 8553			
			B47-1.5.....	F	3 8885			
			B2-2.6.....	M	3 8946			
			Average.....					
			3 6988					

TABLE 5. *Autopsy data showing changes in average body-length, tail-length, and average weight of the various systems and organs in newborn albino rats (test rats) from mothers undi-fed during the last half of pregnancy, as compared with prenatal control fetuses of the same average body-weight.*

	Group.					Average percentage difference from control.
	I.	II.	III.	IV.	V.	
Number and sex in groups.						
Controls . . . . .	M. 6, F. 4	M. 4, F. 6	M. 6, F. 2	M. 4, F. 1	M. 1, F. 1	.....
Tests . . . . .	M. 3, F. 7	M. 6, F. 8	M. 6, F. 7	M. 7, F. 9	M. 5, F. 2	.....
Average gross weight (grams):						
Controls . . . . .	2 2236	2 8096	3 2720	3 7829	4 3032	+ 1.6
Tests . . . . .	2 3529	2 8148	3 3011	3 7398	4 3013	.....
Per cent diff . . . . .	+ 5.8	+ 1.2	+ .89	- 1.1	- .01	.....
Average net weight (grams):						
Controls . . . . .	2 1962	2 7168	3 2082	3 6916	4 1917	+ 1.8
Tests . . . . .	2 2947	2 7758	3 2226	3 6988	4 2034	.....
Per cent diff . . . . .	+ 4.5	+ 1.6	+ .45	- .1	+ .28	.....
Average body-length (nose-anus) (in mm):						
Controls . . . . .	35 12	40 85	42 18	46 3	45 5	+ 1.2
Tests . . . . .	37 67	40 25	41 95	45 04	47	.....
Per cent diff . . . . .	+ 7.3	- 1.5	- .55	- 6	+ 3	.....
Average tail length (mm):						
Controls . . . . .	11 87	11 76	13 20	13 9	13 51	+ 6
Tests . . . . .	12 2	12 5	13 64	14 64	15 28	.....
Per cent diff . . . . .	+ 2.8	+ 6.4	+ 3.4	+ 5.3	+13.1	.....
Average head weight (grams):						
Controls . . . . .	.5313	.6306	.7284	.7743	.8663	+ 5.3
Tests . . . . .	.5460	.6085	.7564	.8249	.9257	.....
Per cent diff . . . . .	+ 2.8	+ 6	+ 3.8	+ 6.5	+ 7.6	.....
Average weight fore limbs (grams):						
Controls . . . . .	1172	1879	2359	2476	2988	+ 8
Tests . . . . .	1568	1892	2306	2701	2945	.....
Per cent diff . . . . .	+34	+ .7	- 2.3	+ 9.1	- 1.1	.....
Average weight hind limbs (grams):						
Controls . . . . .	1137	1739	2173	2604	2976	+19.5
Tests . . . . .	1548	2076	2366	2945	3334	.....
Per cent diff . . . . .	+36.4	+19.5	+ 8.9	+13	+20	.....
Average weight trunk (grams):						
Controls . . . . .	1 4339	1 7544	2 0355	2 4122	2 7350	+ 1.6
Tests . . . . .	1 4370	1 7244	2 0666	2 3530	2 6396	.....
Per cent diff . . . . .	+ .22	- 1.7	- 1.4	- 2.4	- 2.7	.....
Average weight integument (grams):						
Controls . . . . .	2411	3519	4307	5137	5938	+10.4
Tests . . . . .	2844	3746	4930	5669	6103	.....
Per cent diff . . . . .	+18	+ 6.5	+11.5	+10.4	+ 2.8	.....
Average weight skeleton (moist) (grams):						
Controls . . . . .	1570	1969	2388	2632	2786	+ 6.7
Tests . . . . .	1143	1934	2267	2642	2788	.....
Per cent diff . . . . .	-27.2	- 1.8	- 5.1	+ 4	+ 1	.....
Average weight skeleton (dry) (grams):						
Controls . . . . .	6312	9120	9487	10619	9663	+12
Tests . . . . .	9334	9505	9556	10676	10725	.....
Per cent diff . . . . .	+ 7	+20	+14	+ 9	+ 9	.....
Average weight musculature (grams):						
Controls . . . . .	6124	8722	1 0343	1 3167	1 5718	+ 5
Tests . . . . .	6525	8246	1 0004	1 2218	1 4083	.....
Per cent diff . . . . .	+ 6.6	- 5.5	- 3.3	- 9.3	-11	.....
Average weight visceral group (grams):						
Controls . . . . .	5079	5831	5948	7190	7830	+18.4
Tests . . . . .	3706	4600	5350	5987	6377	.....
Per cent diff . . . . .	-27	-21	- 7	-17	-20	.....
Average weight "remainder" (grams):						
Controls . . . . .	16776	7382	8849	8517	9644	+25.4
Tests . . . . .	8432	9398	9876	1 0314	1 2775	.....
Per cent diff . . . . .	+24.5	+27.3	+11.6	+21	+32.5	.....
Average weight brain (grams):						
Controls . . . . .	1357	1539	1614	1777	1855	+12.5
Tests . . . . .	1523	1726	1818	1960	2088	.....
Per cent diff . . . . .	+12.3	+12.2	+12.7	+13	+12.6	.....
Average weight spinal cord (grams):						
Controls . . . . .	0245	0275	0290	0306	0316	+ .26
Tests . . . . .	0259	0280	0277	0298	0312	.....
Per cent diff . . . . .	+ 6	+ 2	- 5	- 3	- 1.3	.....



TABLE 5.—Autopsy data showing changes in average body-length, tail-length, and average weight of the various systems and organs in newborn albino rats (test rats) from mothers underfed during the last half of pregnancy, as compared with prenatal control fetuses of the same average body-weight—continued.

	Group.					Average percentage difference from control.
	I.	II.	III.	IV.	V.	
Average weight eyeballs (grams):						
Controls.....	.0084	.0115	.0133	.0139	.0154	+31.4
Tests.....	.0131	.0144	.0160	.0179	.0192	.....
Per cent diff.....	+56	+26	+21	+29	+25	.....
Average weight thymus (grams):						
Controls.....	.00247	.00360	.00410	.00490	.00495	-21
Tests.....	.00177	.00240	.00360	.00410	.00420	.....
Per cent diff.....	-29	-33	-12	-16	-15	.....
Average weight heart (grams):						
Controls.....	.0107	.0141	.0157	.0183	.0185	+8.4
Tests.....	.0125	.0146	.0172	.0193	.0205	.....
Per cent diff.....	+17	+4	+10	+6	+11	.....
Average weight lungs (grams):						
Controls.....	.0621	.0751	.0734	.0737	.0882	-39.4
Tests.....	.0285	.0419	.0443	.0566	.0564	.....
Per cent diff.....	-54	-44	-40	-23	-36	.....
Average weight liver (grams):						
Controls.....	.2190	.2372	.2187	.2987	.3208	-45
Tests.....	.0939	.1255	.1497	.1819	.1846	.....
Per cent diff.....	-57.4	-47.1	-39.9	-39.2	-42.6	.....
Average weight spleen (grams):						
Controls.....	.0017	.0023	.0041	.0052	.00655	+34
Tests.....	.0023	.0033	.0052	.0064	.00868	.....
Per cent diff.....	+35	+48	+27	+23	+37	.....
Average weight stomach (full) (grams):						
Controls.....	.0444	.0407	.0476	.0451	.0740	-3.7
Tests.....	.0427	.0405	.0490	.0465	.0444	.....
Per cent diff.....	+19.7	-.4	+3	+3	-11	.....
Average weight stomach (empty) (grams):						
Controls.....	.0067	.0102	.0125	.0136	.0158	+5.6
Tests.....	.0077	.0105	.0129	.0139	.0165	.....
Per cent diff.....	+15	+3	+3.1	+2.1	+5	.....
Average weight intestines (full) (grams):						
Controls.....	.0341	.0530	.0618	.0909	.0980	+14.8
Tests.....	.0421	.0618	.0808	.0903	.0999	.....
Per cent diff.....	+24	+17	+31	-6	+2	.....
Average weight intestines (empty) (grams):						
Controls.....	.0139	.0207	.0242	.0342	.0446	-2
Tests.....	.0135	.0197	.0306	.0302	.0375	.....
Per cent diff.....	-3	-5	+27	-12	-16	.....
Average weight pancreas (grams):						
Controls.....	.0077	.0105	.0113	.0165	.0176	-2
Tests.....	.0070	.0103	.0135	.0138	.0191	.....
Per cent diff.....	-10	-2	+20	-16	+9	.....
Average weight suprarenals (grams):						
Controls.....	.00095	.00137	.00152	.00180	.00195	-51.8
Tests.....	.00059	.00063	.00071	.00090	.00100	.....
Per cent diff.....	-38	-69	-53	-50	-49	.....
Average weight kidneys (grams):						
Controls.....	.0128	.0173	.0173	.0262	.0291	+6.1
Tests.....	.0127	.0185	.0221	.0248	.0295	.....
Per cent diff.....	-7	+7	+28	-5	+1.3	.....
Average weight testes (grams):						
Controls.....	.....	.00142	.00150	.00154	.00160	+15.6
Tests.....	.0006	.00145	.00180	.00177	.00202	.....
Per cent diff.....	.....	+2	+20	+15	+26	.....
Average weight epididymides (grams):						
Controls.....	.....	.00057	.00063	.00074	.00050	+17
Tests.....	.00035	.00068	.00056	.00075	.00068	.....
Per cent diff.....	.....	+20	-12	+19	+36	.....
Average weight ovaries (grams):						
Controls.....	.00033	.00041	.00080	.00040	.0003	+1.3
Tests.....	.00055	.00043	.00051	.00041	.0004	.....
Per cent diff.....	+68	+6	-37	+2.5	-33	.....
Average weight thyroid (grams):						
Controls.....	.00080	.00083	.00083	.00108	.00120	-29.2
Tests.....	.00054	.00060	.00074	.00077	.00066	.....
Per cent diff.....	-33	-28	-11	-29	-45	.....

TABLE 6.-Average percentage changes in weight of systems and organs in albino rats during prenatal and postnatal inanition.

Normal control fetuses of same body-weight used for comparison with newborn from mothers underfed during last half of pregnancy. In postnatal inanition, younger normal controls of same body-weight were used, excepting the adult rats, where controls of the same initial body-weight were used.

Description.	Prenatal inanition. Newborn rats from mothers underfed during last half of pregnancy. Mothers' loss 11 to 39 p. ct. of body-weight. Average 40 p. ct. retardation in body-weight of newborn.	Postnatal inanition.							
		Young rats.						Adult rats.	
		Held at birth wt. av. 16 da.; body-wt. 5 gms. (Stewart, 1918a).	Underfed from birth to 3 wks.; body-wt. 10 gms. (Stewart, 1918).	Underfed from birth to 10 wks.; body-wt. 15 gms. (Stewart, 1918).	Underfed from age 3 to 10 wks.; body-wt. 24 gms. (Jackson, 1915a).	Underfed from age 2 wks. to 1 yr.; body-wt. 52 gms. (Stewart, 1918).	Underfed from 10 wks. to 8 mo.; body-wt. 80 gms. (Jackson, 1915a).	Acute inanition; body-loss 33 p. ct. (Jackson, 1915).	Chronic inanition; body-loss 36 p. ct. (Jackson, 1915).
		Systems.							
		<i>p. ct.</i>	<i>p. ct.</i>	<i>p. ct.</i>	<i>p. ct.</i>	<i>p. ct.</i>	<i>p. ct.</i>	<i>p. ct.</i>	<i>p. ct.</i>
"Remainder"	+25	-59	-40	-23	-2	-33	-5	-28	-44
Integument	+10	+25	+0	-48	-36	-14	-16	-31	-39
Musculature	-5	+6	+8	+10	+3	+4	+25	-31	-41
Skeleton	-7	+19	+19	+24	+28	+32	+0.2	-0.4	+2
Visceral group	-18	+16	+28	+38	+1	+1	-21	-40	-36
		Organs.							
Spleen	+34	+38	-49	+24	-42	-5	-1	-51	-29
Eyeballs	+31	+146	+41	+66	+50	+73	+54	-4	-6
Epididymides	+17	+225	+95	-6	.....	-32	.....	.....	.....
Testes	+16	+374	+188	+51	+31	-42	+2	-30	-40
Brain	+12.5	+125	+60	+8	-0.5	+4	+0	-5	-7
Heart	+8	+26	-5	+27	-1	-10	-6	-28	-33
Kidneys	+6	+90	+21	+38	+1	-6	-7	-26	-27
Stomach	+6	.....	.....	.....	.....	.....	.....	.....	.....
Intestines	-7	+10	+17	+100	+28	-27	-26	-57	-57
Pancreas	-0.2	.....	.....	.....	.....	.....	.....	.....	.....
Ovaries	+1.3	+5	+83	+54	-27	+47	-54	+22	.....
Spinal cord	-0.26	+83	+70	+70	+36	+10	+36	-0	-4
Thymus	-21	-49	-30	-80	-90	-90	.....	.....	.....
Thyroid	-29	+8	+5	+1	-24	-36	-62	-0	-22
Lungs	-39	+3	-26	-26	-15	+28	-13	-31	-40
Liver	-45	-23	+17	+64	+10	-7	-39	-58	-43
Suprarenals	-52	+5	+60	+114	+26	+18	-26	+2	-9

## BIBLIOGRAPHY.

- VON BECHTEREW, W., 1895. Über den Einfluss des Hungerns auf die neugeborenen Thiere, insbesondere auf das Gewicht und die Entwicklung des Gehirns. *Neurol. Centralblatt*, Bd. 14, S. 810-817.
- CONROW, S. B., 1915. Cited by Donaldson 1915.
- DANIEL, J. F., 1910. Observations on the period of gestation in white mice. *Jour. Exper. Zool.*, vol. 9, No. 4.
- DONALDSON, H. H., 1911. The effect of underfeeding on the percentage of water, on the ether-alcohol extract, and on the medullation in the central nervous system of the albino rat. *Jour. Comp. Neur.*, vol. 21, No. 2.
- , 1915. The rat. Reference tables and data for the albino rat and Norway rat. *Memoirs of the Wistar Institute of Anatomy and Biology*, No. 6, Philadelphia, 1915.
- EVVARD, J. M., 1912. Nutrition as a factor in fetal development. *Proceedings American Breeders' Association*, vol. 8, pp. 549-560.
- , A. W. DOX, AND S. C. GUERNSEY, 1911. The effect of calcium and protein fed pregnant swine upon the size, vigor, bone, coat, and condition of the offspring. *Am. Jour. Physiology*, vol. 34, pp. 312-325.
- HART, E. B., E. V. MCCOLLUM, H. STEENBOCK, AND G. C. HUMPHREY, 1919. Balanced rations from restricted sources. Their physiological effect on growth and reproduction. *Scientific American Supplement*, No. 2256, pp. 202-203. See *Research Bulletin No. 17*, Univ. of Wis. Agr. Experiment Station, June 1914.
- HATAI, S., 1904. The effect of partial starvation on the brain of the white rat. *Am. Jour. Physiology*, vol. 12.
- , 1908. Preliminary note on the size and condition of the central nervous system in albino rats experimentally stunted. *Jour. Comp. Neur.*, vol. 18.
- , 1913. On the weights of the abdominal and thoracic viscera, the sex glands, ductless glands, and the eyeballs of the albino rat (*Mus norvegicus albinus*) according to body-weight. *Am. Jour. Anat.*, vol. 15.
- , 1914. On the weight of the thymus gland of the albino rat (*Mus norvegicus albinus*) according to age. *Am. Jour. Anat.*, vol. 16.
- , 1915. The growth of the body and organs in albino rats fed with a lipid-free ration. *Anat. Rec.*, vol. 9.
- , 1918. On the weight of the epididymis, pancreas, stomach, and of the submaxillary glands of the albino rat (*Mus norvegicus albinus*) according to body-weight. *Am. Jour. Anat.*, vol. 24.
- HUBER, G. CARL, 1915. The development of the albino rat (*Mus norvegicus albinus*). Part I. From the pronuclear stage to the stage of mesoderm Anlage; end of the first to the end of the ninth day. *Jour. Morph.*, vol. 26.
- JACKSON, C. M., 1909. On the prenatal growth of the human body and the relative growth of the various organs and parts. *Am. Jour. Anat.*, vol. 9, No. 1.
- , 1913. Postnatal growth and variability of the body and of the various organs in the albino rat. *Am. Jour. Anat.*, vol. 15.
- , 1915. Effect of acute and chronic inanition upon the relative weights of the various organs and systems of adult albino rats. *Am. Jour. Anat.*, vol. 18.
- , 1915a. Changes in the relative weights of the various parts, systems, and organs of young albino rats held at a constant body-weight by underfeeding for various periods. *Jour. Exper. Zool.*, vol. 19.
- JACKSON, C. M., AND L. G. LOWREY, 1912. On the relative growth of the component parts (head, trunk, and extremities) and systems (skin, skeleton, musculature, and viscera) of the albino rat. *Anat. Rec.*, vol. 6.
- JACKSON, C. M. AND C. A. STEWART, 1918. The effects of underfeeding and refeeding upon the growth of the various systems and organs of the body. *Minnesota Medicine* (cf. also *Jour. Exper. Zool.*, 1920, 30: 97-128).
- JONSON, A., 1909. Studien über die Thymusinvolution. Die akzidentelle Involution bei Hunger. *Arch. f. mikr. Anat.*, Bd. 73, S. 390-443.
- KING, HELEN D., 1913. Some anomalies in the gestation of the albino rat (*Mus norvegicus albinus*). *Biol. Bull.*, vol. 24.
- , 1915. On the weight of the albino rat at birth and the factors that influence it. *Anat. Rec.*, vol. 9.
- , 1916. On the postnatal growth of the body and of the central nervous system in albino rats that are undersized at birth. *Anat. Rec.*, vol. 11.
- KING, HELEN D., AND J. M. STOTSENBERG, 1915. On the normal sex ratio and the size of the litter in the albino rat (*Mus norvegicus albinus*). *Anat. Rec.*, vol. 9.
- KIRKHAM, WILLIAM B., AND H. S. BURR, 1913. The breeding habits, maturation of eggs, and ovulation of the albino rat. *Am. Jour. Anat.*, vol. 15, pp. 291-317.
- LATASTE, FERNAND, 1891. Des variations de durée de la gestation chez les mammifères et des circonstances qui déterminent ces variations. *Comp. Rend. Soc. de Biol., Paris*, T. 43, pt. 2, pp. 21-31.
- LOWREY, G. L., 1911. Prenatal growth of the pig. *Am. Jour. Anat.*, vol. 12.
- , 1913. The growth of the dry substance in the albino rat. *Anat. Rec.*, vol. 7.
- MÜHLMANN, M., 1899. Russische Literatur über die Pathologie des Hungerns (der Inanition). Zusammen fassen des Referat, *Centralbl. f. allg. Pathologie*, Bd. 10, S. 160-220; 210-242.
- OSBORNE, THOMAS B., AND L. B. MENDEL, 1914. Nutritive properties of proteins of the maize kernel. *Jour. Biol. Chem.*, vol. 18.

- PATON, D. NOEL, 1903. The influence of diet in pregnancy on the weight of the offspring. *The Lancet*, vol. 4, pp. 21-22.
- PROCHOWNICK, L., 1889. Ein Versuch zum Ersatze der künstlichen Frühgeburt. *Centrabl. f. Gynäk.*, Bd. 13, S. 577-581.
- , 1901. Über Ernährungsreue in der Schwangerschaft. *Therapeut. Monatshefte*, Bd. 15, S. 387-403; 416-463.
- REEB, M., 1905. Über den Einfluss der Ernährung der Muttertiere auf die Entwicklung ihrer Früchte. *Beitr. z. Geburt. u. Gynäk.*, Bd. 9, S. 395-411.
- RUDOLSKI, L. V., 1893. On pregnancy in animals in cases of insufficient nourishment of the organism: experimental investigations performed upon rabbits and a dog. (Russian.) *Dissert.* St. Petersburg, 1893. Also cited by Muhlbmann, 1899.
- STEWART, C. A., 1918. Changes in the relative weights of the various parts, systems, and organs of young albino rats underfed for various periods. *Jour. Exper. Zool.*, vol. 25.
- , 1918a. Changes in the weights of the various parts, systems, and organs in albino rats kept at birth-weight by underfeeding for various periods. *Am. Jour. Physiol.*, vol. 48.
- STOITSBERG, J. M., 1914. Cited by Donaldson, 1915.
- , 1915. The growth of the fetus of the albino rat from the thirteenth to the twenty-second day of gestation. *Anat. Rec.*, vol. 9.

---

CONTRIBUTIONS TO EMBRYOLOGY, No. 54.

---

A CASE OF TRUE LATERAL HERMAPHRODITISM IN A PIG  
WITH FUNCTIONAL OVARY.

BY GEORGE W. CORNER,  
*Of the Anatomical Laboratory, Johns Hopkins Medical School.*

---

With one plate.



# A CASE OF TRUE LATERAL HERMAPHRODITISM IN A PIG WITH FUNCTIONAL OVARY.

BY GEORGE W. CORNER.

That variety of true hermaphroditism which is characterized by the presence of an ovary on one side and a testis on the opposite side is one of the rarest forms of structural abnormality of the genitalia. No undoubted cases have yet been reported in man, and but two instances have been observed in swine. Some idea of the rarity of the condition may be gained from the results of a systematic examination of 500,000 swine made in the Berlin municipal abattoir, under the direction of Ludwig Piek (1914). In this series of animals five cases of hermaphroditism were observed, but none of them was of the lateral variety, a mixed gland (ovotestis) on one or both sides being present in each.

Reuter (1885) described the case of a two months' old pig, discovered among a litter which also contained two pseudohermaphrodites. This animal possessed a right testis and a left ovary. The ovary was very small but contained ova in primordial follicles; the testis contained numerous interstitial cells, but apparently there were no germ-cells in the tubules. On the side on which the testis was located the uterus ended in a rudimentary Fallopian tube.

Kingsbury (1909) recorded the examination of a young adult pig with male external genitalia. There was a normal-looking uterus with a rudimentary left ovary and a large right testis with a typical epididymis. On the right side the Fallopian tube ended in a diminutive blind sac. The ovary contained a few ova in follicles; the testis had the typical structure of a cryptorchid testis, with numerous interstitial cells but without germ-cells in the tubules.

## DESCRIPTION OF SPECIMEN.

The author's specimen, consisting of the uterus, tubes, and ovaries of an adult pig, was found among a number of uteri which had been brought in from a neighboring slaughter-house for study; therefore no information is at hand concerning the history or appearance of the animal from which it came.

The uterus was normally formed (fig. 1), presenting two cornua as usual. Its size corresponded to that of the uterus of a young, sexually mature sow. On the right side the uterine cornu ended in a normal Fallopian tube in connection with a normal ovary; the latter contained four recent corpora lutea, one of them cystically dilated. On washing out the contents of the tube with saline solution, one ovum was found, normal in all respects except that the cytoplasm was slightly shrunken; one polar body had been extruded. The left uterine horn, normal in size and form, ended in a very slender tube about 1 mm. in external diameter near

the uterus, which gradually thinned down to an almost linear dimension, losing its lumen, and finally ending in the connective tissue over the epididymis (fig. 1).

On the left side, in place of an ovary there was a mass 30 by 25 by 20 mm. in diameter, of dull flesh-color, exactly resembling a testis in form, texture, and color. It was covered by a thick capsule in which large and somewhat tortuous vessels coursed; when this tunic was incised the contents bulged over the cut edges. The exposed surface was dry and granular in appearance.

On this side of the uterus there was a well-defined Wolffian duct, such as is occasionally present in sows, beginning in the vagina and running parallel to the uterine horn between the layers of the broad ligament. However, instead of ending in a cul-de-sac or in a series of minute cysts in the region of the ovarian pedicle, as this duct usually does when present in the sow, it became greatly convoluted as it approached the tip of the cornu and finally so closely coiled as to form the body indicated in figure 1. This structure presented the appearance of an epididymis by reason of its texture, its close apposition to the testis-like body, and also because of a slight constriction at the middle portion, suggesting a division into *globus major* and *minor*.

Microscopic examination fully confirmed the foregoing interpretation and proved that the specimen was indeed one of true lateral hermaphroditism. Sections of the testis (figs. 2 and 3) showed a typical tunica albuginea, within which the gland substance consisted of tubules separated by relatively wide groups of interstitial cells of normal appearance, in whose nuclei mitotic figures were occasionally found. The tubules were lined by a layer of high cells, nowhere more than one cell deep, except that here and there a nucleus lay farther from the basal margin than the others. The nuclei were of medium size and contained relatively less chromatin than those of the interstitial cells. No mitoses could be found. The cytoplasm toward the free border was frayed out into long irregular strands which were so interlaced that the lumina of the tubules seemed in most places to be filled by this vague network of protoplasmic material. Within the cell-bodies of this epithelial lining there were numerous large vacuoles. Germ-cells were totally lacking; no tubule contained any cells other than those already described, which were presumably partially degenerated Sertoli cells. The connective tissue of the testis was normal in appearance, showing no sign of the hyaline degeneration which has sometimes been seen in hermaphrodite glands. The epididymis (fig. 4) was similar in all respects to that of a normal male animal except that it contained no spermatozoa.

In order to gain a general view of the ovary it was cut into six blocks and sections were taken from each of these portions; these presented everywhere the histological structure of a normally functioning organ (fig. 5). The corpora lutea were recently formed, with the *membrana propria* broken down and the elements of the *theca interna* just beginning to invade the *granulosa*, indicating that ovulation had taken place about three days before. (For grounds for this estimate, see Corner, 1919.) This finding is, of course, in accord with the presence of an ovum in the



tube. No special significance is attached to the fact that one of the corpora lutea was slightly cystic, since this is a common occurrence in normal swine. The cortex of the ovary contained primordial ova and there were numerous follicles of normal type. Due consideration was given to the possibility that small masses of testicular tissue might be present in the ovary; that is, that the organ might be an ovotestis (as in one of Pick's cases, which macroscopically closely resembles ours), but no foreign tissue was found.

The uterine mucosa was normal and similar in both horns. From the results of studies on the cyclic changes in the uterine mucosa, now in preparation, the author feels justified in stating that the uterus of this animal presented the microscopic features characteristic of the period of œstrus.

#### DISCUSSION.

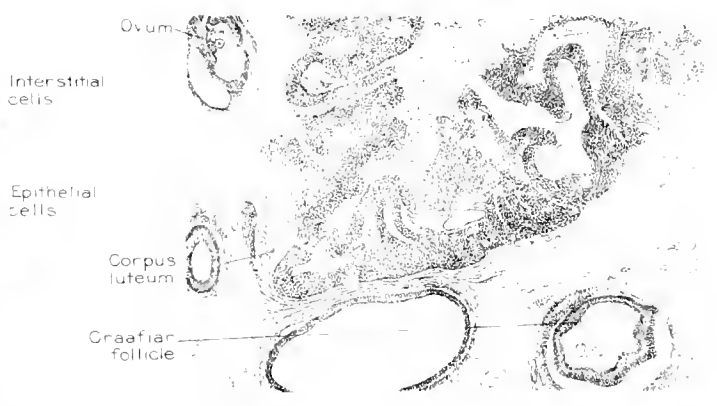
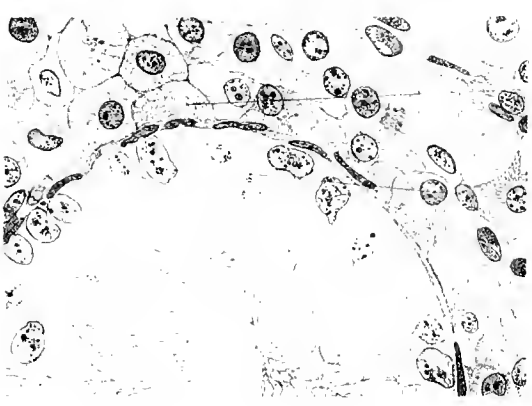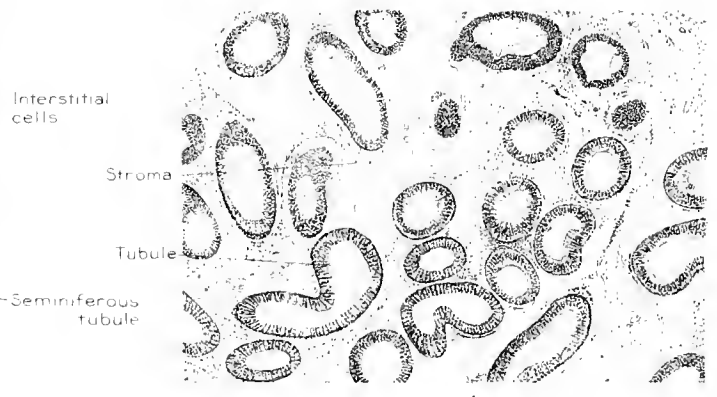

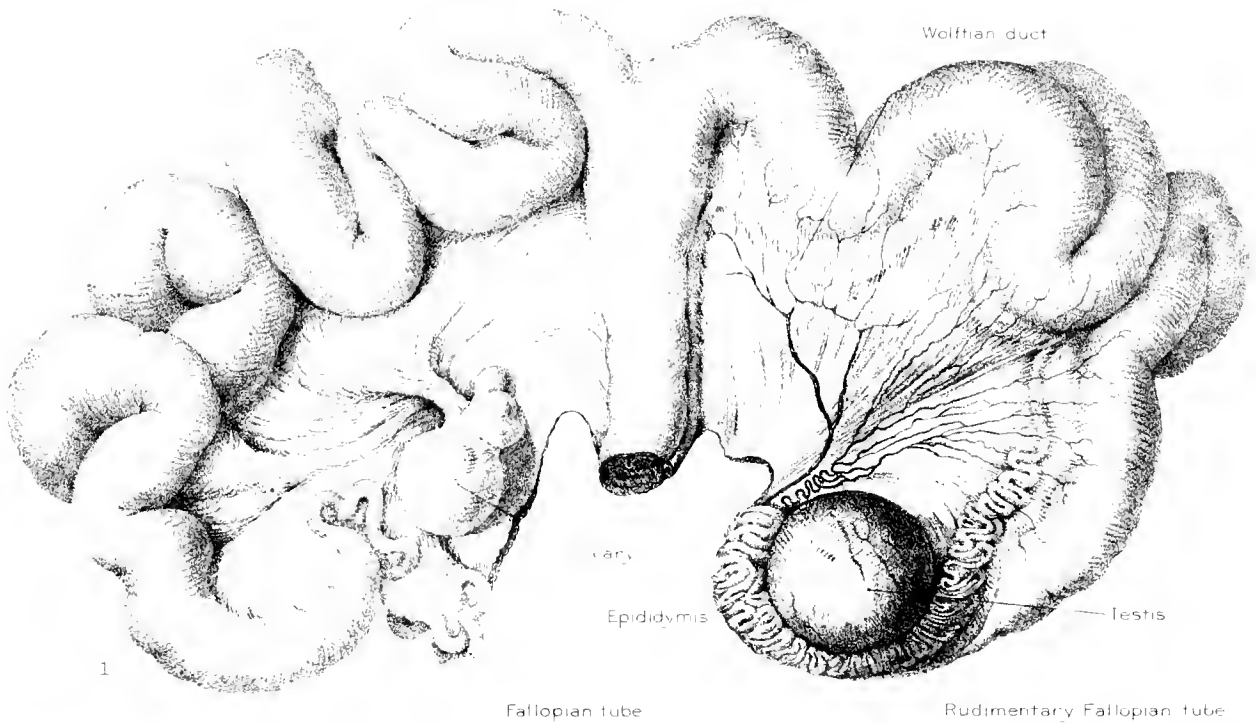
Owing to the fortunate circumstance that this pig passed into the butcher's hands as a sexually mature animal just after an ovulation had occurred, we have had a unique opportunity to study the physiological state of the ovary; indeed, this is apparently the first sure case of glandular hermaphroditism in which there is direct evidence of the discharge into the deferent duct of germ-cells from either gonad.

In the presence of a normal ovary containing very early corpora lutea, an ovum in passage through the Fallopian tube, and a full-sized uterus histologically normal, it seems more simple to consider this animal as functionally a female (at least as far as the internal genitalia are concerned) in which a local malformation had substituted a functionless testis and an epididymis for one ovary and the corresponding oviduct. In this respect the conditions are much like those of the previously described examples of true hermaphroditism in swine (now numbering about fifteen), in each of which the internal genitalia have been feminine as to gross morphology, with a more or less well-developed uterus and a testis or ovotestis in the anatomical position of the ovary. The opposite type of hermaphroditism—the presence of an ovary or ovotestis at the usual site of the testis, with the genital duct system resembling the male type—should it occur, is far less likely to be observed by the anatomist because of the general custom of castration of boars intended for the butcher. In three of the four cases in man, however, which were summarized in the comprehensive review of L. Pick (1914), the hermaphrodite gland was found in the inguinal canal. The male gland of our specimen was not dissimilar to those of other cases. The close resemblance to the testes of ridglings, the absence of germ-cells, the relatively numerous interstitial cells, the remarkably complete epididymis, the persistent Wolffian duct, have all been commented upon in previous reports. So fully elaborated and indubitable a male apparatus as this must at once dispose of contentions such as that of Kermauer (1912), that the germ-lacking organs of supposed hermaphrodites are merely examples of non-differentiation from a neutral state of the gonadal primordium. In view of the current debate as to the early history of the germ-cells in mammals, great interest

attaches to the question as to whether these gamete-free testes of hermaphrodites at any time in their development contained spermatogonia; and upon the answer to this depend the further questions as to why the ova seem always to survive at the expense of the spermatozoa, and in what manner the male germ-cells are inhibited; but these questions must await experimental attack or the chance discovery of embryonic stages of glandular hermaphroditism.

## REFERENCES CITED.

- |  |  |
|--|--|
| <p>CORNER, G. W., 1919. On the origin of the corpus luteum of the sow from both granulosa and theca interna. <i>Am. Jour. Anat.</i> 26, 117-183.</p> <p>KERMAUNER, F., 1912. <i>Sexus anceps</i> oder Hermaphroditismus. <i>Frankf. Zeitschr. f. Pathol.</i> 11.</p> <p>KINGSBURY, B. F., 1909. Report of a case of hermaphroditism (H. verus lateralis) in <i>Sus scrofa</i>. <i>Anatomical Record</i>, 3, 278-282.</p> | <p>PICK, L., 1911. Ueber den wahren Hermaphroditismus des Menschen und der Säugetiere. <i>Arch. f. mikr. Anat.</i> 84, 2 Abt. 119-242.</p> <p>REUTER, J., 1885. Ein Beitrag zur Lehre von Hermaphroditismus. <i>Verh. d. phys. med. Gesellsch. zu Würzburg</i>, N. F. xix.</p> |
|--|--|



J. F. Didusch fecit

A. Hoeen & Co imp

(1) General view of specimen; X 0.75. (2) Section of testis showing relative proportions of tubular and interstitial cells; X 28; hematoxylin and eosin. (3) Section of testis showing details of structure; X 1300; iron hematoxylin. (4) Section of epididymis showing normal character of tissue; X 80; hematoxylin and eosin. (5) Section of ovary showing several small Graafian follicles and part of an early corpus luteum; X 15, hematoxylin and eosin. These figures were drawn directly on stone from the gross specimen and from the sections.



---

CONTRIBUTIONS TO EMBRYOLOGY, No. 55.

---

WEIGHT, SITTING HEIGHT, HEAD SIZE, FOOT LENGTH, AND  
MENSTRUAL AGE OF THE HUMAN EMBRYO.

BY GEORGE L. STREETER,  
*Of the Department of Embryology, Carnegie Institution of Washington.*

---

With 2 figures and 6 charts.

## CONTENTS.

	PAGE.
Fixation .....	146
Measurement .....	148
Age .....	150
Summary of data. ....	152
Mean sitting height and weight .....	152
Relation of increment in weight to sitting height .....	153
Relative variation in sitting height and weight .....	154
Foot length.....	156
Head modulus .....	157
Bibliography.....	159
Tables 6 and 7.....	160
Charts 1 to 6.....	

# WEIGHT, SITTING HEIGHT, HEAD SIZE, FOOT LENGTH, AND MENSTRUAL AGE OF THE HUMAN EMBRYO.

---

BY GEORGE L. STREETER.

---

Before any satisfactory growth curve for the human embryo can be constructed, or the normal range of its variations in the different stages of development can be determined, more abundant and better data are necessary, as has long been apparent to those concerned with this problem. As a means towards this end, all of the embryological material received at this laboratory during the past five years has been systematically weighed and measured and, in order that the individual records may be comparable, the methods and conditions have been maintained as nearly uniform as possible; in fact, the determinations were made for the most part by the same person. The data thus derived from 704 selected specimens have been tabulated and plotted in the form of fields and graphs and are now presented in the hope that, in addition to their value in the study of normal growth, they may be of aid in the recognition of such abnormal and pathological processes as are frequently met with in specimens from abortions. Furthermore, since much of the material was accompanied by clinical records of the menstrual age, it has been possible to construct an age scale which can be read for weight and size simultaneously. The consideration of both of these factors will make it possible to estimate more accurately than heretofore the age of embryological specimens, it having been necessary in the past to base the estimation either on size or on weight alone. Further than the making of a few selected measurements which can be easily carried out in any laboratory, no attempt is made in this paper to enter into a more detailed anthropological consideration of fetal growth. That important field is at present being studied by Dr. A. H. Schultz, who has made comprehensive observations upon these and additional specimens.

The ideal material for determining the curves of fetal length, weight, and age would be living specimens (examined in the fresh state) which had been removed by operation at chosen intervals in cases where there was a recorded single coition immediately following menstruation. With abundant material of this character from normal individuals of the same age, stature, race, and living conditions, each of whom had previously borne the same number of children, we might well expect perfect results. However, these requirements, although they can be met in all other mammals, can not be met in man. In the latter, therefore, we must be content with conditions that are as nearly constant as possible for the bulk of the material obtainable. The observations reported in the literature can not be assembled satisfactorily because of lack of uniformity in the technique adopted by the various observers in making measurements and in the method of preserving the material. The data on age are usually scant and the criteria as to whether or not the specimens are normal are frequently unreliable. The best available data are

those obtained from obstetrical clinics, where most of the material is from the last three months of pregnancy. In such cases the records of weight can be safely relied upon, but the measurements of the fetus are less accurate because they are not uniformly made, being done by many different and untrained observers and without the aid of proper instruments. Comprehensive data for the later months of pregnancy, obtained through cooperation with the obstetrical department of the Johns Hopkins Hospital, have been published by Meyer (1915); his 2,394 cases were white and negro in about equal proportions. The study of Zangemeister (1911) is also to be commended, particularly because of its convenient graphic presentation. His paper includes the weight and length of the fetus and the weight of the various organs, together with the normal limits of variation, based upon averages obtained from the literature and his own observations. For the earlier part of pregnancy the studies of Mall (1910, 1918), though composite, contain the best data we have on the size and age of embryos under 100 mm. long.

The fact that in this laboratory there is a continuous accession of embryos of all stages of development has made it possible to inaugurate a plan of systematic measuring and weighing of each specimen by which the factors involved are kept relatively constant. Toward this end the following precautions were observed with respect to the selection, fixation, and measurement of the material: In the first place, only normal specimens were used and these were classified in three grades, depending on the condition in which they were received. Those that showed no injury and in which the tissues were practically living at the time of fixation were classed as grade 1. Those in which the preservation was not perfect or which had been slightly injured in some way were classed as grade 2. Under grade 3 were grouped the poorest specimens, including those that showed some maceration of the tissues or mechanical injuries, though where these conditions were extensive enough to essentially alter the normal character of the specimen it was not utilized for purposes of tabulation. These grades are illustrated in figure 1.

#### FIXATION.

Although in much of our material record was made of the weight and measurements of the fresh specimen, many of the specimens were sent to us already fixed in formalin and it was necessary, therefore, to accept the formalin state as a basis for the group as a whole. Furthermore, since formalin is in general use in other laboratories, this basis will facilitate the comparison of our observations with those of other workers. It is to be remembered, however, when working with formalin material, that the preservative introduces an artificial element which must be taken into account. Young, fresh specimens, when placed in a 10 per cent formalin solution, quickly take up the fluid, becoming tensely distended, so that they increase markedly in weight and to some extent in length. In older specimens, and those in which the tissues are macerated, the distention is not so great. A specimen, after being distended by the solution, in the course of a few months tends to gradually regain its original size and weight. Owing to the character of the subcutaneous tissues of the scalp and head, the size of the head under these conditions



is more affected than that of the trunk or extremities; thus the head modulus, which is normally less than the sitting height, may temporarily exceed it, due to the formalin distention. In the subsequent shrinkage a fetus of 146 mm. CR, for instance, will regain its normal proportions within 16 months. These changes in the embryo due to formalin preservation have been described by Schultz (1919).

To obviate, as far as possible, discrepancies due to formalin, we have made it a rule to record the weight and measurements at about the end of the second week after the specimen has been placed in the fixative. Even with this precaution it will be seen that the distended specimen tends to fall below the curve; that is, to have a greater weight than it should have for its length, as compared with the aver-

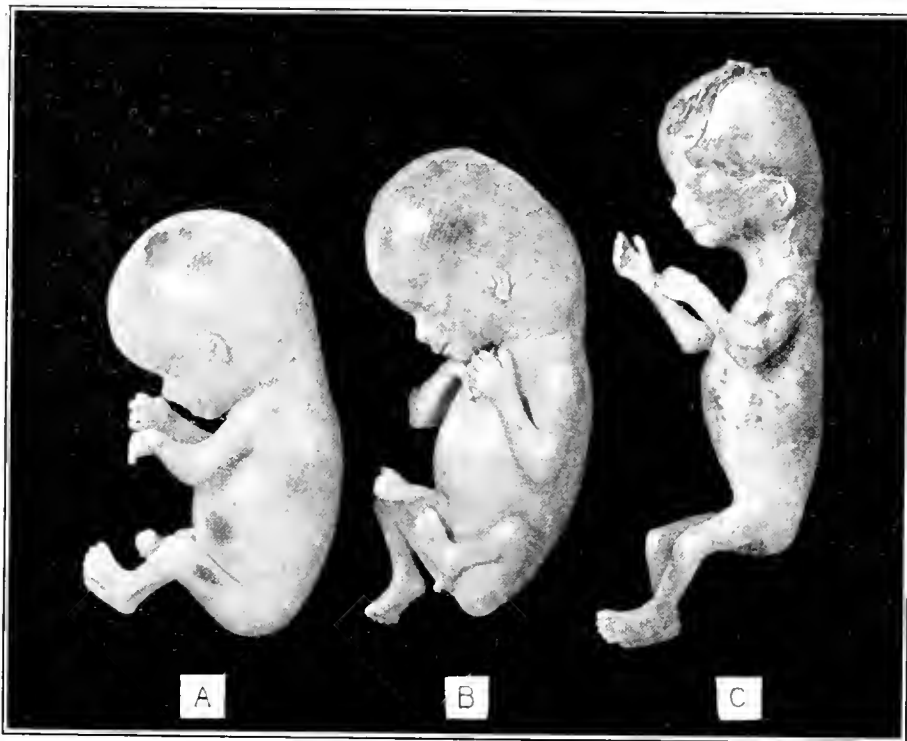

FIG. 1.—Normal fetuses showing the three grades under which they are grouped. A, grade 1, fetus No. 1183, CR length 60 mm., weight 19.5 grams; B, grade 2, fetus No. 1282b, CR length 65.5 mm., weight 18 grams; C, grade 3, No. 1210, CR length 66 mm., weight 14.2 grams. A is shorter and manifestly younger than the other two, but owing to its extreme distention by formalin, it weighs more.

age specimen; on the other hand, macerated specimens rise above the mean curve—that is, they are not heavy enough for their length. This is illustrated in figure 1, in which are shown three fetuses having the following respective measurements and weights: A (No. 1183), 60 mm. long, 19.5 grams; B (No. 1282b), 65.5 mm. long, 18 grams; and C (No. 1210), 66 mm. long, 14.2 grams. Fetus B shows about the average formalin distention, and although it is a little longer and older than fetus A, the latter weighs more as a result of its tense distention in formalin, which is always the case in such particularly fresh, grade 1 specimens. Fetus C, a grade 3 specimen, is the longest of the three, although it weighs considerably less than either of the others. Its great length relative to its weight is due in part to the fact

that it was stretched unusually straight, and in part to the fact that it shows no formalin distention, owing to the moderate maceration of its tissues. Fetus B would fall in closely with our mean curve, fetus A well below the curve, and fetus C considerably above the curve.

If it were not for the effect of the preservative, the correlation field would be even more compact than it is. In other words, there is probably less variation between the weight and length than is indicated in our charts.

Some fetuses of over 400 grams weight were embalmed with a 10 per cent formalin solution injected through the umbilical artery. These are indicated in the tables. Here the artificial increase in weight is considerable and these specimens can not be fairly compared with those simply immersed in formalin. In such cases, therefore, the fresh weight was used, plus 5 per cent as the equivalent of the average increase due to formalin immersion based on the experiments of Schultz (1919). The size recorded in these cases is that of the fresh specimen.

#### MEASUREMENT.

Three measurements were selected for the purpose of correlation with weight. The sitting height or crown-rump length (Mall) was taken as of primary importance, inasmuch as it can be satisfactorily made from the youngest stages to term. It possesses additional advantages in that in fetuses it can be determined more accurately than the standing height and that it eliminates the individual variations in the length of the lower extremities. In larger specimens the only precautions found to be necessary were to hold the body straight and, in those of the last three months of pregnancy, to keep the posture of the head uniform, which was done by placing the head so that the eye-ear line was perpendicular to the axis of the body.

Where the fetus had been hardened in an extremely flexed position, so that an accurate, straight measurement could not be obtained, the sitting height was not charted; and where the curvature of the body was less marked the specimen was entered with an explanatory note in the tables. Such a specimen, instead of measuring 148 mm., for instance, under normal conditions would probably measure about 160 mm. and thus would tend to fall below the mean curve. On the other hand, some are stretched unusually straight before fixation, with elongation of the neck, and under these circumstances they may measure as much as 5 per cent longer than usual, thus falling above the curve. All such specimens were noted in the tables under "Remarks." Workers in other laboratories, utilizing the curves for comparison with other material, should take these factors into account and make proper allowance.

The body could be safely straightened for crown-rump measurement down to the stage of 35 or 40 mm. long. Specimens smaller than this were measured without disturbing their natural curved posture. These are indicated in the tables and in the curve given on chart 1 they are entered by *crosses* instead of the *dots* used for all straight measurements.

For measuring the crown-rump length of small embryos, where it is desired to obtain readings involving fractions of a millimeter, it is important to have some device more accurate than small calipers. No matter how careful one might be,

it is not possible to so control the caliper points that they come into perfect contact with the ends of the embryo without indenting it, or without incurring the risk of injuring the specimen. The difficulties are increased by the fact that the measurement has to be carried on under fluid. To meet these conditions resort may be had to one of the simpler types of measuring microscopes, such as are used for calibrating thermometer scales or for measuring spectrum photographs. For our own use I have found that a Leitz-Edinger brain microscope, remodeled as shown in figure 2, answers the purpose very satisfactorily.




FIG. 2.—Instrument for measuring embryos. X, Leitz No. 9 eyepiece with cross-hairs; Z, 70 mm. Zeiss objective; Y, glass container for embryo; V, standard on top of which the stationary plate of the Vernier scale is mounted. The reading is made from the rear of the instrument.

with which it was originally equipped was removed and in its stead was substituted a brass plate carrying a revolving table on which to place a glass dish containing the embryo to be measured. This made possible the movement of the embryo, so that it could be brought to any desired position under the observing tube. The observing tube was equipped with a 70 mm. objective and a Leitz No. 0 eyepiece having a hair-line. Through this optical system, with the tube drawn out, it was possible to see in sharp focus an entire 12 mm. embryo in a single field under a magnification of about 10 diameters. A Vernier scale, reading to 0.05 mm., was attached to the support carrying the observing tube, by means of which the excursion of the tube to the right or left could be determined.

This completed the apparatus. Its use is extremely simple. The embryo is brought to rest under the tube with the axis selected for measurement placed parallel with the frame on which the support of the tube rides. By turning the crank handle of the threaded rod, which moves the observation tube from side to side, the tube is adjusted so that the hair-line of the eyepiece is vertically sighted at one end of the embryo, as with a surveyor's theodolite, and a reading is taken on the Vernier scale. The observation tube is then moved to the other end of the embryo and another vertical reading is taken. The difference between the two readings gives the distance the tube has

moved—that is, the length of the embryo—with an accuracy of 0.05 mm. With this device one gets the same result on repeated trials; moreover, what is more important, different observers get the same result. On account of its accuracy we have found this instrument of value in testing changes in size produced by fixatives and dehydrating solutions. One must take the precaution, however, of always having the embryo placed so that its midsagittal plane is perpendicular to the axis of the observing tube. In other words, the embryo should be in true profile. The data included in this paper do not cover very small embryos, where the crown-rump length (center of mid-brain to coccygeal region) is less than the greatest body length. I may note, however, that our rule for such specimens is to use the latter measurement, for the reason that it is subject to less variation due to chance posture of the embryo.

In addition to sitting height, the head size and foot length were recorded for the purpose of correlation with weight. The head size was recorded in the form of a *head modulus*, expressed in millimeters and consisting of the mean between the greatest horizontal circumference of the head and the biauricular transverse arc. It was found convenient to measure the latter with a thin strip of paraffined paper placed at the external auditory meatus (in older specimens the tragus) of one side and extending over the apex of the head to the opposite external auditory meatus, the paper then being laid opposite a millimeter rule and the reading taken. Similar paper strips were used for obtaining the head circumference.

The foot length was found to be of value as a third measurement. This was taken with a small sliding compass, the length being measured from the posterior surface of the heel to the tip of the first or second toe, whichever was the longer. Where there was a difference in the size of the two feet the longer one was recorded. The foot is usually quite straight, but in older specimens it is sometimes flexed, and in such cases it should be held as straight as possible during the measurement.

#### AGE.

For a considerable number of our specimens we have been able to obtain a record of the menstrual age, which I have recorded in the tables. These data are sufficient to construct a satisfactory curve of mean menstrual age for the first 28 weeks of pregnancy. For the last 12 weeks resort has been had to data from other sources, thus completing the curve for the whole period of pregnancy; this is reproduced in chart 6. Based on this curve, the age has been entered for each week along the upper margins of the size-weight curves of charts 1 to 5. It is hoped that this will prove of convenience to other workers who, for clinical purposes, may have occasion to determine the age of fetuses for which no age data are available. By the use of these charts it is possible to estimate the menstrual age of a given fetus, either from weight or from any one of the plotted measurements; *i. e.*, sitting height, head-size modulus, or foot length, although, where all of these data can be used jointly in placing a specimen, the reading for age is proportionately more accurate by so doing.

From the group of 1,200 cases gathered by Mall (1918), it was found that the duration of pregnancy, when reckoned from the last menstrual period, was fully

10 days longer than when computed from the time of fruitful copulation. Mall therefore enters the copulation age in his curve of growth as a line which falls in a position 10 days less than the mean menstrual age. The copulation age in turn is to be distinguished from the ovulation age and the fertilization or true age. Unfortunately, we do not possess sufficient data for man to establish satisfactory curves for the latter two ages. For our purposes, therefore, we have taken into consideration only the menstrual age, the time from the beginning of the last menstrual period. This has the disadvantage of a considerable probable variation but, on the other hand, it has the more than compensating advantage that we are able to obtain these data for a large proportion of the material.

As stated above, our records justify an age curve for only the first 28 weeks of the fetal period. In fact, the largest part of our records concerns specimens of the first half of pregnancy. This is due to the source of our material, which is chiefly from abortions, the products of which are sent in by physicians. As a rule, the larger specimens are not sent to us. Therefore, the fact that we happen to receive a greater number of younger specimens does not justify the conclusion that interruption of pregnancy is more frequent during the earlier weeks. To construct a perfect age curve, one should have abundant data evenly distributed throughout the whole fetal period, the fetuses should have been normal and living up to the time pregnancy was interrupted, accurate records should have been kept by the physician and the patient, and furthermore the previous menstrual history of the patient should have been normal. These conditions can be adequately met only in operative cases, of which too few are thus far available. To eventually obtain such data will require the systematic cooperation of many institutions towards this end. In the meantime we must be content with an approximate result such as is given in chart 6. If the outlying dots in this chart are disregarded as due to inaccuracy of the history given by the patient, to irregularities in menstruation, or to the fact that the development of the fetus had ceased some time before its expulsion, there still remains a consistent cluster of dots along which the curve is laid.

While our collection contains fewer specimens from the later than from the earlier months of pregnancy, there is a sufficient number of the older ones to permit a fairly satisfactory correlation between sitting height and weight; unfortunately, however, the clinical records accompanying them are inadequate for the completion of the curve for the menstrual age beyond the twenty-eighth week. It has therefore been necessary to resort to data from other sources. An attempt was made to extend the curve by the use of the excellent data compiled by Meyer (1915) from 2,394 cases at the Johns Hopkins Hospital. The incorporation of his figures however, produces an irregularity in the curve that is apparently due to the large proportion of negro fetuses included among his specimens. It has been shown by Riggs (1904) that, possibly because of inferior nutrition, or perhaps other causes, the negro new-born weighs less than the white. The average weight of the new-born of 227 white multiparæ was 3,480 grams, whereas for 168 negro multiparæ it was only 3,131 grams. Since our material is predominantly white, I have used the data reported by Zangemeister (1911). In race and living conditions the cases collected from the literature by him would be fairly comparable to ours. From his

curve (p. 131) one can take the following readings: End of fortieth week, average fresh weight 3,242.4 grams; end of thirty-sixth week, 2,360 grams; end of thirty-second week, 1,600 grams. I have taken these three determinations for our curve of menstrual age, increasing them by 5 per cent to make them comparable to the formalin weight of our tables, so that they become 3,405 grams, 2,478 grams, and 1,680 grams, respectively. By the use of the correlation curve in chart 4 they were converted from formalin weight to mean sitting height for the respective menstrual ages; *i. e.*, fortieth week, 362 mm.; thirty-sixth week, 321 mm.; thirty-second week, 283 mm. These converted readings were then entered in their respective places on chart 6 as prominent circles and a smooth curve was drawn through them, uniting them with the menstrual curve from our own material of the first 28 weeks. The total curve thus obtained is probably as close an approximation as can be obtained from such records as are at present available.

Through cooperation with Professor Williams, of the Woman's Clinic of the Johns Hopkins Hospital, provision has been made for obtaining more adequate information on the relation of sitting height to menstrual age for the last 12 weeks of pregnancy. For this purpose a convenient instrument for determining sitting height has been devised by Dr. A. H. Schultz (1920), which is now in routine use in all confinements at the Johns Hopkins Hospital. It is expected that in the course of another five years sufficient data can be secured to properly verify or correct the curve of menstrual age as now given.

#### SUMMARY OF DATA.

Were our embryological material of sufficient proportions it would, of course, be desirable to divide it according to race and sex and to treat it under separate groupings; but as the number of suitable specimens available at present is only 704, no attempt at such subdivision is made in this paper. Our data could be increased by utilizing the reports of other observers, but this would introduce discrepancies, due to method or to different criteria as to what constitutes a normal fetus, which would tend to invalidate the results to a degree that would more than offset the advantage to be derived from the larger mass of material.

By far the greater number of our 704 fetuses are white, and these are about equally divided as to sex. The other races are not sufficiently represented to alter appreciably the general results. The actual distribution is as follows: White males 252; white females 241; negro males 66; negro females 60; other races, males 15, females 11; unidentified as to race or sex 59.

#### MEAN SITTING HEIGHT AND WEIGHT.

The mean sitting height and weight for the end of each week of menstrual age, from the eighth week to term, are given in the accompanying table 1. These figures are obtained from the curves shown in charts 1, 2, and 4. In the table the weekly increment in height and weight is given. It is of interest to note that the weekly increment in height is greatest from the thirteenth to the seventeenth week, reaching a maximum of 15 mm. at the sixteenth week. Throughout the remainder of the fetal period the increase is surprisingly constant, varying between 9 and 11 mm. The relation of the increment in height to the actual height of the specimen, how-

ever, shows a steadily decreasing percentage. Thus the increase in height is 22 per cent during the tenth week, 18 per cent during the twelfth week, and continues to diminish until, between the thirty-eighth and fortieth weeks, it is less than 3 per cent.

The actual increment in weight, in contrast to the increment in height, is a constantly increasing one. The rate of increase is uniform except for an acceleration between the twenty-eighth and the thirty-second weeks, when it makes maximum jumps of 20 grams, and another acceleration from the thirty-eighth to the fortieth week. The percentage increment in weight is a little over twice that of the percentage increment in height and, like the latter, steadily decreases as the fetus

TABLE 1.—*Menstrual age with mean sitting height and weight.*

Based on 701 specimens of the Carnegie Collection, distributed as follows: white males 252; white females 241; negro males 66; negro females 60; other races, males 15, females 11; unidentified as to race or sex, 59. These data correspond to the curves shown in charts 1, 2, and 4.

Menstrual age.	Sitting height at end of week.		Increment in height.		Formalin weight. <sup>1</sup>		Increment in weight.		Menstrual age.	Sitting height at end of week.		Increment in height.		Formalin weight. <sup>1</sup>		Increment in weight.	
	weeks.	mm.	mm.	p. ct.	grams.	grams.	p. ct.	weeks.		mm.	mm.	p. ct.	grams.	grams.	p. ct.		
8	23				1.1			25	218	10	4.6	723	93	13			
9	31	8	26	2.7	1.6	59.3	26	228	10	4.4	823	100	12.2				
10	40	9	22.5	4.6	1.9	41.3	27	238	10	4.2	930	107	11.5				
11	50	10	20	7.9	3.3	41.8	28	247	9	3.6	1,045	115	11				
12	61	11	18	14.2	6.3	44.4	29	256	9	3.5	1,174	129	11				
13	74	13	17.6	26	11.8	45.4	30	265	9	3.4	1,323	149	11.3				
14	87	13	15	45	19	42.2	31	274	9	3.3	1,492	169	11.3				
15	101	14	14	72	27	37.5	32	283	9	3.1	1,680	188	11.2				
16	116	15	13	108	36	33.3	33	293	10	3.4	1,876	196	10.4				
17	130	14	10.8	150	42	28	34	302	9	3	2,074	198	9.5				
18	142	12	8.4	198	48	24.2	35	311	9	3	2,274	200	8.8				
19	153	11	7.2	253	55	21.7	36	321	10	3.1	2,478	204	8.2				
20	164	11	6.7	316	63	20	37	331	10	3	2,690	212	8				
21	175	11	6.3	385	69	18	38	341	10	3	2,914	224	7.7				
22	186	11	6	460	75	16.3	39	352	11	3.1	3,150	236	7.5				
23	197	11	5.6	542	82	15	40	362	10	2.8	3,405	255	7.5				
24	208	11	5.3	630	88	14											

<sup>1</sup> Many of the specimens between the twenty-eighth and fortieth weeks were embalmed, and in these cases the weight given is the fresh weight plus 5 per cent.

becomes larger. Thus, during the twelfth week the fetus gains 44 per cent in weight; during the fourteenth week 42 per cent; during the sixteenth week 33 per cent; and so on until, during the thirtieth week, the gain is less than 8 per cent.

## RELATION OF INCREMENT IN WEIGHT TO SITTING HEIGHT.

The increase in weight, in proportion to the increase in length, is readily determined from the mean curves on length-weight charts 1, 2, and 4. By reading the weight for each millimeter increase in length, one obtains the weight increase per millimeter, and in table 2 the average weight increments per millimeter of growth are given for fetuses from 40 mm. long to term. Specimens under 40 mm. long were not included, because the greater number were measured in their natural curved posture; their length, therefore, is not strictly comparable to that of older specimens whose bodies could be straightened out for the purpose of measurement. In the table the fetal length is divided into 10mm. intervals and the weight increment as given is the average increase per millimeter for the respective intervals.

From an examination of this table it is at once apparent that the weight increment per millimeter progressively increases throughout the fetal period. In fetuses under 60 mm. long the weight increase for each additional millimeter in length is less than 1 gram. In fetuses between 70 and 80 mm. long there is an average increase of 1 gram per millimeter. This becomes 2 grams per millimeter in fetuses between 90 and 100 mm. long, and 4 grams per millimeter in fetuses between 130 and 140 mm. long. In fetuses about 200 mm. long the weight increase is 10 grams per millimeter; 300 grams, 20 grams per millimeter; and at term it reaches 25 grams per millimeter.

It is of interest to note that, whereas there is a progressive increase in the actual weight increment throughout the whole fetal period, the contrary is true for the percentage weight increment which progressively decreases. For example, in fetuses 90 mm. long, weighing 50 grams, with each millimeter increase in length there is an increase of 2 grams in weight, *i. e.*, 4 per cent; in fetuses 160 mm. long, weighing 298 grams, the weight increment is 6 grams per millimeter, *i. e.*, 2 per cent; in fetuses 300 mm. long the weight increment becomes less than 1 per cent.

TABLE 2.—*Weight increment per millimeter for fetuses of various sizes.*  
The increment given is the average for the respective 10-millimeter intervals.

CR length	Weight increase.		CR length	Weight increase.		CR length	Weight increase.		CR length	Weight increase.	
mm.	gm. per mm.	p. ct.	mm.	gm. per mm.	p. ct.	mm.	gm. per mm.	p. ct.	mm.	gm. per mm.	p. ct.
			100	2.5	3.5	200	8.8	1.5	300	19.9	0.9
			110	3.0	3.3	210	10.3	1.5	310	20.7	0.9
			120	3.0	2.5	220	10.3	1.3	320	21.5	0.8
			130	4.0	2.6	230	10.8	1.2	330	23.3	0.8
40	0.3	6.6	140	5.0	2.6	240	12.0	1.2	340	23.5	0.8
50	0.5	6.4	150	5.5	2.3	250	14.8	1.3	350	23.5	0.7
60	0.9	6.7	160	6.0	2.0	260	17.2	1.3	360	25.0	0.7
70	1.0	4.6	170	6.0	1.6	270	19.8	1.4			
80	1.5	4.4	180	6.6	1.5	280	21.3	1.3			
90	2.0	4.0	190	7.8	1.5	290	21.5	1.1			

#### RELATIVE VARIATION IN SITTING HEIGHT AND WEIGHT.

It has been generally known that the length of the fetus exhibits less variation than its weight and in this respect is regarded as a more accurate criterion of age. From the data contained in our tables, and also from charts 1, 2, and 4, the normal variation in length (always referring to sitting height) relative to weight can be fairly accurately determined. Although it is true that the percentage variation in weight is greater than that of sitting height, yet the weight increment for each week is so much greater than that of length that age determination based on weight has an accuracy nearly as great as that based on length. The combination of the two increases proportionately the accuracy of age determination, and for this reason charts 1, 2, and 4 should prove of practical value.

At the fourteenth week the fetus has a mean sitting height of 88 mm. and a mean weight of 44 grams. If the far outlying ones are omitted, it will be found that specimens of this age measure between 85 and 92 mm. in length, a range of 7 mm., thus showing a variation of 8 per cent in length. At the same time, fetuses 88 mm. long vary in weight from 38 to 52 grams, *i. e.*, 14 grams or a variation of 31



per cent in weight. Since the increment in sitting height for the fourteenth week is 16 per cent, the existing variation of 8 per cent in length yields an accuracy of about half a week. In the same manner the increment in weight for the fourteenth week is 42 per cent. The weight variation at this time being 31 per cent, the resulting accuracy of age determination from weight would be three quarters of a week.

At the seventeenth week the mean length of the fetus is 130 mm. and the mean weight 150 mm. The normal range of length for this week extends from 125 to 135 mm., *i. e.*, 10 mm., thus showing a variation of 7.6 per cent. Since the length increment for a week at this time is about 10.7 per cent, an accuracy of about 5 days is yielded. The variation in weight for fetuses 130 mm. long is from 135 to 170 grams, a variation of 35 grams, or 23 per cent. The weight increment for a week at this time is 28 per cent, which for purposes of age determination yields an accuracy of 6 days as compared with three-fourths of a week at the fourteenth week.

At the twentieth week the mean length of the fetus is 164 mm. and the mean weight 316 grams. The normal range of length for this week extends from 155 to 172 mm., *i. e.*, 17 mm., a variation of 10.3 per cent; whereas, under the conditions of our examination, fetuses 164 mm. long have a normal range in weight from 275 to 367 grams, *i. e.*, 92 grams or a weight variation of 29 per cent. Since the increment of length for the twentieth week is 7 per cent and the increment in weight 20 per cent, the accuracy for age determination at this time is equivalent to  $1\frac{1}{2}$  weeks for both length and weight.

At the twenty-fifth week the fetus has a mean length of 218 mm. and a mean weight of 723 grams. Specimens of this week range in length from 207 to 229 mm., *i. e.*, a variation of 22 mm., or 10 per cent. On the other hand, fetuses 218 mm. long weigh from 615 to 845 grams, a variation of 230 grams, or 31 per cent. The increment of length for the twenty-fifth week being 4.6 per cent and the increment of weight being 12 per cent, we have an accuracy for age determination of 2 weeks, as based on length, and  $2\frac{1}{2}$  weeks as based on weight.

The fetus of the thirtieth week has a mean length of 265 mm. and a mean weight of 1,323 grams. Our fetuses at this time range in sitting height from 252 to 277 mm., *i. e.*, a variation of 25 mm. or 9.4 per cent. For a sitting height of 265 mm. they range in weight from 1,150 to 1,550 grams, *i. e.*, a variation of 400 grams or 30 per cent. The increase in sitting height for the thirtieth week is 3.4 per cent and the increment in weight is 11 per cent. This gives an accuracy for age determination of  $2\frac{3}{4}$  weeks as based on sitting height and 3 weeks as based on weight.

At the thirty-fifth week the fetus has a mean sitting height of 311 mm. and a mean weight of 2,274 grams. The normal range in sitting height at this time is from 295 to 327 mm., *i. e.*, a variation of 32 mm. or 10 per cent. The range in weight is from 1,970 to 2,650 grams, *i. e.*, a variation of 680 grams or 29 per cent. The increment in sitting height for the thirty-fifth week is 2.8 per cent and the increment in weight is 9 per cent. Therefore, where the age of a fetus of this size is estimated from sitting height alone, it can be done with an accuracy of  $3\frac{1}{2}$  weeks, and when done from weight alone it can be done with an accuracy of  $3\frac{1}{4}$  weeks.

In general it may be said that the normal variation in sitting height for any age over 40 mm. is from 8 to 10 per cent, and that the normal variation in weight

for a given sitting height is about 30 per cent. But since the weekly weight increment is about three times greater in its percentage than the sitting-height increment, the difference in accuracy in their use for the determination of age is slight. Their accuracy is greater in the earlier weeks and becomes progressively less toward the later weeks, varying from about 4 days at the fourteenth week to over 3 weeks at the thirty-fifth week. The joint use of the two determinations, however, correspondingly increases the accuracy of the age estimation.

For convenience of reference, these data have been tabulated in table 3. It is to be remembered that these figures are based on only 704 specimens and additional material may modify them somewhat; but it is probable that they are adequate to establish the essential character of these relations.

TABLE 3—Relative variation of sitting height and weight, showing extent of possible error in estimating age on either sitting height or weight.

	Mean.	Normal minimum.	Normal maximum.	Range of variation.	Range percentage.	Increment for week.	Possible error.
14th week:					<i>p. ct.</i>	<i>p. ct.</i>	
Sitting height . . . . .	87 mm.	85 mm.	92 mm.	7 mm.	8	15	4 days.
Weight . . . . .	45 gm.	38 gm.	52 gm.	14 gm.	31	42	5 days.
17th week:							
Sitting height . . . . .	130 mm.	125 mm.	135 mm.	10 mm.	7.6	10.7	5 days.
Weight . . . . .	150 gm.	135 gm.	170 gm.	35 gm.	23	28	6 days.
20th week:							
Sitting height . . . . .	164 mm.	155 mm.	172 mm.	17 mm.	10.3	7	1½ weeks.
Weight . . . . .	316 gm.	275 gm.	367 gm.	92 gm.	29	20	1½ weeks.
25th week:							
Sitting height . . . . .	218 mm.	207 mm.	229 mm.	22 mm.	10	4.6	2 weeks.
Weight . . . . .	723 gm.	615 gm.	845 gm.	230 gm.	31	12	2½ weeks.
30th week:							
Sitting height . . . . .	265 mm.	252 mm.	277 mm.	25 mm.	9.4	3.4	2½ weeks.
Weight . . . . .	1,323 gm.	1,150 gm.	1,550 gm.	400 gm.	30	11	3 weeks.
35th week:							
Sitting height . . . . .	311 mm.	295 mm.	327 mm.	32 mm.	10	2.8	3½ weeks.
Weight . . . . .	2,274 gm.	1,970 gm.	2,650 gm.	680 gm.	29	9	3½ weeks.

#### FOOT LENGTH.

For purposes of determining age, neither the foot length nor the head size, when used alone, has as much value as do weight and sitting height. The head size shows considerable variation, due in part to the mechanical molding which occurs in the great majority of specimens and in part to the varying effect of formalin on the soft tissues of the scalp, the distention of which affects the size reading considerably more than the corresponding increase in the sitting height. The foot length, as compared with the sitting height, possesses the disadvantage of being smaller and having a smaller weekly increment. Nevertheless, these two measurements serve as additional controls, and in cases of dismembered specimens they often constitute the only reliable criteria for the determination of the age. From an uninjured foot one can determine fairly closely the normal sitting height, weight, and menstrual age of the specimen by means of the respective correlation curves.

Accurate measurement of the foot can not be made earlier than in embryos about 24 mm. long. Briefly stated, the mean foot length at different intervals is as follows: at 8½ weeks, about 4 mm.; end of the eleventh week, about 7 mm.; end of the fourteenth week, 14 mm.; end of the sixteenth week, about 20 mm.; end of the twenty-second week, about 40 mm.; end of the thirtieth week, about

60 mm.; and at term it averages 82.5 mm. If the foot length is plotted as a curve at weekly intervals from the eighth week to term it will be found that the growth is relatively slow at first and does not reach its maximum weekly increment until about the fourteenth week, after which there is a weekly increase of about 3 mm., continuing with slight variation to term. The growth is a little more rapid from the fourteenth week (CR 87 mm.) to the twenty-sixth week (CR 228 mm.) and a little less rapid from then until term.

TABLE 4.—Foot length and its proportion to sitting height.

End of week.	Mean sitting height.	Mean foot length.	Minimum foot length.	Maximum foot length.	Percentage mean foot length: sitting height.	End of week.	Mean sitting height.	Mean foot length.	Minimum foot length.	Maximum foot length.	Percentage mean foot length: sitting height.
	<i>mm.</i>	<i>mm.</i>	<i>mm.</i>	<i>mm.</i>	<i>p. ct.</i>		<i>mm.</i>	<i>mm.</i>	<i>mm.</i>	<i>mm.</i>	<i>p. ct.</i>
8½	27	4.2	3.8	4.6	15.6	25	218	47.7	44.5	51.0	22.0
9	31	4.6	4.2	5.0	15.0	26	228	50.2	47.0	53.5	22.0
10	40	5.5	5.0	6.0	13.8	27	238	52.7	49.0	56.5	22.0
11	50	6.9	6.0	7.8	13.8	28	247	55.2	51.5	59.0	22.3
12	61	9.1	7.5	10.8	15.0	29	256	57.0	53.0	61.0	22.3
13	74	11.4	9.8	13.0	15.4	30	265	59.2	55.5	63.0	22.3
14	87	14.0	12.5	15.5	16.0	31	274	61.2	57.5	65.0	22.3
15	101	16.8	15.2	18.5	16.6	32	283	63.0	59.0	67.0	22.3
16	116	19.9	18.2	21.6	17.0	33	293	65.0	61.0	69.0	22.2
17	130	23.0	21.0	25.0	17.7	34	302	68.2	64.0	72.5	22.6
18	142	26.8	24.8	28.8	18.9	35	311	70.5	66.0	75.0	22.6
19	153	30.7	28.5	33.0	20.0	36	321	73.5	69.0	78.0	23.0
20	164	33.3	31.0	35.7	20.0	37	331	76.5	72.0	81.0	23.0
21	175	35.2	32.5	38.0	20.0	38	341	78.5	74.0	83.0	23.0
22	186	39.5	36.0	43.0	21.0	39	352	81.0	76.0	86.0	23.0
23	197	42.2	39.0	45.5	21.4	40	362	82.5	77.5	87.5	23.0
24	208	45.2	42.0	48.5	21.8						

The foot length of our individual specimens has been entered in the form of dots on charts 1, 3, and 5, showing the length in millimeters correlated to both sitting height and weight. The pathway occupied by the dots, aside from a few outlying ones, is smooth and distinct. When the upper and lower margins of this pathway are outlined it gives the maximum and minimum foot lengths at the different intervals. These readings are entered in the accompanying table 4. The average of the maximum and minimum lengths is entered as the mean foot length. There is also entered in the same table the percentage of the sitting height formed by the mean foot length for the end of each week. Examination of this table shows that there is a gradual increase in the length of the foot relative to the length of the embryo. This does not begin, however, until the fetus is about 70 mm. long. From 30 mm. to 60 mm. the foot grows less rapidly than the body as a whole. Beyond 70 mm. there is a slight gradual increase in the length of the foot in proportion to sitting height, so that during the last month the foot length is 23 per cent of the sitting height, having increased from about 15 per cent, which existed in fetuses 70 mm. long. This increase in the percentage of the foot length to sitting height is not so much due to an acceleration in the growth of the foot as to a retardation in the increase in sitting height that characterizes the latter part of fetal growth.

## HEAD MODULUS.

As an index of head size a modulus was selected, consisting of the mean of the greatest horizontal circumference of the head and the biauricular transverse arc (*i. e.*, the distance from one external auditory meatus over the vertex of the head to

the other external auditory meatus). The sum of these, divided by 2, is taken as a *head modulus* and expressed in millimeters. These measurements were selected because they can be systematically and accurately made for specimens from 50 mm. long to term, and because they tend to correct each other when the head is molded, as is frequently the case. If I were going to make these measurements again I should add the biauricular diameter to the transverse arc, thus obtaining a transverse circumference of the head. The average between this and the greatest horizontal circumference would approximate the average circumference of the head. Dr. Schultz, of this laboratory, in his anthropological study of the fetal period, is utilizing the horizontal, transverse, and sagittal circumferences, the latter two being composed respectively of the transverse arc and biauricular diameter, and the sagittal arc and nasion-inion diameter. By dividing his results by 3 he obtains a still more accurate mean head circumference. It is probable, however, that the head modulus as used may be relied upon as giving an approximate index of the normal head size and the essential proportions of the latter to body length.

The head-modulus data for the individual specimens were entered as dots on charts 3 and 5, showing their correlation to the mean sitting height and weight. The dots do not form as compact a cluster as those for sitting height in the corresponding charts 2 and 4; there is, however, a consistent pathway through which a smooth curve could be drawn, showing the mean head modulus. The readings taken from this curve are entered in table 5. Up to the thirty-second week the plotted field could be definitely outlined and its upper and lower limits for the successive weeks were entered in the same table, the few widely outlying entries being omitted. Beyond the thirty-second week there were enough data to complete a mean curve up to term, but not enough to warrant a delimitation of the range of variation. In table 5 were also entered the weekly increments in the mean head modulus and the proportion of the head modulus to the sitting height, expressed in percentages.

TABLE 5.—*Head modulus, representing head size in millimeters, based on the mean between greatest horizontal circumference and the biauricular transverse arc.*

End of week.	Mean.	Mini- mum.	Maxi- mum.	Incre- ment.	Percentage head modulus: sitting height.	End of week.	Mean.	Mini- mum.	Maxi- mum.	Incre- ment.	Percentage head modulus: sitting height.
	<i>mm.</i>	<i>mm.</i>	<i>mm.</i>	<i>mm.</i>	<i>p. ct.</i>		<i>mm.</i>	<i>mm.</i>	<i>mm.</i>	<i>mm.</i>	<i>p. ct.</i>
11	48	45.5	50	.....	96	26	207	196	216	9	90.7
12	59	56.2	62	11	96.7	27	215	204	225	8	90.3
13	71.2	68	74.2	12.2	96.2	28	223.5	212	234	8.5	90.4
14	84	80	87.6	12.8	96.5	29	230	219	242	6.5	89.8
15	97	92	101.8	13	96	30	237	225	249	7	89.4
16	110	104.6	114.8	13	94.8	31	243.5	232	257	6.5	88.8
17	121.5	115	127	11.5	93.4	32	251	238	265	7.5	88.6
18	132	125.5	137.6	10.5	93	33	258.5	.....	.....	7.5	88.2
19	142.5	135.5	148	10.5	93	34	265	.....	.....	6.5	87.7
20	151.8	145.5	157.6	9.3	92.5	35	271	.....	.....	6	87.1
21	160	152	165.5	8.2	91.4	36	277	.....	.....	6	86.2
22	170	161.5	179	10	91.4	37	282	.....	.....	5	85.1
23	180	170	190	10	91.3	38	287	.....	.....	5	84.1
24	189	180	199	9	90.8	39	293.5	.....	.....	6.5	83.3
25	198	188	207	9	90.8	40	301	.....	.....	7.5	83.1

From an examination of the table, it will be seen that the actual increment in head size undergoes a slight gradual decline from the twelfth to the fortieth week, decreasing from 13 mm. to 5 mm. Expressed in terms of percentage the decrease is greater, being from 20 per cent to about 2 per cent. As in the case with sitting height, the greatest increments are before the eighteenth week. The decrease in the percentage increment is a little greater in the head modulus than in the sitting height, and its mean curve, as seen in charts 3 and 5, gradually recedes from the mean curve of the latter. On this account the head modulus, though at first nearly equivalent to the sitting height (96 per cent), toward the end of pregnancy is less than 84 per cent. In a few outlying instances the head modulus equals or exceeds the sitting height. These are cases showing unusual distention of the soft tissues of the scalp. Under the usual conditions, if the head modulus is greater than the sitting height it should be regarded as abnormal. In this way we may be able to detect early cases of hydrocephalus. On the other hand, if the head modulus is too small we have an indication of microcephalus.

## BIBLIOGRAPHY.

- MALL, F. P., 1910. Determination of the age of human embryos and fetuses. *Manual of Human Embryology* (Keibel and Mall), vol. 1, p. 180-201.
- , 1918. On the age of human embryos. *Amer. Jour. Anat.*, vol. 23, pp. 397-422.
- MEYER, A. W., 1914. Curves of prenatal growth and autocalysis. *Arch. f. Entwicklungsmechanik der Organismen*, vol. 40, pp. 497-525.
- , 1915. Fields, graphs, and other data on fetal growth. *Contributions to Embryology*, vol. 2, pp. 55-68, Carnegie Inst. Wash. Pub. 222.
- RUGGS, T. F., 1901. A comparative study of white and negro pelves, with a consideration of the size of the child and its relation to presentation and character of labor in the two races. *Johns Hopkins Hosp. Reports*, vol. 12, pp. 421-451.
- SCHULTZ, A. H., 1919. Changes in fetuses due to formalin preservation. *Amer. Jour. Phys. Anthropol.*, vol. 2, pp. 35-41.
- , 1920. An apparatus for measuring the newborn. *Johns Hopkins Hosp. Bull.*, vol. 31.
- ZANGEMEISTER, W., 1911. Die Altersbestimmung des Foetus nach graphischer Methode. *Zeitschr. f. Geb. u. Gyn.*, vol. 69, pp. 127-142.

Tables 6 and 7 constitute a list of normal embryos of the Carnegie Collection on which the correlation curves of sitting height, weight and menstrual age are based. The material is arranged according to weight, *i. e.*, its formalin weight after being in a 10 per cent solution about two weeks. Some of the specimens of over 400 grams in weight were injected with the formalin solution through the umbilical vessels, as noted under "Remarks"; in such cases the weight given is the fresh weight plus 5 per cent, this being more nearly comparable to the weight of specimens simply immersed in the solution. The sitting height of specimens 50 mm. long and over was measured with the body held as straight as possible. Specimens smaller than this were usually measured in their natural curved posture. In the overlapping field both measurements are given, as seen in table 6. By head modulus is to be understood the mean between the greatest horizontal circumference of the head and the biauricular transverse arc. The estimated menstrual ages of the specimens are based on the curve in chart 6, with the exception of the first 8 specimens in table 6, the ages of which are based on the estimates of Mall (1910).

TABLE 6.—Data on embryos weighing less than 10 grams.

Weight.	Sitting height (CR).		Head modulus.	Foot length.	Specimen No.	Menstrual age		Grade.	Remarks.
	Straight.	Flexed				Stated.	Est'd.		
<i>grams.</i>	<i>mm.</i>	<i>mm.</i>				<i>days.</i>	<i>days.</i>		
.012	.....	5.5	.....	.....	1380	44	(35)	1	The age data of the first eight specimens are taken from estimates of Mall, 1910.
.110	.....	9.5	.....	.....	2113	.....	(40)	1	
.215	.....	14.5	.....	.....	1267 <i>a</i>	.....	(46)	1	
.442	.....	14.5	.....	.....	1232	.....	(46)	3	
.578	.....	19	.....	.....	1063	49	(49)	2	
.607	.....	18	.....	.....	1390	54	(49)	1	
.745	.....	19	.....	.....	1332	58	(50)	1	
.755	.....	18	.....	.....	1927	.....	(49)	2	
1.001	.....	23	.....	.....	1266	.....	56	1	Possibly grade 2.
1.055	.....	25	.....	.....	1459	74	57	2	
1.25	.....	19.3	.....	.....	2114	56	56	1	Hysterectomy.
1.5	.....	25.9	.....	.....	895	.....	58	1	Quite straight.
2	.....	29.6	30.5	4.2	879 <i>c</i>	.....	61	2	
2.095	.....	24.6	.....	.....	1474 <i>e</i>	.....	61	2	Sharply flexed.
2.2	.....	28	.....	4.2	1779	.....	61	3	Blunt.
2.5	.....	25	.....	4.5	1267	72	63	3	Sharply flexed.
2.5	.....	32.8	.....	4.5	949	65	65	3	Scalp torn off, underweight.
2.6	.....	31	.....	.....	1495 <i>a</i>	.....	63	2	Quite swollen.
2.8	.....	27.5	.....	.....	2561	75	62	1	
3.2	.....	31.1	36.5	4.6	950	35	65	1	Moderately swollen.
4	34.4	32	.....	5.2	1022 <i>d</i>	.....	68	3	Macerated.
4.12	43	.....	.....	6	1675	87	70	3	Tissue lost, underweight.
4.39	40	36.2	.....	5.8	1684	62	69	2	Some skin torn off.
4.5	42.5	38	41.5	6	1012	82	71	2	
4.56	.....	36	.....	5.5	1591	.....	70	1	Distended with formalin.
4.6	.....	33.2	.....	5.3	1358 <i>b</i>	.....	67	1	
4.6	.....	37	.....	5.5	2330	72	70	2	Twin.
4.64	.....	38.5	.....	5.3	1840 <i>a</i>	71	71	2	
4.66	.....	31.6	.....	6.1	1031	42	60	1	Distended with formalin.
4.8	40.5	.....	.....	5.2	1826	44	71	1	
5.14	.....	37	.....	5.5	1980	.....	2	1	Distended with formalin.
5.2	.....	35.5	.....	5.8	1915	70	71	1	
5.46	45.5	.....	.....	6	1929	63	73	2	Thin.
6.1	45	.....	.....	6.7	1534	.....	74	3	Macerated; ectopic.
6.15	47	11.5	.....	6.7	1613	.....	74	2	Distended with formalin.
6.238	.....	43.3	.....	5.7	1611 <i>a</i>	.....	75	1	
6.26	.....	39	.....	.....	1597 <i>b</i>	74	74	1	Flexed into a ball.
6.4	.....	33.2	.....	5.9	1488 <i>b</i>	67	74	2	Hysterectomy.
6.5	.....	40	.....	6	2075	70	74	1	
6.5	.....	43	.....	6	1686	.....	75	1	Nearly straight.
6.5	48.5	.....	.....	6.4	1437	86	75	1	Body flexed, Filipino.
6.5	50	.....	.....	7.5	2027	.....	76	2	
6.5	50.7	.....	45.5	7.2	1434 <i>f</i>	.....	76	3	High vertex, Filipino.
7.4	51	49.3	45.5	7.2	1388	149	76	3	Stretched straight, Filipino.
7.5	49.6	.....	47	7.4	928 <i>d</i>	118	76	1	Distended with formalin.
8	50	.....	.....	7	1660	.....	77	2	
8.275	52.6	.....	.....	6.8	1793	.....	78	3	Skin torn from head.
8.8	52	.....	.....	8	495 <i>b</i>	.....	78	2	Body flexed, Filipino.
9	48	.....	49.5	7.2	2203 v	.....	78	2	
9	52	.....	50.5	7.5	2203 III	.....	79	2	High vertex, Filipino.
9	53.5	.....	50	8	2204 IV	.....	79	2	Stretched straight, Filipino.
9.19	50	.....	51.5	7	2331	.....	78	1	Distended with formalin.
9.24	54	.....	.....	8	1625 <i>b</i>	47	79	2	
9.26	49	43.5	51	6.5	2357	46	77	1	Injured.
9.5	50	.....	.....	6.5	2170	74	78	1	Hysterectomy.
9.5	54.5	.....	.....	7.8	1514	58	79	3	Torn and macerated.
9.5	56	.....	.....	7.3	1242 <i>b</i>	.....	79	3	Thin, part of scalp missing.
9.8	50	.....	.....	7.5	1965	.....	78	1	Much distended with formalin.
9.8	55	.....	50	8.5	1101	.....	79	2	Body curved, skin torn from scalp.

TABLE 7.—Data on embryos weighing 10 grams or more.

Weight.	Sitting height (CR).	Head modulus.	Foot length.	Race.	Sex.	Specimen No.	Menstrual age.		Grade.	Remarks.
							Stated.	Est'd.		
<i>grams.</i>	<i>mm.</i>		<i>mm.</i>				<i>days.</i>	<i>days.</i>		
10	50		6.5		F	2144		79	1	Distended with formalin.
10	54		7		F	1537		80	1	Distended.
10.5	54	53	7	W	M	2389	77	80	3	Hydatiform degeneration of villi.
10.5	57		8		M	1556		81	2	
10.5	58		9	W	M	1882a	70	81	3	Menstrual age approximated.
10.6	57.5		9		F	1659		81	3	Tubal pregnancy.
11.5	52.2	57.5	7.7	N	M	965		81	1	Distended with formalin, hysterectomy.
11.5	53		7		M	2066		81	1	Distended.
11.5	56		8	W	M	2121		82	3	Shrivelled.
11.8	62	56	9.3		F	929a <sup>1</sup>		82	3	Twin.
12	58	51.5	8	W	M	1234	82	82	3	Some skin torn from head.
12	60.2	53	8.8	W	M	1083		82	3	Head appears small.
12	62.8	55.5	8.4		F	843		82	2	Body very straight.
12	64.5	54.5	8.8		F	935		83	3	Thin specimen.
12.4	56		8.3	W	F	2504	91	83	3	Head damaged.
12.8	58.2	55.5	8	W	M	847	80	83	2	Distended.
13	60		8.5	W	M	2080	91	83	3	
13	61	54.5	9.3		M	884		83	3	
13	62.8	58.5	9	W	M	1135	90	84	3	
13	63		9		F	1495c		84	3	
13.4	61		9	W	F	1689	123	84	2	
13.5	52		8	W	M	2095		80	1	Distended with formalin.
13.5	56.5		8.5	W	F	2079	63	83	1	Distended, menstrual age approximated.
13.7	64.5	58	9	Korean	M	1462		84	3	
14	58.2	58.7	8.9	W	M	853	82	83	1	Distended.
14	62		8		F	2076c		84	3	Quite macerated.
14	62		8.5	W	M	1916	86	84	3	
14	64		10	W	F	2339		84	3	Tissues damaged.
14.2	66	59	9	W	F	1210	88	86	3	Slender and very straight.
14.3	59	59	8.7	W	M	1364	91	84	2	Scalp torn.
14.5	62.5		9	W	F	2191	95	84	3	Much macerated.
14.6	63		9	W	F	1661b	84	84	2	Twin.
14.8	61	58.7	8		F	2511		84	2	
15	61		8.5	W	F	2102	80	84	2	
15	62	60.5	9.5	W	F	1471		84	2	
15	64	58.5	9.9		M	929a <sup>2</sup>		85	3	Twin, head shrunken.
15.2	62.5	63	9	N	F	1359		85	2	Tubal specimen.
15.5	62.5	61.5	9	W	F	2187		85	1	
16	62		9	W	M	1553	97	85	2	
16.3	61	60.5	9.5	W	M	2523	80	85	1	Distended with formalin.
16.5	60.5	59	9	W	F	2031		85	2	Distended.
16.8	69		11.8	W	F	1747	94	88	3	Quite slender, apparently stretched.
17.2	63	66	10.1		F	1413		86	1	Tubal, body curved.
17.5	63	63	9.4	W	F	907	85	86	1	
17.5	65		9.5	W	F	2141	91	86	3	
18	65.5	62	10	W	F	1282b		87	2	Head thin.
18	66		9	W	M	1918	51	87	2	
18	66	63	9.6		M	1603		87	2	
18	67.3	61.5	9.6	W	F	928a		87	2	Skin desquamated.
18.3	66.6	66	10	W	F	844	98	87	1	
18.8	68		10.5	W	F	1661a	84	88	2	Twin, head partially collapsed.
19	67.8	63.5	10		F	1598a		88	2	
19	69	63	10.5		F	2183		88	2	
19.5	69	67.5	9.2	W	M	1183	90	85	1	Long stretched neck.
19.5	66	66	9.2	W	M	1445	93	88	2	Distended.
19.5	66		9.8	W	F	1669	88	88	3	Distended.
20.5	69.5		9.5	W	F	2109	84	88	3	
20.5	71.5		11		F	2152		89	3	Macerated, apparently underweight.
20.8	69.5	68.5	10.2		F	1542		89	2	Tubal pregnancy.
21	65	65.2	10		F	2328		88	1	Moderately distended.
21	66.5		10.2	W	M	2148		88	3	
21	68.2	68.5	10	W	F	1157	80	88	1	

TABLE 7.—Data on embryos weighing 10 grams or more—continued.

Weight.	Sitting height (CR).	Head modulus.	Foot length.	Race.	Sex.	Specimen No.	Menstrual age.		Grade.	Remarks.
							Stated.	Est'd.		
<i>grams.</i>	<i>mm.</i>		<i>mm.</i>				<i>days.</i>	<i>days.</i>		
21	69	.....	11	W	F	1329	85	89	3	
23	66	.....	10	W	F	1350	84	89	3	Injured.
23	69	65.5	10.5	.....	M	1295 <sup>g</sup>	62	89	2	
23	70.5	71	10	W	F	1478	.....	89	2	
23.5	66.2	71.5	10	W	M	1724	72	89	1	Distended with formalin.
23.5	73	.....	11	W	M	1889	112	90	3	Macerated; menstrual age approximated.
23.5	76	65.5	10.8	.....	M	1134 <sup>a</sup>	.....	90	2	Some brain lost, due to injury.
23.6	71.5	71.5	10.7	.....	F	1431	.....	90	2	
24	79.6	69	11.2	N	F	925	124	93	3	Thin.
24.5	72.5	.....	11.5	.....	F	1873	.....	90	3	Macerated.
24.5	69.5	.....	10	.....	F	2118	.....	88	1	Somewhat distended with formalin.
25	73	68	11.2	W	F	2289	93	90	2	
25.5	74	70	11	W	F	1242 <sup>a</sup>	99	91	2	
26.5	69.5	.....	10.5	.....	M	2105	.....	88	1	Distended.
27	69	70.5	12.5	Fil.	M	2203 <sup>ii</sup>	.....	90	2	Filipino.
27.5	78	74.5	11.5	W	M	906	78	91	1	
28	73.5	.....	11	.....	M	2199 <sup>b</sup>	.....	91	2	
28.5	76	68	12	N	M	1828	49	92	3	
29.3	82.5	.....	11.6	W	M	1721	71	93	2	Head molded toward vertex.
29.5	77	73	12.5	N	F	2252	91	91	1	Hysterectomy.
29.5	78.5	.....	11.9	W	M	1552	.....	93	1	
30	74	74	11.3	.....	F	1605	.....	91	1	Distended with formalin.
30	79	76	12.5	.....	F	1260 <sup>b</sup>	.....	93	2	
30.5	78	74.5	12.5	W	F	1733	95	93	2	
31	71	75.5	11	W	F	1358 <sup>a</sup>	.....	89	1	Distended with formalin.
31.8	83	73	13.3	.....	M	1406	89	94	2	Macerated.
32	76	.....	11.5	N	M	2122	119	93	1	
32	84.5	.....	14	W	M	2013	.....	93	3	Slightly macerated.
32	83	73	13.7	N	F	1504	.....	94	1	Thin.
33	82	81	12	W	F	1817	95	94	1	
33.5	78	79	11	W	F	1345	101	94	2	
33.5	78.5	79	11.1	N	F	1455	101	94	1	Hysterectomy.
34	78	76.5	12.3	.....	F	1291	.....	94	2	
34.5	84	.....	12.7	.....	F	1474 <sup>b</sup>	.....	95	3	
34.7	79	75.5	12	.....	M	2512	.....	94	1	
35	83.5	.....	11.2	.....	F	1216	.....	95	2	
36	79	.....	12	W	M	2307	.....	94	2	
36	81	84	13	N	M	2323	.....	95	1	Tubal pregnancy.
36.8	82	79	.....	W	M	1098	.....	95	2	
37	76.5	81.5	12.5	W	F	1968	68	93	1	Distended with formalin.
37	82.6	79.5	14	.....	M	1922 <sup>c</sup>	.....	95	2	
37.3	85.9	82	13.5	.....	M	1134 <sup>e</sup>	.....	96	2	
37.5	82	80.1	12.4	.....	M	1483	.....	95	2	
37.5	85.5	.....	13	.....	M	2182	.....	96	2	
38.5	87	81.5	14.4	.....	F	1358 <sup>i</sup>	.....	97	2	Rather thin.
39	81	.....	13.5	W	F	1886	.....	96	3	Body curved.
39	87	81.7	14.5	W	M	2001	108	97	2	
39.5	89.5	.....	13	W	M	1506 <sup>a</sup>	97	96	3	Body very straight.
40.5	81	.....	13	W	F	2093	.....	96	1	Distended with formalin.
40.5	86	83.2	13.5	W	F	1907	91	97	2	
41	84.5	82	14	.....	F	983 <sup>b</sup>	.....	96	2	
41.3	90	.....	14.3	W	M	1304 <sup>e</sup>	101	98	2	Macerated.
41.5	83	81	14	W	M	981	108	96	2	
41.5	83.2	84.5	12.8	W	M	1705 <sup>a</sup>	.....	97	2	
42	84.5	81.5	13	W	F	1740	.....	97	2	
42	86	78.5	13	Fil.	F	2202 <sup>vi</sup>	.....	97	2	Filipino.
43	84	83.2	11.2	.....	M	832	.....	97	1	
43	85.5	78	13.9	.....	M	879 <sup>b</sup>	.....	97	3	
43.2	92	86.5	13.5	W	M	2493	.....	98	3	
45	90	.....	15.5	W	F	2058	61	98	3	
45.4	87.5	85	12.7	.....	M	1430	.....	98	2	
45.5	87.3	86.9	14.4	.....	F	1449	.....	98	2	
46	89	83.5	14.6	W	F	1132	.....	98	3	
46.5	84.7	84	14	N	F	924	.....	98	2	



TABLE 7.—Data on embryos weighing 10 grams or more—continued.

Weight.	Sitting height (C.R.).	Head modulus.	Foot length.	Race.	Sex.	Specimen No.	Menstrual age.		Grade.	Remarks.
							Stated.	Est'd.		
<i>grams.</i>	<i>mm.</i>		<i>mm.</i>				<i>days.</i>	<i>days.</i>		
47.3	90.3	81.5	13.5	W	M	1439	96	99	2	Menstrual age approximated.
47.5	85	89.2	13.5	W	F	1562	97	98	1	Distended, tubal pregnancy.
47.5	86	86	14	W	F	2062 <sub>a</sub>	117	98	2	
48	90	84.2	11	W	F	2381	105	99	2	
48.5	91	89	11	W	M	1294	57	99	2	
48.5	91.5	.....	15	.....	M	1905	105	100	3	Apparently emaciated.
50	87	86.5	15	.....	M	1845 <sub>a</sub>	98	58	2	Distended.
51	91.5	86.5	14.7	N	M	1641	97	100	2	
51.3	89.2	90	.....	W	F	1104	103	100	1	
51.5	90	85	11.5	W	M	1317	108	100	2	
52	100	.....	15.7	W	F	1353	98	100	3	Head molded toward apex.
53.5	94	88	14	W	M	1985	49	101	2	Menstrual age approximated.
54	95	.....	13.7	.....	F	1252	.....	101	2	
56.5	99	90.7	16.5	W	F	1993	67	102	3	Moderately emaciated.
57.5	92	94.5	15	.....	M	1215	.....	101	1	Moderately distended.
57.5	97	.....	16	N	F	1768	91	102	2	
58	90.6	87.5	15.1	Fil.	M	900 <sub>i</sub>	.....	101	2	Filipino.
58	93	.....	15	N	M	1690	98	101	2	Brain hernia. Hysterectomy.
58.5	95.5	.....	16.5	W	F	1997	.....	102	2	
59	93	92	15.5	.....	F	2354	.....	102	1	Tubal pregnancy.
59.2	97	90	.....	W	F	1010	98	102	2	
59.5	103	.....	16.2	.....	M	1532	.....	104	3	Very slender specimen.
59.7	90	88.2	11	W	F	2436	58	100	1	Distended with formalin. Hysterectomy.
59.7	96	92	15	W	M	2484	.....	102	3	
60	99.3	95	15.5	W	M	980	.....	102	2	Head molded toward vertex.
61	91	.....	16	.....	M	1268	.....	102	1	
62.5	97	97.5	15.3	W	F	1590	.....	103	2	
63.2	95	91	17.2	N	F	2433	.....	102	2	
63.5	104	.....	16.5	W	M	1870	115	103	3	Stretched very straight.
64	100	92	15	W	M	2215	142	103	2	
64.5	93.5	94.5	16	W	F	1831	105	102	2	Somewhat distended. Menstrual age approximated.
65	95	96	15.5	W	F	1310	105	103	1	History of single coition.
65.5	103	.....	17	W	M	1699	.....	104	3	
66	100	92.5	16	W	F	1839	98	104	2	
67.3	100	.....	16	W	F	1476	87	104	2	
68	100	95	17	.....	M	1253	108	104	2	Menstrual age approximated.
68.2	101.2	94	16.4	.....	F	1134 <sub>b</sub>	.....	104	2	
68.5	100.5	.....	16.5	.....	M	1846	.....	104	2	
69	98.5	96.2	17	W	M	1538 <sub>a</sub>	96	104	1	Twin.
69	106.5	.....	17	W	F	1982	107	105	3	Slender and very straight body.
70	97	.....	18	Fil.	F	2202 <sub>iv</sub>	.....	104	2	Filipino.
70.6	102	.....	16	W	M	2438	.....	105	2	
72.8	97.8	89.5	16.8	W	M	1078	114	104	1	
74	100	102	18.9	N	F	1595	.....	105	2	
76	104	95.7	17	W	F	1888 <sub>a</sub>	101	106	3	Twin.
76.4	100	101	16	W	F	2548	.....	105	1	Distended with formalin.
76.5	98.5	104.5	17.2	W	M	1538 <sub>b</sub>	96	105	1	Twin.
77	97.5	98.7	17.5	W	M	2199 <sub>c</sub>	.....	104	1	Distended.
77	100.5	93.7	18	N	F	1908	109	105	1	Distended.
77.5	104.8	93.5	19.4	W	M	827	.....	106	3	
78	108	100.5	19.6	W	F	913	159	107	3	
78.5	103.5	.....	18.5	W	F	1459	.....	106	2	
79	105.4	97	16.4	N	F	1152	.....	106	2	
79.2	103	93	18	W	F	2454	100	106	2	
81.5	100	104.5	15.5	W	F	2271	.....	105	1	Distended with formalin.
81.5	108	100.5	20	W	M	1769	114	107	2	Menstrual age approximated.
81.5	111	92	19	W	F	1906	95	108	3	Mechanically damaged.
82	105	.....	15.5	W	F	2130	114	107	1	
82	106.7	.....	19	W	F	1186	112	107	2	
82.5	110	.....	18.5	W	M	1884	112	107	2	
83.5	106.4	105	18	W	F	1663	117	107	2	
83.5	106.7	97.5	.....	W	M	1079	94	107	2	
84.1	97	104.5	17	W	F	2588	105	107	1	Much distended.

TABLE 7. *Data on embryos weighing 10 grams or more—continued.*

Weight.	Sitting height (C.R.).	Head modulus.	Foot length.	Race.	Sex.	Specimen No.	Menstrual age.		Grade.	Remarks.
							Stated.	Est'd.		
<i>grams.</i>	<i>mm.</i>		<i>mm.</i>				<i>days.</i>	<i>days.</i>		
84.8	100.4	101.5	18.5	W	M	1358c	.....	107	1	
85	111	100	17	W	F	2351	.....	108	3	Thin specimen.
85.5	103	106.5	18.4	W	M	1295e	94	107	2	Slightly distended.
86.2	110	103	18.5	.....	F	1426	.....	108	2	
86.3	101	105.5	17	W	F	2467	.....	107	1	Distended.
87	104	101.5	18	W	F	1835	102	108	2	
89	107	102	17.5	N	M	2372	.....	108	3	
89	109	100.5	18.3	W	M	1812	109	109	2	
91	100	107.5	17.7	W	F	1858	81	107	1	Distended.
93	118.5	.....	18.5	.....	M	2247	.....	110	3	Thin.
93.5	115	104	20.5	N	F	2189	133	110	2	
94	112.5	102.5	21	W	F	1512	.....	109	2	
94.5	103.5	105.5	20	W	F	2003	.....	108	1	Distended.
95.5	108	106.5	18	N	M	1270	.....	109	1	
95.5	111	109	19.7	W	M	1673	.....	110	2	
96	113.3	102.5	19.2	W	M	1725	103	110	2	
96.3	112	108.5	20	.....	M	1211a	.....	110	3	Twin.
96.5	115	.....	18.5	W	F	2160	109	110	2	
100	112	104	20	W	F	1271	.....	110	2	
100	113	102	20.5	.....	M	1211b	.....	110	3	Twin.
100	115.5	.....	21.5	W	F	2083	.....	111	2	
100	118	108	20	W	F	2245	112	111	2	Thin specimen.
100.5	113.5	111	20	W	M	2185	103	111	1	
101.4	118	106.5	20.5	W	F	2482	112	111	3	
102	115	103.5	20.3	W	M	928d	.....	111	2	
103.5	115	110	20	.....	F	1311	.....	111	2	
104	112	108.5	19.5	W	M	1182a	105	111	1	Distended.
104	121.5	.....	20.5	.....	M	1956b	.....	111	3	Head much elongated.
106.5	114	113.5	18.5	.....	M	1888b	101	111	3	Twin.
107	116	106.5	20	W	F	1348	115	112	2	
107	117	112	21	W	M	1973	119	112	3	
109	127	.....	21.4	W	M	1499	121	114	3	Very thin.
110	118	111.5	21	W	F	1622	.....	113	3	
110.8	119.7	109.5	20.4	N	F	1130	.....	113	2	
111	119.5	106	20.5	.....	F	1626	.....	113	2	
111.5	118	.....	19	W	M	1295m	110	113	3	
112.5	113	111	20.3	N	F	1600	.....	112	1	Distended.
113.5	113	113	21.5	W	M	2271	.....	112	1	Distended. Hysterectomy.
113.5	120	.....	21.5	W	F	1995	.....	113	2	
116.5	121	106.5	22.3	.....	F	1491a	.....	114	3	Macerated.
117.5	119.5	101.5	19.8	W	M	812	105	114	1	
120	116	114	21	W	F	1832	.....	111	1	
120.5	118.3	110.5	21.8	.....	F	969b	.....	114	2	
121	116	103.5	22	N	F	1384	108	114	2	
121	124	110.5	21	.....	M	1200a	.....	115	2	Apparently macerated.
121.7	111	113.5	20	N	M	2472b	.....	113	1	Twin.
122	118	112	21.5	.....	M	2321	.....	114	1	
126	126	115	21.4	W	M	1559	91	115	2	
127	125.5	.....	20.5	W	M	2134	119	115	2	
127	126.5	115.5	21.5	W	F	1904	.....	115	3	
128	125	.....	24.5	N	F	2212	114	115	2	
128.5	129.5	.....	23	W	F	2119	121	116	3	
129.3	120	115.5	22	N	M	2472a	.....	115	1	Twin.
129.5	.....	115.3	21.5	W	F	1448	112	.....	2	Specimen curled up.
130	119.5	120.5	21	.....	M	1424	.....	115	1	
131	121	.....	22	W	F	2048	115	115	2	Menstrual age approximated.
131	125	117.5	21.8	W	M	1142	.....	116	1	
134	125	.....	22	W	M	1285a	110	116	2	
135.8	124.4	119	21	N	M	1529	151	116	1	
136.5	116.4	115	21.4	W	M	831	112	115	1	Distended with formalin.
138	117.4	113.5	22	W	M	1050	109	115	1	Distended with formalin. Hysterectomy.
139	136.2	115.5	23	W	M	1722	.....	119	3	
139.5	123.5	.....	23	N	F	2072	133	117	2	
139.5	131	113.5	20.7	W	M	1378	.....	118	2	
140	132.4	.....	24	W	F	1743	123	118	2	Menstrual age approximated.

TABLE 7.—Data on embryos weighing 10 grams or more —continued.

Weight.	Sitting height (CR).	Head modulus.	Foot length.	Race.	Sex.	Specimen No.	Menstrual age.		Grade.	Remarks.
							Stated.	Est'd.		
<i>grams.</i>	<i>mm.</i>		<i>mm.</i>				<i>days.</i>	<i>days.</i>		
141.5	125		22		F	1282a	121	117	2	
141.5	127.6	115.5		N	F	1066		118	1	
143	134.5	117	22	W	M	1833	122	118	2	Stretched very straight.
143.5	127	118	22.5	W	M	1293	133	118	2	
146	131		23	W	F	2407	123	119	1	Embalm'd.
149	129	115.5	24.6	W	F	1387	99	119	2	
151	131		23.5	W	M	1365	138	119	2	
151	132.3	115	23.8	W	M	928b	114	119	2	
152.5	128	124.5	25	W	F	1951	126	119	2	
155.5	134	119.2	23.4		F	823		120	3	
156	125.5	119.5	23.5	W	M	1966		119	1	Distended.
156.5	135	124.5	24.5	W	M	1222	113	120	2	
159	132	123.5	24.4	W	M	1302	120	120	2	
159	137		24.5		M	1849		121	2	
160	142		25	W	M	2059	97	121	3	
160.5	131	128	23.8		F	1575		120	1	
161	126	124.5	23		F	1358g		120	1	Distended.
161	135	125	25		M	1855	115	120	2	
161.5	128		24	N	M	1879	126	120	2	
161.5	128.8	116.5	22.2	W	M	952a	116	120	2	Twin.
162	128	124	24.9	W	F	928c	93	120	1	
162	136.5	125	24.9		M	1491		121	2	
163	135	122.5	24		M	2246		121	2	
164	128.4	125.5	24	N	F	1609b		121	1	Twin.
166	131.2	126	25.8	N	M	1609a		121	1	Twin.
166	139.5	119	25.5	W	M	2188		122	3	
169.5	129	127.5	22.5	W	M	1957b		121	1	Distended.
172	131	126.5	25.5	W	F	1983		122	2	
174.5	141.7	124.2	24.5	W	M	1426	126	123	3	
175	142	127.5	24	W	F	1284	119	123	2	CR long because of haematoma.
177	132	124	23	N	M	1524	117	122	1	
177	141		25	Ind.	F	1978	147	123	3	Menstrual age approximated.
177.5	135.6	130.5	26.8		F	1782		123	1	
177.8	138.4	119	26.3	Fil.	F	990b	152	123	1	Stretched very straight. Filipino.
178.5	133.5	125.7	25	N	F	2086	129	123	1	
179	141	125	25.5	N	M	2172		124	2	
180.5	136.4	124			F	1054		123	2	
180.5	142	122	24		M	2495		124	2	
182.5	136	124.5	24	N	F	2628	119	123	1	
183.8	134		25.5	N	F	2569		124	2	Embalm'd.
188	137	124.5	26.4	W	F	1391		124	2	
189	139	135	25.5		M	1957a		124	2	
190	141	126	24.5	W	M	1502		125	3	Body curved.
190	142	125.5	27	Fil.	M	2201A		125	2	Filipino.
190	153	133	27	N	F	1489b	124	126	3	
190.5	125		25.5	W	F	2004		123	1	Tissues quite swollen and congested.
197.1	146	123.5	28.5	N	M	2418a		126	2	Twin.
200.5	143	133.5	28	W	F	1903		126	2	
202	144	131.5	30	W	F	1816	128	127	2	
205	146		27.5		M	1923		127	3	
213	130		27	W	F	2190		127	2	Body curved, tissues swollen.
213	142	141	26.5		M	1510		128	2	
213.8	140	136	26.2		M	1433		128	1	
215	141	140	26	W	F	2424		128	1	
216	150.7	138	29.4	W	F	951	126	129	2	Menstrual age approximated.
216.3	152		28	W	M	2502		129	1	Embalm'd.
218	141	134.5	24.6	W	F	1257	123	128	1	
218.5		139.5	26.6	W	F	1338	126	129	2	Body markedly curved.
220.5	142		30		F	2076a		129	2	
221	158		29	W	M	2527		130	1	Embalm'd.
222	146.5	136.2	27	W	M	1991		129	2	
223	142	136	28.5		F	2154		129	1	
225	146	142	25.5	W	M	2267	123	129	1	

TABLE 7. — *Data on embryos weighing 10 grams or more* — continued.

Weight.	Sitting height (C.R.).	Head modulus.	Foot length.	Race.	Sex.	Specimen No.	Menstrual age.		Grade.	Remarks.
							Stated	Est'd.		
<i>grams.</i>	<i>mm.</i>		<i>mm.</i>				<i>days.</i>	<i>days.</i>		
226.4	141	136.5	27.5	W	F	2458		129	1	
226.5	154	140.5	28.2	W	M	1708		131	2	
226.8	157		31.5	N	M	2390		132	1	Embalmed.
228	116	148	27	W	F	2067		130	1	
228	165		32.5	F	F	1928		132	3	
229			27.5	W	F	2282		131	2	
229	158.4	141.5	30.8	N	M	1168		131	2	Quite straight.
229.5	154	132.7	29	W	M	1825	92	131	1	Quite straight.
232.5	144	138	27	W	M	1240 <i>b</i>		130	2	
237.5	149	136	29	W	F	2248	126	131	1	
238	149		31	N	F	2064	127	131	1	
238.5	152.4		30.2	N	M	1788		131	2	
240	155.5		32.5		F	2076 <i>b</i>		132	3	
240.5			33		M	1370		132	3	
241	149	130.5	30.5	W	M	2540		131	2	
241	141	139.5	28.5		F	2374		130	1	
242.5	158	132.5		W	F	1179	93	132	2	
243	152	132.5	31	Fil.	M	2201 <i>v</i>		132	2	Filipino.
244	157.5		29.4	N	M	1159		132	2	
245	153	141.5	33	N	F	2284		132	1	
246	150	135.5	30.5	N	F	801	133	132	1	
247	143.5	138.5	28.5		M	1954 <i>a</i>		132	2	Body curved.
248.5	150	145.5	28.7		M	1702		132	1	
249.5	141		33	W	M	2194		132	3	
252.3	155.6	133.5		N	M	1103		133	2	
253	160	144.5	31	N	F	2343	140	134	2	
253.7	149	137	32	N	M	241 <i>sb</i>		133	2	Twin.
254.5	160		32	W	M	2018	93	134	3	
257.5	157	144.5	29.7		M	1551		134	2	
260	152	132.5	30.5		M	2560		133	2	
260	153.5		30.5	W	M	2061	133	133	3	
262.5	160		31	W	F	2577		134	1	Embalmed.
263.5	148.6	140		W	F	1068	152	134	2	
264	151	145	29.8	W	M	1521 <i>a</i>	98	133	1	
267.5	155	143	32		F	1191	116	135	2	
269	149	147	28		M	1200 <i>d</i>		134	2	
269.5	149.5	150.5	30	W	F	2055		134	1	
270	158		31.5		M	2159		135	3	
272	157.7	140		W	F	1166	147	135	1	
272	160		30.5	W	F	2180	142	135	2	
274	158		27.5	W	M	2110	133	135	2	
275	158	143.5	31.5	N	F	2164	154	135	1	
278	162.5			W	M	2149	175	136	2	
278	163.5	133.5	32.6	W	F	1149	151	136	2	
279.5	172		32	W	F	2078	86	137	3	
280	144	153	31.5	Fil.	F	2200 <i>xi</i>		135	2	Filipino.
280	157.5		34.5	Ind.	F	1979		136	3	Indian halfbreed.
281.3	148	151	36	N	F	2414	189	135	1	
286	171		32	W	F	2232		138	3	
287	161.8	150.5	31	W	M	1765		137	3	
291	156.5		32.2		F	1691 <i>b</i>		137	2	
292	161.9	149.5	31	W	M	1049	130	138	1	
292	165		32	W	M	2054	189	138	3	
294	159		31	W	M	2737		137	1	Embalmed.
295	157.5	150.5	34		M	2043		137	1	
297	160.5	154	30		M	1451		138	2	
297.5	162	146	33.5	W	F	1427	126	138	2	
298	150	153.5	32	N	M	2168		137	1	
299.3	173		31.5	W	F	2551	147	138	2	Embalmed. Length based on fixed measurement.
300	155	155.5	31.5		M	2264 <i>e</i>		138	2	
301.5	160	141.5	34.6		M	1593		138	2	
303	159	152	30	W	M	2087	130	138	1	
306.6	169		32	W	M	2531	137	138	1	Embalmed.
307.5	163	147	33.3		F	1657		139	2	
308.5	165.3	147	33.4		M	1714		139	2	

TABLE 7.—Data on embryos weighing 10 grams or more—continued

Weight.	Sitting height (C.R.).	Head modulus.	Foot length.	Race.	Sex.	Specimen No.	Menstrual age.		Grade.	Remarks.	
							Stated.	Est'd.			
<i>grams.</i>	<i>mm.</i>		<i>mm.</i>				<i>days.</i>	<i>days.</i>			
309.5	148		33	W	M	2012	...	139	2	Body curved.	
310	154.5	145.5	35.5	N	F	2082	...	139	2		
310	155	147	31	N	F	2591	...	139	1		
311	153.5	157	30.5	N	M	2240	147	139	2	Subcutaneous oedema.	
312	154	151	32	W	M	918	...	139	1	Body not quite straight.	
312	159.5	...	35		F	2145	...	139	3		
314	159	156.5	28	W	M	1295 <sup>7</sup>	119	140	1		
315	176	154	33		F	2264 <sup>b</sup>	...	141	3		
317	170	...	35	W	M	2017	81	141	2		
319	167.5	...	33.5		F	2133	124	141	2		
320	159	160	35	Fil.	M	2200 II	...	140	2	Filipino.	
322.2	163	155	34	W	F	2477	...	141	2		
336	166	142.5	35	W	M	1013	...	142	3		
337.5	160	153.5	34	W	M	1326	...	142	2		
339	159	159	33		M	1899 <sup>a</sup>	...	142	2		
341	169	155.5	31.5		F	2295	...	143	1		
343	177	150.5	34.5		F	1450	...	143	2		
346	165	155.5	34	Fil.	M	2201 III	...	143	1	Filipino.	
346	168	157.5	33.5	W	F	1385	152	143	1		
346.6	158	154	31	W	F	2437	...	142	1		
350	169	155.5	33	Fil.	F	2201 IV	...	144	1	Filipino.	
351	172	155.5	34	W	M	2299 <sup>b</sup>	...	144	2	Twin.	
351.5	165	161.5	34.5	N	M	1383	161	143	1		
352	170	151.5	37	Fil.	M	2200 V	...	144	2	Filipino.	
357	169	...	38	N	F	2543	...	143	1	Embalm'd.	
363	173.5	151.5	33.3	W	M	1185	145	145	2		
365	161	162.5	35	Fil.	M	2200 IV	...	144	1	Filipino.	
367	175	155.7	35	W	M	1939	164	146	2		
368	165	155.5	36	Fil.	F	2200 IX	...	145	2	Filipino.	
368	178	...	36	N	M	2491	...	145	3	Embalm'd.	
370.5	172.5	153	34.6	W	M	1480	122	145	2		
371	179	...	32.5	W	F	2129	...	146	2		
373.5	163.5	159	33	W	F	1912 <sup>a</sup>	136	145	1	Twin.	
377	170	150	37.5	N	F	2100	...	177	146	1	
378	178.5	...	40	N	F	2440 <sup>a</sup>	...	146	1	Embalm'd.	
381	153	155.5	35	Fil.	M	2200 VII	...	145	2	Filipino.	
381	179	...	40.5	N	F	2085	92	147	3		
381	173.5	156	35.2	W	M	1964	210	147	1		
385	177	...	37	W	F	2503	...	147	1	Embalm'd.	
387	177.5	...	35.5	W	M	2342 <sup>b</sup>	...	147	3	Twin.	
389	164	...	33		M	2319	...	147	2		
391.6	177	157.5	37	W	M	2505	...	148	1		
393	171	165.5	37.7		M	1316	...	147	2		
393	173.5	...			M	2030	...	147	1		
394	180	156	39	N	M	2586	...	148	1	Embalm'd.	
394.5	184	158.5	36	W	F	2303	...	148	1		
395.5	179	160		W	F	1059	123	148	2		
399	170	169	37	W	F	1876	191	148	2		
399	182	173	37	W	F	2496	...	148	1	Embalm'd.	
404	180	165.5	37	W	F	2398	...	148	2	Embalm'd.	
407	157.7	155.5		W	F	1072	...	145	1		
407	187	159	39	N	M	2302	...	149	1		
408.5	167	163.5	35	W	M	1912 <sup>b</sup>	136	148	1		
420	188	168.5	37	W	M	2507	152	151	1	Embalm'd.	
422	181	159	37.4		F	1195	...	150	2		
426	168.4	165.5	37.9	W	F	894	155	149	2		
428.5	172.5	168	38	W	F	1774 <sup>a</sup>	...	151	1	Twin. Caesarean section.	
430	185.3	161.5	38	W	F	961	151	151	1		
431	177.8	169.5	35		M	1171	...	151	1		
431	188	166	37.5	N	M	2520	...	152	1	Embalm'd.	
433.5	183	164	39	W	M	1469	152	152	1		
434	187	160	39	W	F	2342 <sup>a</sup>	...	152	1		
436	193	...	39		M	1995 <sup>a</sup>	...	153	3		
444	177	170	37.5	N	M	2211	141	152	2		
445	187	162	...	W	M	1067	147	153	2		
445	194	...	35	W	M	1309	240	153	3		

TABLE 7.—Data on embryos weighing 10 grams or more—continued.

Weight.	Sitting height (C.R.).	Head modulus.	Foot length.	Race.	Sex.	Specimen No.	Menstrual age.		Grade.	Remarks.
							Stated.	Est'd.		
<i>grams.</i>	<i>mm.</i>		<i>mm.</i>				<i>days.</i>	<i>days.</i>		
447	175 2	172	38 5	W	F	1774b	...	152	1	Twin. Caesarean section.
447 8	179	169 5	...	W	M	1096	177	153	2	
448	186	170	43	Fil.	F	2200 II	...	153	2	Filipino.
450	187	163	39	W	M	2299a	...	153	2	
451	190	168 5	38 5	W	F	2220	158	153	2	
452	191	175	38	W	F	2486	...	153	2	Embalmed.
453	177 5	168 5	35	W	M	1924	154	153	1	
453	182	170 5	41	Fil.	F	2201 II	...	153	2	Filipino.
455	188 5	...	38	N	M	2063	155	153	2	
459 5	177 8	168	37 1	...	F	1691a	...	153	1	
461	182	169 5	39	W	M	1412	156	154	1	
461	188	179	41	N	F	1143	164	154	2	
464	184	171 5	37	Fil.	F	2201 VIII	...	154	1	Filipino.
467	185	170 5	39	W	F	2480	...	155	2	
469 5	191 2	171 5	39	W	F	1742	147	155	2	
473	195	166	40	W	M	2306	178	156	2	
477 2	186	160 5	37 5	W	M	2498	...	156	2	
480	196	171	41	W	F	2453	...	156	2	Embalmed.
490	187	172 5	41	Fil.	M	2201 VII	...	156	1	Filipino.
496 7	191	168 5	40	W	M	2474	155	157	2	
500	190	176 5	42	W	F	1646	100	157	2	
500	198	...	41	N	M	2070	...	158	2	
503	191	...	41 5	W	M	2147	...	157	3	
516	183	165 5	38	W	F	2279	...	158	2	Short and fat.
516	201	173	42	W	M	2304	...	159	2	
517 2	191	173 5	44	W	M	2446	158	158	1	
520	189 5	177	...	W	M	1680	...	159	2	
527	198	180 5	42	N	M	2178	163	160	2	
534	189	178	39	W	F	1306	149	160	1	
534	201	166	48	N	M	2350	...	160	2	
538	192	181	43	W	F	2387	...	161	2	Embalmed.
542	180	181 5	41	Fil.	M	2201 I	...	160	1	Filipino.
545	201	...	42	W	M	2283	...	161	3	
545	211 5	175 5	44	...	F	1554	...	163	2	Emaciated.
549	195	182 5	41	...	F	1564	151	161	2	
552	192	180	43	Fil.	F	2200 VIII	...	161	1	Filipino.
554	196	188 5	42	W	F	2485	...	161	1	Embalmed.
556	201 5	190 5	40	N	F	2193	...	162	2	
564	184	187	42	W	M	2019	155	161	2	
565	198 4	181	42	W	F	1489c	...	163	2	
567	197	185 5	40	W	F	2490	...	163	1	Embalmed.
569	198 5	184 8	42	N	F	1913	81	163	2	
573	185	188	40	N	M	2287	...	162	2	
574 5	204 5	178	39 5	W	F	2263	163	164	2	
575	215	183 5	48	W	M	1619	...	164	2	
578	201	194 5	45	W	M	2738	...	164	2	Embalmed.
580	198	183	44	W	F	2606	...	163	1	
586	210	192	43	W	M	2402	...	164	2	Embalmed.
584 5	197	...	45	N	M	2060	162	164	3	
589	210	...	43 8	W	F	1177	...	165	3	
590 5	195	178	43 5	W	M	1654	187	165	2	
593	202	180	42	N	M	2441	...	165	2	Embalmed.
603	196	183 5	43	Fil.	F	2200 I	...	165	1	Filipino.
609 5	212 5	...	47	N	M	2088	...	166	1	
611	197	181	41 5	...	M	1823	...	166	1	
611	218	185 5	46 5	W	F	2320	...	166	2	
617	204	176 5	47	N	F	2277	...	167	1	
626	202	186	41	W	M	2195	...	167	2	
626	216	196	46	W	M	2249	...	168	2	
627	199 4	188 5	42	...	F	1498a	...	167	2	
633	210	...	45 5	...	M	2050	...	169	2	
636	195	...	45	W	M	1138	...	168	3	
637	208	...	48	W	F	2049	...	168	2	
642	214	192	46 2	...	F	1614	...	169	2	
655	209	197	46	N	F	2278	...	169	1	
656 5	204	185	49 3	...	F	1375	...	169	2	

TABLE 7. --Data on embryos weighing 10 grams or more --continued

Weight.	Sitting height (CR).	Head modulus.	Foot length.	Race.	Sex.	Specimen No.	Menstrual age.		Grade.	Remarks.
							Stated	Est'd.		
<i>grams.</i>	<i>mm.</i>		<i>mm.</i>				<i>days.</i>	<i>days.</i>		
657	226	186 5	48	N	F	2293		170	1	
664	205 3	192 5	44 5	W	F	1764		170	1	
666	210	194 5	49	N	F	1085		170	1	
680	221	186 5	49	W	F	2281		172	3	
683	219	194 5	46 5	N	F	2562	200	172	3	Embalmed.
684	195	196 5	45	W	F	1204		171	2	
686	202	186 5	40	W	F	2365		172	1	
704	198	194	45	W	M	2396		172	1	
710	220	202 5	49	N	F	1265	168	171	2	
710	221 6	203 7	46 2	W	M	1395		171	2	
712	208 5		49 5	W	F	2011		171	2	
714	205	184	43	N	M	2724		171	2	Embalmed.
720	219	201 5	47	W	M	2305		175	1	
724	217 5	196	49	W	F	1877	175	175	2	
734	198 5	198	46 5		F	1861		175	1	
735	209	197	48	W	F	2539		175	2	Embalmed.
735	209	185 5	47	W	M	2425		175	1	Embalmed.
740	213	196 5	47	W	M	2301	206	176	1	
741	211 5	193	49	N	M	2392	97	176	2	
744	217	202 5	46	W	F	2209		176	1	
751	235	219 5	47	W	M	2574		178	2	
758	211	202 5	47	W	M	2167		178	2	
759	231	191 5	50 5	W	F	1934	178	178	2	
761	228	199	50 5	N	F	1566		178	2	
767	220	203	45	W	M	2464		178	2	
772	233		49	N	F	2116		179	1	
773	225	203 5	52		F	2157		179	2	
785	226 5	201	48	W	M	2041	172	180	1	
790	216 5	199	52	W	F	2181	180	180	2	
795	212 4	203	48		F	1500		180	1	Hysterectomy. Body curved.
814	238	212 5	51	N	M	2397	182	182	1	Embalmed.
817	233	206	50	W	M	1452	161	182	3	
830	248	215	53	W	M	2243		183	2	
857	230	207	53	W	M	1172	154	184	2	
865	236	212 5	52 2		M	1651		185	2	Quite straight.
866	242	210	54	W	M	2332		185	1	
872	221		51	N	F	2186	183	185	3	
880	238	209	53 6		M	1650		186	2	
883	238 5	214 5	52	N	F	2266	185	186	2	
884	223		52	W	M	2015	183	185	2	
914	225	211	51	N	M	2427		187	1	Embalmed.
926	240	217 5	52	W	M	1792	196	189	2	
948	240	203	53	W	M	1131	115	190	2	
957	250	222 5	56	W	M	1503	168	191	2	
984	251	214	54	N	M	2553		192	2	Embalmed.
987	229	204 5	50	N	F	2519		191	1	Embalmed.
988	246	218 5	58	N	M	2333		192	3	
993	226		53	W	M	2223	187	192	3	
1007	239		50	W	M	2089		193	2	
1076	245		59	W	F	1212	210	197	2	
1081	236	252 5	57		M	1691		197	3	Body twisted.
1089	229	211 5	48	N	F	2449		196	3	Embalmed.
1105	262	243 5	59	W	F	2543		199	3	Embalmed.
1124	260	236	57 5		F	2755		200	1	Embalmed.
1168	257	233	62	W	F	2318		202	2	
1182	268	225 5	59	N	F	2292		203	1	
1187	250	246	60	N	M	2725		203	1	Embalmed.
1209	262	239 5	57	W	M	1396	205	204	2	
1233	259	228 5	55	W	F	2363		206	1	
1260	273	236	58	W	F	2552		208	1	Embalmed.
1276	268	232 5	58	W	M	2534		208	1	Embalmed.
1295	253	231	55	W	M	2375		207	2	
1374	272	236 5	62	N	M	2379		213	2	
1387	269	231	66	N	M	2337		213	1	
1390	255	240 5	57	Phi	M	2200	213	213	3	Filipino
1399	266 5			N	F	2104	235	213	3	

## WEIGHT, SIZE, AND AGE OF THE HUMAN EMBRYO.

TABLE 7.—Data on embryos weighing 10 grams or more—continued.

Weight.	Sitting height (CR).	Head modulus.	Foot length.	Race.	Sex.	Specimen No.	Menstrual age.		Grade.	Remarks.
							Stated.	Est'd.		
<i>grams.</i>	<i>mm.</i>		<i>mm.</i>				<i>days.</i>	<i>days.</i>		
1428	258				F	2014		214	3	
1501	274		62.5	W	M	2294		217	1	
1520	275		62	W	M	2509 <i>b</i>		218	1	
1596	300	246.5	65	W	M	2265		224	3	
1637	276				M	2029		222	1	Hysterectomy.
1643	266	234.5	58	W	F	2384		218	2	
1649	285	262	65	N	M	2592		223	2	Embalmcd.
1649	289	258.5	65	W	M	2525		224	1	Embalmcd.
1691	277	249.5	59	N	M	2747		224	2	Embalmcd.
1700	285	245.5	62	W	M	2509 <i>a</i>		225	2	
1764	281	248	65	N	M	2380		228	1	
1765	294	244	68.5	N	M	2300		229	3	
1775	300	246.5	59	W	M	2597		231	2	Embalmcd.
1794	296	258	64	N	M	2316		235	2	
1842	275	230.5	56	N	F	2373		226	4	
1900	281	254	61	W	F	2518		227	1	
1937	308	259.5	74	N	M	2479		234	2	Embalmcd.
1953	305		68	W	F	2051		234	1	
1962	317	273.5	67	W	F	2335	254	239	1	
1980	328		67	W	M	1397		239	3	
1995	296	283	67	N	M	2758		235	1	Embalmcd.
2000	317	266.5	70	W	M	2443		240	3	Embalmcd.
2006	294	256	68	N	F	2554		235	1	Embalmcd.
2016	305	267	69	W	M	2466		236	2	Embalmcd.
2053	314	289.5	75	N	F	2465		242	1	Embalmcd.
2094	315	264.5	68		M	1401		242	2	Ectopic.
2167	286	270	71		F	2161		242	2	Curve in back.
2216	316	275	70	N	M	2419		244	1	Embalmcd.
2258	315	274	66	W	F	2434		244	2	Embalmcd.
2262	307	269	71	W	M	2309		244	3	
2271	298	270.5	61.5	W	M	1922	229	242	1	
2346	307	271	70	W	F	2368		247	2	Embalmcd.
2410	330	275	74	N	M	2259		250	3	
2412	317	276.5	79.5	W	F	2238		250	3	
2499	355		76	W	M	1794		259	3	
2510	339	276	73	W	M	2317		254	1	
2520	323		73.5	W	F	2585		254	1	Embalmcd.
2578	337	262	74	W	F	2448		256	2	Embalmcd.
2584	328			W	F	2103		256	3	
2625	332	304	75	W	M	2677	252	257	1	Embalmcd.
2651	337	284.5	76	N	M	2428		258	1	Embalmcd.
2696	320	275	73	N	F	2364		257	2	
2762	309	287	78	N	M	2576		252	1	Embalmcd.
2773	350	275	79	N	M	2226	238	263	1	
2779	350		83	W	M	1723		263	2	
2783	328	283.5	74	N	M	2413		262	3	Embalmcd.
2793	344	280.5	86	N	F	2358		263	1	Embalmcd.
2795	349	279.5	77	W	F	2366		265	2	
2855	322	280	82	N	M	2312		263	2	
2870	349	283	77	W	F	2327		265	1	
3014	344	292.5	78	N	M	2353		268	1	
3045	350	296.5	76	W	M	2409		269	1	Embalmcd.
3120	380			W	F	1275		278	3	
3134	351	298	86	W	M	2442		273	2	Embalmcd.
3205	365	294	82	W	M	2346		275	1	
3218	354	295	77	N	F	2359		275	1	Embalmcd.
3255	347	295.5	84	W	F	2315		275	1	
3255	348	295.5	78	W	M	2524		275	1	Embalmcd.
3266	349	295	79	N	M	2537		276	1	Embalmcd.
3371	367	314.5	86	W	M	2558		279	2	Embalmcd.
3596	363	287.5	86	W	M	2566		280	1	Embalmcd.
3770	361	299	86	N	M	2423		280	1	Embalmcd.
3780	339	292	85	N	M	2405		280	1	Embalmcd.
4064	369	323	84	N	M	2500		294	1	Embalmcd. Cord attached
4298	376	280	78	W	F	2451		298	2	Unusually fat. Embalmcd.



CHART 1.

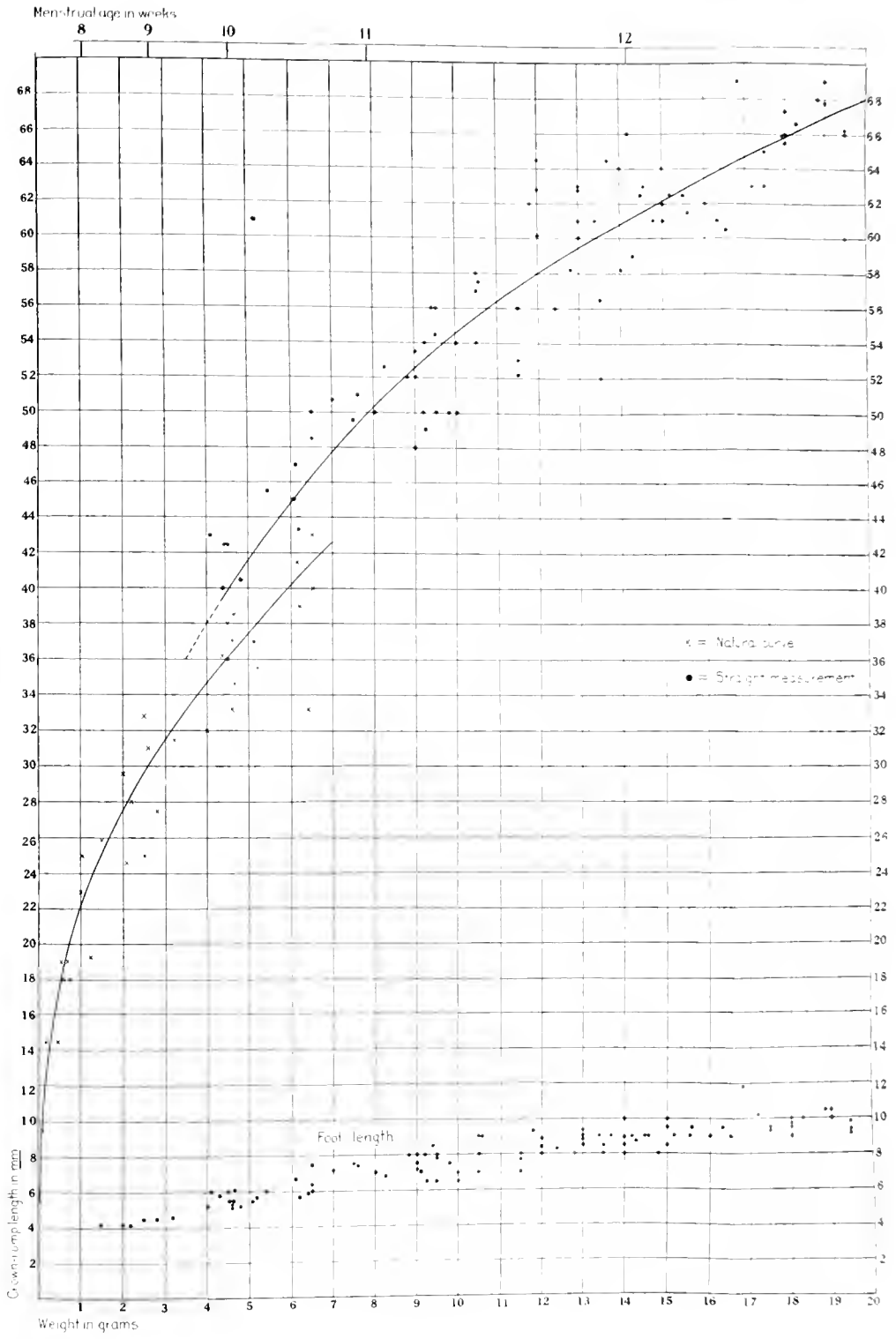
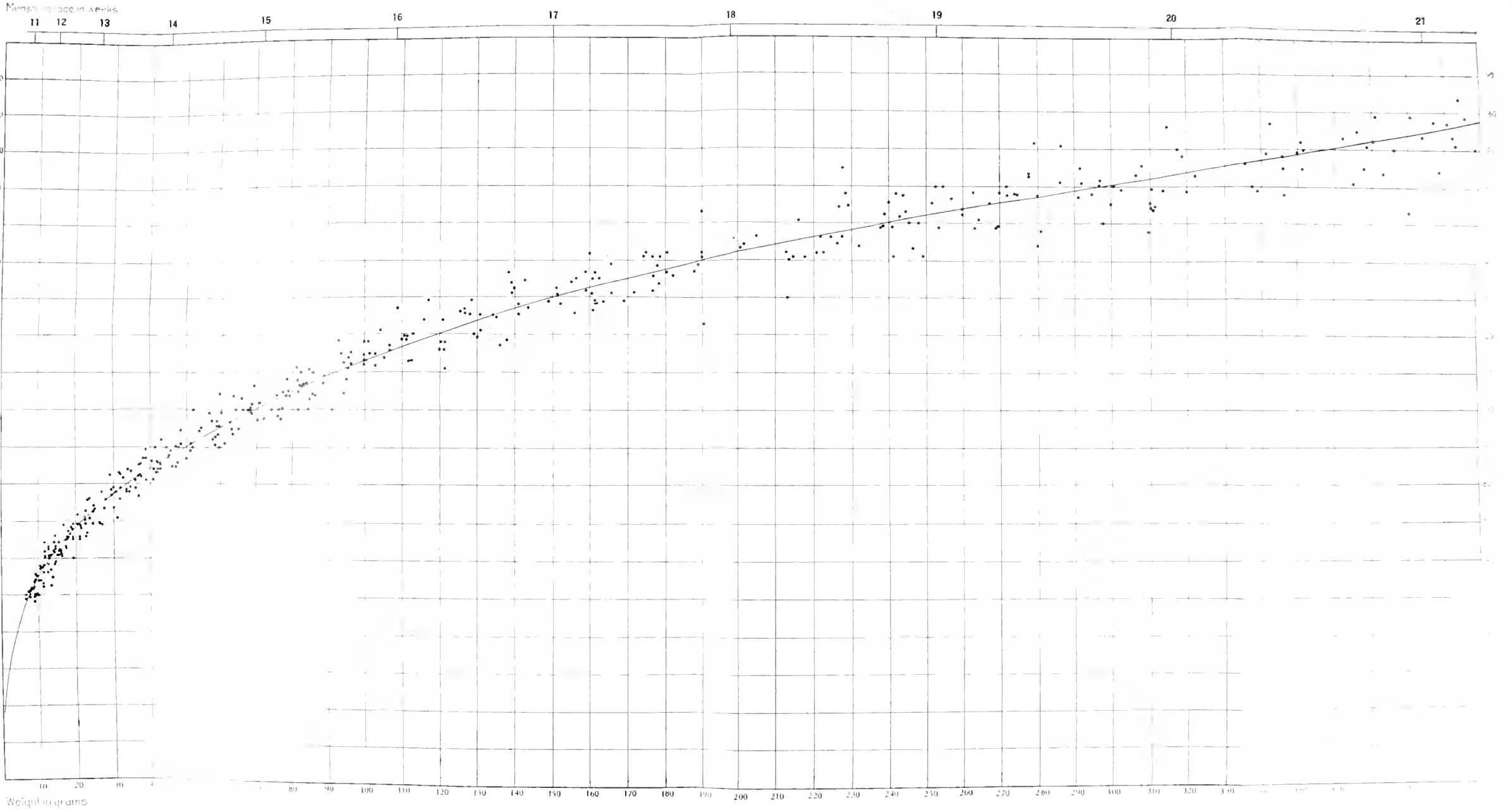


CHART 1.

Growth curve based on crown-rump length and weight of embryos weighing less than 20 grams. Each specimen measured with the body straightened out is entered as a dot; those measured in their natural curved posture are entered as crosses. The mean curves drawn through these two fields overlap, showing that if embryos of 36 to 42 mm. are straightened out it adds about 4 or 5 mm. to their length. Toward the bottom of the chart the foot length in millimeters is plotted according to weight of embryo. A scale showing menstrual age, as in the succeeding charts, is placed at the top of the chart. This scale is based on chart 6.



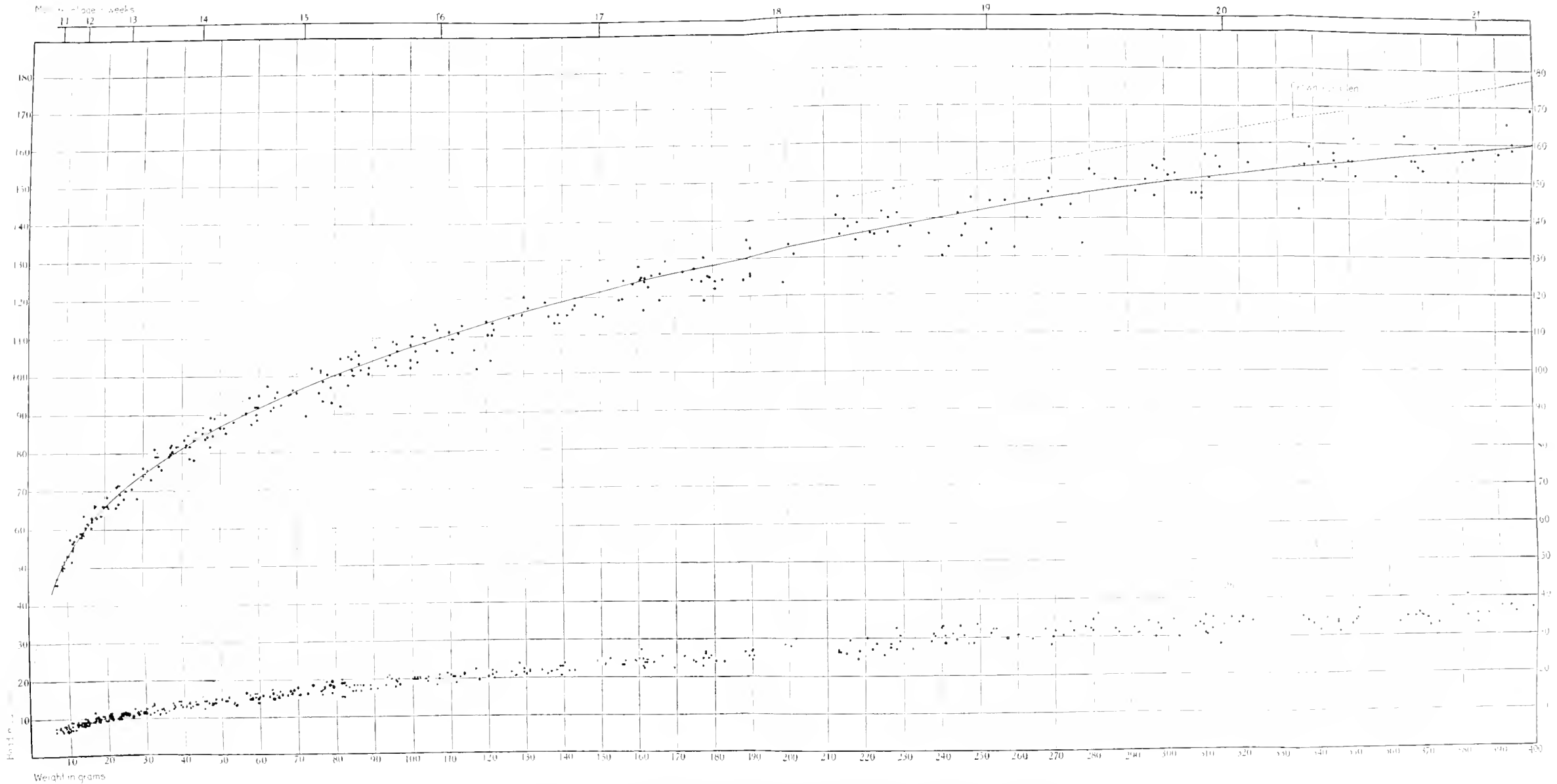
Chart 2.



Mean curve of growth for fetuses of the Carnegie Collection weighing less than 400 grams, based on sitting height and weight.



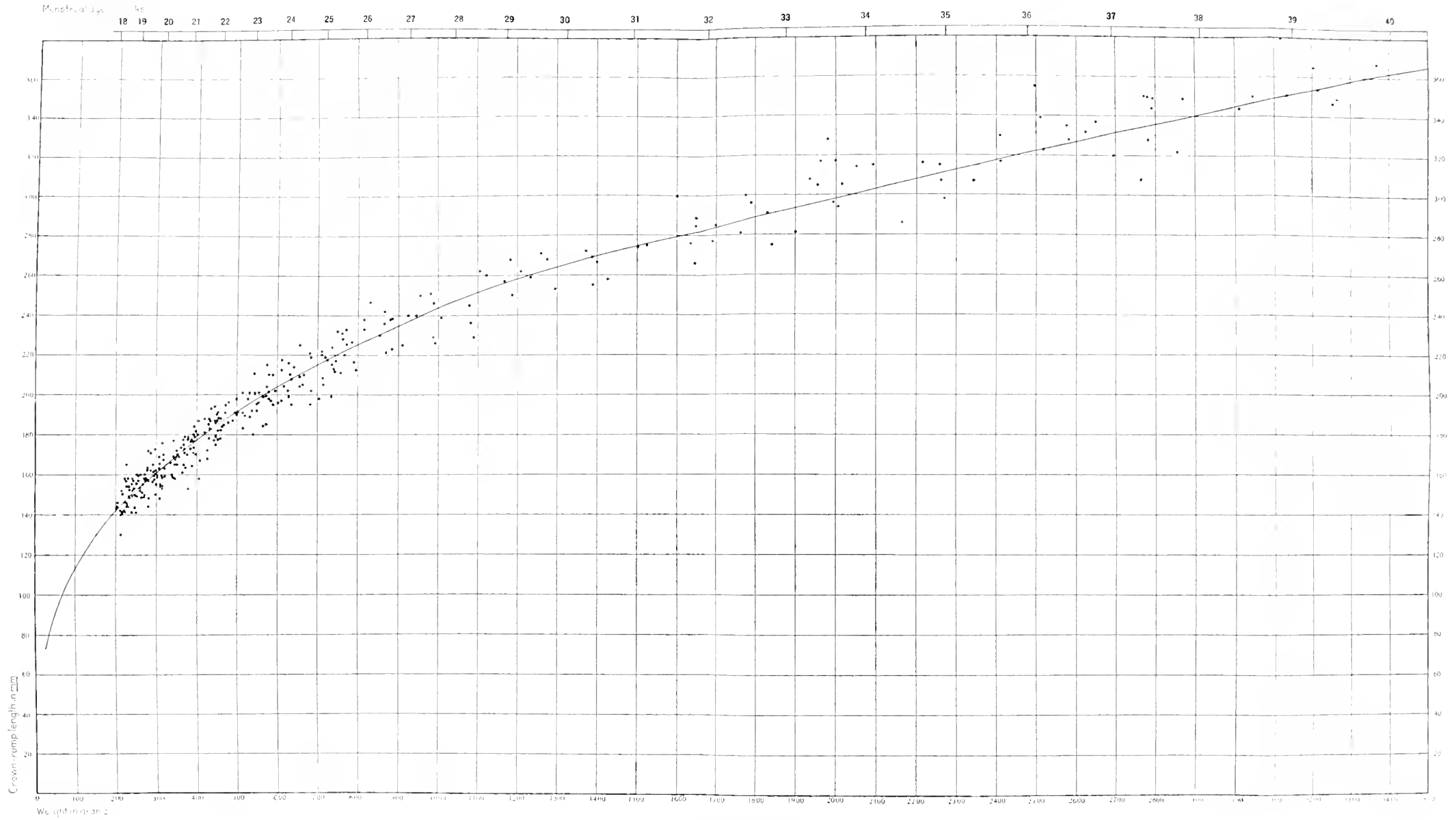
CHART 3.



Foot length and head modulus correlated to sitting height and weight for fetuses under 400 grams in weight. The heavy line represents the curve of the mean head modulus; the broken line is the mean sitting height or crown-rump length, taken from chart 2.



CHART I.

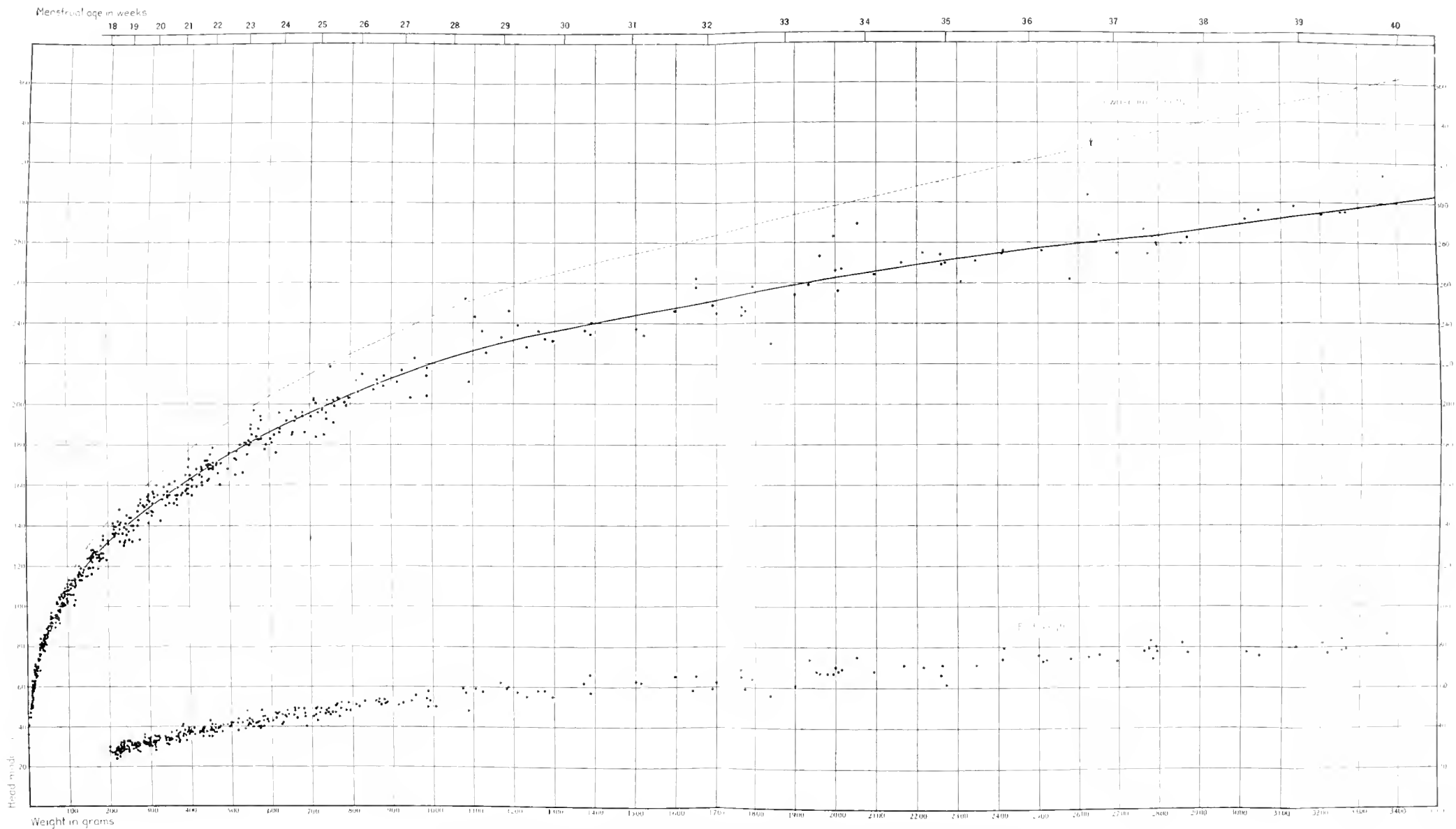


Curve of growth for fetuses of the Carnegie Collection over 200 grams in weight, plotted for sitting height and weight.





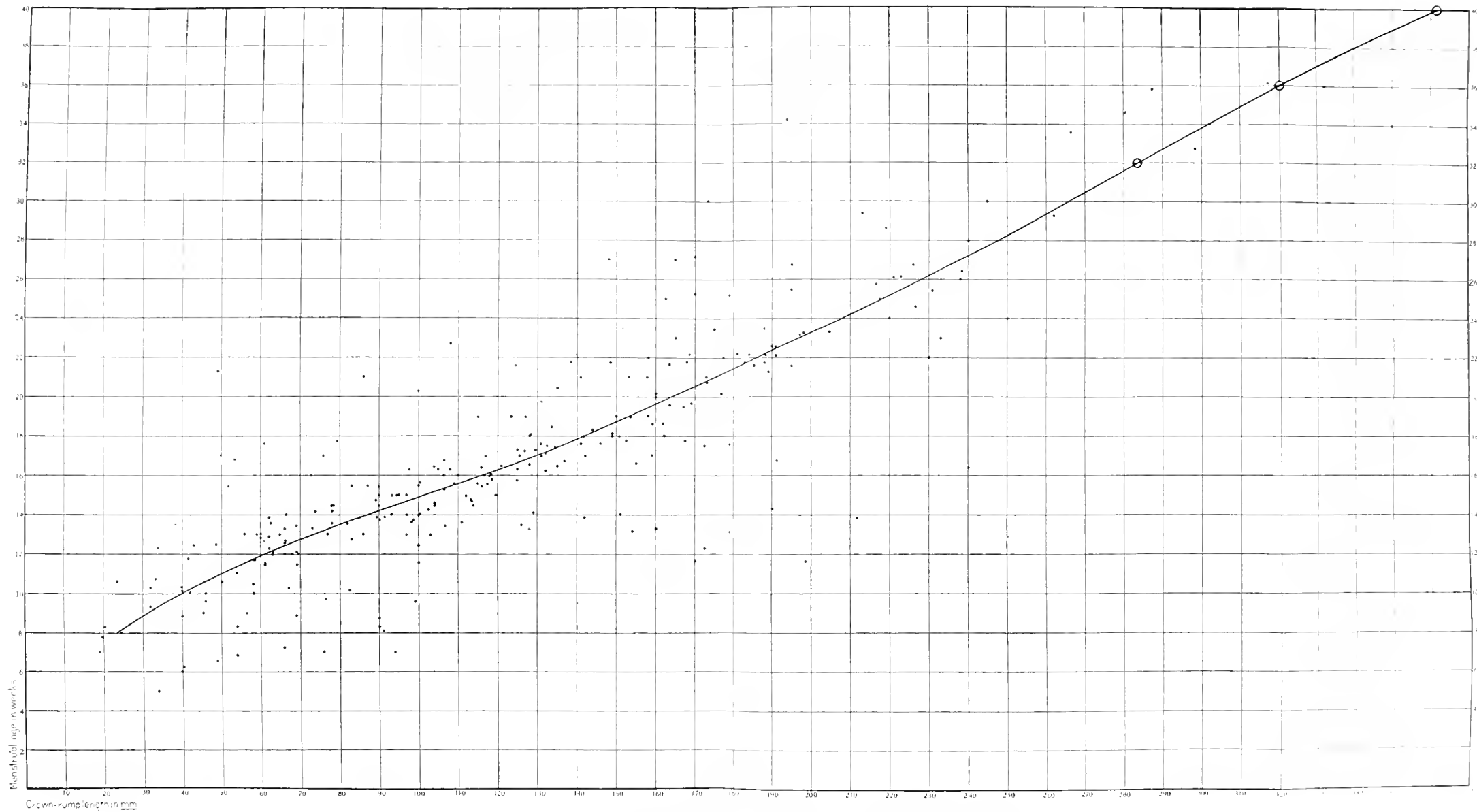
CHART 5.



Foot length and head modulus correlated to sitting height and weight for fetuses of the whole prenatal period. The heavy line represents the curve of the mean head modulus; the broken line is the mean sitting height or crown-rump length taken from chart 4.



CHART 6.



Field and curve of mean menstrual age for specimens in the Carnegie Collection having menstrual histories. The circles placed at the 32d, 36th, and 40th weeks are taken from Zangemeister's (1911) data and are used to complete the curve to the termination of pregnancy.



# CONTRIBUTIONS TO EMBRYOLOGY

---

VOLUME XI, Nos. 49 to 55



PUBLISHED BY THE CARNEGIE INSTITUTION OF WASHINGTON  
WASHINGTON, 1920













MBL WHOI LIBRARY



WH 1811 .

